REVISTA ERR01 ISSN: 2595-1378

CONGENITAL DENGUE AND NEONATAL NEUROLOGICAL MANIFESTATIONS: A SCOPING REVIEW

DENGUE CONGÊNITA E MANIFESTAÇÕES NEUROLÓGICAS NEONATAIS: UMA REVISÃO DE ESCOPO

DENGUE CONGÉNITO Y MANIFESTACIONES NEUROLÓGICAS NEONATALES: UNA REVISIÓN DEL ALCANCE

10.56238/ERR01v10n2-046

Ricardo Marafigo Zander[1], Ianka do Amaral Caetano[2], Aline Domingues Stumpf Mendoza[3], Laiza Moura Cunha Costa Luz[4], Jessyca Twany Demogalski[5], Cristina Berger Fadel[6], Leonardo Welling[7], Fabiana Bucholdz Teixeira Alves[8]

ABSTRACT

Rationale: Despite the rising number of dengue cases in pregnant women and the possibility of vertical transmission with neonatal neurological repercussions, the effects of congenital DENV infection remain poorly understood and scarcely documented in the scientific literature.

Objective: To map the neurological manifestations resulting from congenital dengue virus infection in neonates and to identify and explore scientific gaps related to improving maternal and child healthcare in the context of this condition.

Methods: This scoping review was conducted based on a search strategy guided by the research question: “What are the neonatal neurological manifestations resulting from congenital dengue?”, with clear definition of the study population, concept, and context. The databases Embase, LILACS, PubMed, Scopus, Web of Science, and gray literature sources were searched up to June 2024.

Results: A total of 178 articles were identified. After applying methodological filters and inclusion criteria, five studies were selected. Bibliographic data, aspects related to congenital dengue, and study conclusions were presented.

[1] Doctor Candidate in Health Sciences. Universidade Estadual de Ponta Grossa (UEPG).
E-mail: 240310501014@uepg.br
[2] Doctor Candidate in Health Sciences. Universidade Estadual de Ponta Grossa (UEPG).
E-mail: iankadoamaral@gmail.comz
[3] Master’s Student in Health Sciences. Universidade Estadual de Ponta Grossa (UEPG).
E-mail: alinedom93@gmail.com
[4] Master in Health Sciences. Universidade Estadual de Ponta Grossa (UEPG).
E-mail: laizamc1908@gmail.com
[5] Specialist in Neonatology. Secretaria de Estado da Saúde do Paraná (SESA-PR).
E-mail: jessycademogalski91@gmail.com
[6] Dr. in Preventive and Social Dentistry. Universidade Estadual de Ponta Grossa (UEPG).
E-mail: cbfadel@gmail.com
[7] Dr. in Medical Sciences. Universidade Estadual de Ponta Grossa (UEPG).
E-mail: leonardowelling@yahoo.com.br
[8] Dr. in Dental Sciences, Pediatric Dentistry. Universidade Estadual de Ponta Grossa (UEPG).
E-mail: fbtalves@uepg.br

Conclusion: The scoping review identified evidence of neonatal neurological manifestations associated with congenital DENV infection, highlighting its impact on fetal health and the need for clinical and neurological surveillance of exposed neonates.

Keywords: Dengue. Vertical Transmission of Infectious Disease. Neurologic Manifestations. Neonate.

RESUMO

Justificativa: Apesar do aumento de casos de dengue em gestantes e da possibilidade de transmissão vertical com repercussões neurológicas neonatais, os efeitos da infecção congênita pelo DENV permanecem pouco compreendidos e escassamente documentados na literatura científica.

Objetivo: Mapear as manifestações neurológicas decorrentes da infecção congênita pelo vírus da dengue em neonatos e identificar e explorar lacunas científicas relacionadas à melhoria da atenção materno-infantil diante dessa patologia.

Métodos: A revisão de escopo foi realizada com base em uma estratégia de busca fundamentada na pergunta norteadora “Quais são as manifestações neurológicas neonatais decorrentes da dengue congênita?”, com a definição da população, conceito e contexto do estudo. As bases de dados Embase, LILACS, PubMed, Scopus, Web of Science e literatura cinzenta foram consultadas até junho de 2024.

Resultados: Foram identificados 178 artigos. Após a aplicação dos filtros metodológicos e dos critérios de inclusão, cinco estudos foram selecionados. Foram apresentados dados bibliográficos, aspectos relacionados à dengue congênita e as conclusões dos estudos.

Conclusão: A revisão de escopo identificou evidências de manifestações neurológicas neonatais associadas à infecção congênita pelo DENV, destacando seu impacto na saúde fetal e a necessidade de vigilância clínica e neurológica em neonatos expostos.

Palavras-chave: Dengue. Transmissão Vertical de Doenças Infecciosas. Manifestações Neurológicas. Neonato.

RESUMEN

Justificación: A pesar del aumento de casos de dengue en embarazadas y la posibilidad de transmisión vertical con repercusiones neurológicas neonatales, los efectos de la infección congénita por el virus del dengue (DENV) siguen siendo poco conocidos y escasamente documentados en la literatura científica.

Objetivo: Mapear las manifestaciones neurológicas derivadas de la infección congénita por el virus del dengue en recién nacidos e identificar y explorar las lagunas científicas relacionadas con la mejora de la atención maternoinfantil para esta afección.

Métodos: La revisión exploratoria se realizó mediante una estrategia de búsqueda basada en la pregunta guía "¿Cuáles son las manifestaciones neurológicas neonatales derivadas del dengue congénito?", definiendo la población de estudio, el concepto y el contexto. Se realizaron búsquedas en las bases de datos Embase, LILACS, PubMed, Scopus, Web of Science y literatura gris hasta junio de 2024.

ISSN: 2595-1378

Resultados: Se identificaron 178 artículos. Tras aplicar los filtros metodológicos y los criterios de inclusión, se seleccionaron cinco estudios. Se presentaron datos bibliográficos, aspectos relacionados con el dengue congénito y las conclusiones del estudio.

Conclusión: La revisión exploratoria identificó evidencia de manifestaciones neurológicas neonatales asociadas con la infección congénita por DENV, destacando su impacto en la salud fetal y la necesidad de vigilancia clínica y neurológica en los neonatos expuestos.

Palabras clave: Dengue. Transmisión Vertical de Enfermedades Infecciosas. Manifestaciones Neurológicas. Neonato.

ISSN: 2595-1378

1 INTRODUCTION

Dengue is an infectious disease caused by the dengue virus (DENV), which belongs to the Flaviviridae family and is divided into four serotypes: DENV 1, DENV 2, DENV 3 and DENV 4. Transmission of the virus occurs mainly through female Aedes aegypti and Aedes albopictus mosquitoes, which inhabit tropical and subtropical regions (Rathore et al., 2022; Singh et al., 2023) . This endemic disease often triggers epidemic outbreaks of varying intensity and frequency, influenced by climatic factors, disorderly urbanization, and deficiencies in basic sanitation (Brasil, 2023).

According to Situation Report No. 16 - Dengue Epidemiological Situation in the Region of the Americas, 6,769,140 suspected dengue cases were reported on the American continent in 2024, resulting in a cumulative incidence of 717 cases per 100,000 inhabitants. In Brazil, according to the Epidemiological Week No. 11 report from the Emergency Operations Center, published by the Ministry of Health, from the first to the sixteenth epidemiological week of 2024, 3,852,901 probable dengue cases were recorded, with an incidence coefficient of 1,897.4 cases/100,000 inhabitants (Brasil, 2024c). Furthermore, considering the same period and according to data extracted from the Department of Information and Informatics of the Unified Health System (DATASUS), there are currently 4,099,684 probable cases of dengue in pregnant women in Brazil, with 421,361 probable cases in the state of Paraná (Brasil, 2024b).

The clinical repercussions of dengue in pregnant women include fever above 38 degrees, skin spots between the fourth and seventh day after infection, intense muscle, and joint pain of mild intensity, as well as intense headache, pruritus, and glandular hypertrophy, moderate hemorrhagic dyscrasia and rare neurological involvement (Brasil, 2024a). The gestational and perinatal prognosis of dengue fever shows a direct relationship between the gestational age at which the disease occurs and its intensity and the presence of complications in women (Anuradha; Sandya; George, 2019), increasing the risk of adverse pregnancy outcomes (Maurice; Ervin; Chu, 2021), such as miscarriage, premature birth, low birth weight and double the chances of the newborn having congenital neurological anomalies (Paixão et al., 2018).

However, despite the possibility of mother-to-fetus transmission of DENV ranging from 22.7% to 56.2%, depending on the gestational period of infection

(Basurko et al., 2017), and the occurrence of associated neonatal neurological repercussions (Maurice; Ervin; Chu, 2021), the effects of dengue infection during pregnancy on fetal neurological outcomes are not well understood and documented in the literature (Paixão et al., 2016; Brasil; Lupi, 2017; Maurice; Ervin; Chu, 2021; Usama; Assawawiroonhakarn; Soonsawad, 2024), which are often associated with other viruses transmitted by dengue vectors, such as Chikungunya virus and Zika virus (Brasil, 2024a). It is important to note that DENV transmission is more common when infection occurs close to childbirth (Arragain et al., 2017). Early identification and management are essential in these situations due to the associated high neonatal mortality rates (Ahuja; Gharde, 2023).

Brazil is currently facing significant challenges related to DENV infection, with an exponential increase in cases in pregnant women and the possibility of fetal involvement, a public health scenario that requires special care. This study aims to identify and explore research describing neonatal neurological manifestations resulting from congenital dengue infection. To this end, a mapping of scientific research will be carried out using the scoping review methodology, to provide a compilation of information that is easy to access and use, to improve maternal and childcare.

2 METHODS

2.1 TYPE OF STUDY

This is a scoping review. This type of review aims to map studies in the literature on a subject of interest, as well as to enable the identification of basic concepts, synthesizing evidence and possible gaps in the field of study, without determining the methodological quality of the studies analyzed (Arksey; O'Malley, 2005; Tricco et al., 2018; Peters et al., 2020; Pollock et al., 2021).

2.2 PROTOCOL

Adapting to the purposes of the study, the protocol for this review was carried out in six consecutive stages: (1) formulation and identification of the research question and objective; (2) identification of potentially relevant studies, which enable the breadth and scope of the review's purposes; (3) selection of eligible studies, according to the predefined criteria; (4) data extraction and

coding, carrying out the mapping; (5) compiling, summarizing and interpreting the results through a qualitative thematic analysis about the objective and question; (6) reporting the results, identifying the implications for practice or research (Arksey; O'Malley, 2005; Levac; Coulquhoun; O'Brien, 2010). The stage related to stakeholder consultation was excluded. The PRISMA ScR - Extension Fillable Checklist - Appendix 11.2 (JBI, 2021) was used to explain and present the scoping review. The protocol for this review is registered on the Open Science Framework (OSF) platform (Zander et al., 2024).

2.2.1 Formulating the research question

After deciding on the subject of the study, "What are the neonatal neurological manifestations resulting from congenital dengue?", the research question was defined and shaped by consensus among the authors to qualify the objective of the review. This was elaborated using the acronym PCC (Population-Concept-Context), plus the respective results of interest (Peters et al., 2020), as described in Figure 1. The central concept examined by the study, in order to guide the investigation's scope and breadth, includes the interventions, phenomena of interest, and/or outcomes, according to the JBI manual (Peters et al., 2020). The concept that applies to the research question is also described in Table 1.

Table 1

Research question and concept

Primary review question	**Population (P)**	**Concept (C)**	**Context (C)**	**Result of interest (O)**
"What are the neonatal neurological manifestations of congenital dengue?"	Neonates.	Dengue fever.	Neonatal neurological manifestations resulting from congenital dengue infection.	Mapping of studies describing neurological manifestations in neonates caused by congenital dengue infection.
Concept (C)	**Definition**			

ISSN: 2595-1378

Dengue fever	Dengue is a disease that belongs to the arboviruses, resulting from infection by viruses transmitted by arthropod vectors. In Brazil, the vector of this disease is the female Aedes aegypti mosquito. Scientifically, dengue viruses (DENV) are classified in the Flaviviridae family and in the Flavivirus genus. Among the different types of DENV, four serotypes with distinct genotypes and lineages are known to date: DENV-1, DENV-2, DENV-3 and DENV-4 (Brasil. 2023).

Source: The authors. Ponta Grossa – PR, Brasil, 2025.

2.2.2 identification of relevant studies, using the search strategy and data source

The researchers developed the search strategy after initial training in bibliographic screening without defined criteria. A standard strategy was then developed, using descriptors controlled by the Medical Subject Headings (MeSH) and Health Sciences Descriptors (DeCS), combined with keywords (free terms) and Boolean operators "AND" and "OR", in order to validate the terms of the PCC acronym of the question. Five multidisciplinary health science databases were consulted: Embase, Latin American and Caribbean Health Sciences Literature (LILACS), Public Medical Literature Analysis and Retrieval System Online (PubMed), Scopus and Web of Science.

The list of free and controlled terms and the standard search strategy used in the PubMed database are described below (Table 2). The standard search strategies used in the other databases were translated from the strategy in the table below and are described in detail in the protocol registered with the OSF.

Table 2

List of controlled and free terms used and advanced search strategy employed in PubMed

***Free terms**	
Perinatal Dengue, Congenital Dengue, Neurological Malformations, Neurological Disorders, Neurological Syndromes.	
Database	**Search strategy**

PubMed	("Infant Newborn"[All Fields] OR "Infants Newborn"[All Fields] OR "Newborn Infant"[All Fields] OR "Newborn Infants"[All Fields] OR "Newborns"[All Fields] OR "Newborn"[All Fields] OR "Neonate"[All Fields] OR "Neonates"[All Fields]) AND ("Dengue"[All Fields] OR "Dengue Fever"[All Fields] OR "Fever Dengue"[All Fields] OR "Classical Dengue"[All Fields] OR "Congenital Dengue"[All Fields] OR "Perinatal Dengue"[All Fields] OR "Severe Dengue"[All Fields] OR "Dengue Hemorrhagic Fever"[All Fields] OR "Hemorrhagic Dengue"[All Fields] OR "Hemorrhagic Fever Dengue"[All Fields] OR "Dengue Shock Syndrome"[All Fields] OR "Dengue Virus"[All Fields] OR "Dengue Viruses"[All Fields] OR "Virus Dengue"[All Fields] OR "Viruses Dengue"[All Fields] OR "Dengue Infection"[All Fields]) AND ("Neurological Manifestations"[All Fields] OR "Manifestation Neurologic"[All

Source: The authors. Ponta Grossa – PR, Brasil, 2025.

The gray literature was searched through Google Scholar, LIVIVO - The Search Portal for Life Sciences and ProQuest™ Dissertations & Theses Citation Index. The end date for all searches was June 2024.

2.2.3 selection of studies, following the inclusion and exclusion criteria

This review included scientific articles focused on neonatal neurological manifestations resulting from congenital dengue infection, according to the research question, without any language restrictions or time limits. The exclusion criteria adopted were: texts that addressed neurological manifestations resulting from other arboviruses transmitted by Aedes aegypti (Chikungunya virus and Zika virus), studies that were not carried out on newborns (up to 28 days old), that did not address the topic of interest, expert opinions, letters and animal studies.

The references cited in the selected articles were also checked if they were not retrieved in the standard database searches. All references were managed using the EndNote Online software and duplicate studies were removed. The study selection process was carried out using the Rayyan software in two stages. In stage 1, two reviewers (LRMZ and ADSM) independently assessed the titles and abstracts of all the references identified in the databases.

In stage 2, the same selection criteria were applied to the full articles to confirm their eligibility. The list of articles included for this stage was reviewed by an independent examiner (FBTA). The same two reviewers from the first stage (LRMZ and ADSM) then participated independently in the selection of studies. Disagreements in either of the two stages were resolved by discussion and mutual agreement between the two reviewers (LRMZ and ADSM) and in the

absence of agreement, a third reviewer (IAC) made a sovereign decision, when requested, on the eligibility of the studies. It is important to note that the final decision to include a study was always based on a complete reading of its text.

2.2.4 Data extraction and coding

The following information was recorded for each study included in the final data set: Bibliographic information and aspects of congenital dengue fever: Author(s) (year) and place of study (country), Type of study, Sample, Maternal characteristics, Dengue transmission and diagnosis parameters, Neonatal systemic and neurological manifestations, Conclusions.

2.2.5 Analysis and interpretation of results

A descriptive analysis of the data was carried out, followed by an interpretation focused on meeting the review's objectives. The relevant information was grouped into main nuclei contextualized in an analysis of the aspects of congenital dengue, with a focus on neonatal systemic and neurological manifestations, and are presented in the results section.

2.2.6 Reporting the results

In this last stage of the protocol, the results were presented as a flowchart, highlighting the search process and the inclusion/exclusion of publications. In addition, figures were drawn up containing the findings from the review, plus a descriptive summary of the mapped data, describing how the results are related to the research objective and question, in order to facilitate the synthesis and interpretation of the information presented. It should be noted that the methodological quality of the included studies was not assessed, as this scoping review aims not to provide a critical assessment of the evidence (Munn et al., 2018).

2.3 ETHICAL ASPECTS

As this study was based on publicly available bibliographic information, it did not require prior approval by an ethics committee for research involving human beings. In addition, the authors of this review have no links with funding institutions that could characterize potential conflicts of interest.

3 RESULTS

After applying the methodological filters, 178 articles were initially selected. Of these, duplicate articles were excluded (n = 99), giving 79 studies selected for reading the title and abstract. After excluding articles that did not answer the guiding question by reading the title and abstract (n = 65), 14 articles were selected for full reading. After reading the resulting articles in full, 12 studies were excluded because they were incompatible with the stipulated criteria. Subsequently, other studies that could be included in the review were searched for and retrieved by directly consulting the references (n = 3) and searching the gray literature (n = 1). At the end of the process, five (n=5) articles were included in the study (Figure 1).

Figure 1

Flowchart of the study selection process

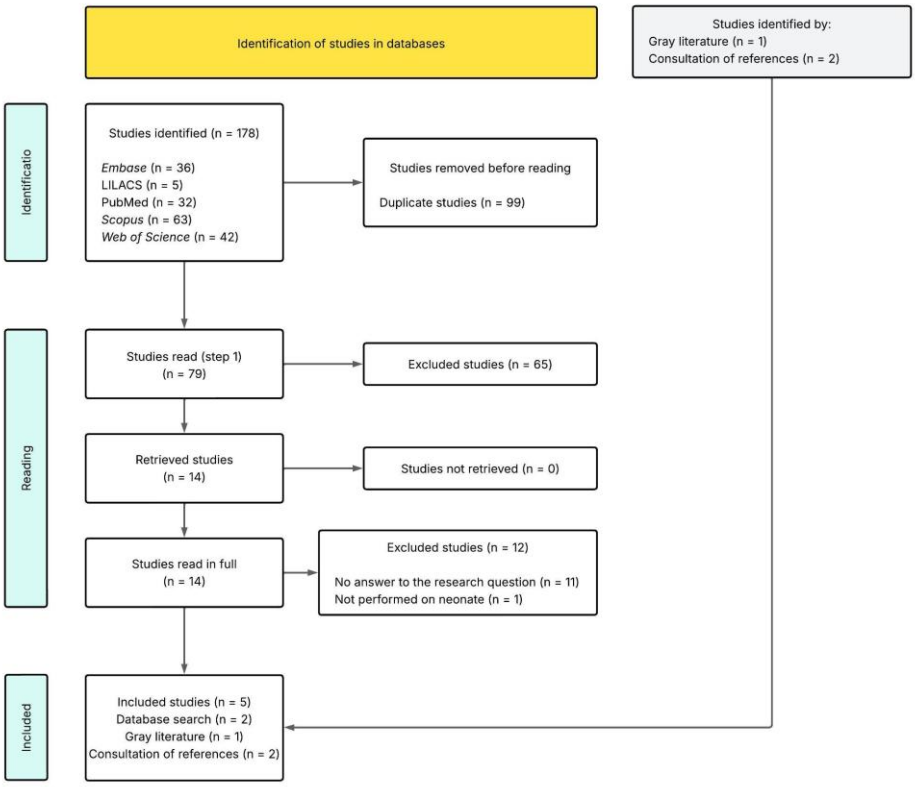

Source: The authors. Ponta Grossa – PR, Brasil, 2025.

The bibliographic information and aspects of congenital dengue fever included in the review are presented on the next page (Table 3).

ISSN: 2595-1378

Table 3

Bibliographic information, aspects of congenital dengue fever and conclusions of studies

Bibliographic information, aspects of congenital dengue fever and conclusions						
Author(s) (year) and place of study (country)	**Type of study**	**Sample**	**Maternal characteristics**	**Dengue transmission and diagnosis parameters**	**Neonatal systemic and neurological manifestations**	**Conclusions**
Sharma; Gulati (1992), India.	Prospective descriptive observational cross-sectional study.	4875 participants were investigated, with 87 confirmed cases of NTD and an incidence of 18.18/1000 births.	The average age of the mothers of neonates with NTDs was 24.6 years, of whom approximately 25.28% were primiparous and 68.96% multiparous. Of these patients, 51.72% had a good socio-economic situation and 48.28% lived in poor conditions. Approximately 96.55% were Hindu, had no history of vaginal bleeding in the first trimester of pregnancy and no abnormalities in laboratory tests (Hb, leukocyte	Of all the mothers of neonates with NTDs, 20.68% were diagnosed with dengue fever in the first trimester of pregnancy. In addition, 24.13% had a relative diagnosed with dengue during pregnancy and 24.13% had experienced an outbreak of the disease in their place of residence while pregnant. The remaining 31.06% did not have these characteristics to justify DENV infection	Approximately 25.28% (n=22) of the neonates had anencephaly, 13.79% (n=12) meningocele, 17.24% meningomyelocele (n=15), 9.19% (n=8) meningomyelocele associated with anencephaly, 34.48% (n=30) meningomyelocele associated with hydrocephalus. It was also possible to observe a frequency of 40.24% (n=35) of cases of spina bifida, with 92.54% (n=32) occurring in the sacral region.	Cases of NTDs appear to result from maternal infection with the dengue virus.

ISSN: 2595-1378

			count, uroculture, blood urea, glycemia and peripheral blood smear). However, there were 2 cases of positive Wassermann 's test for syphilis, one case of positive IgM for toxoplasma, two cases of rubella and a 5.74% family history of NTDs.	during pregnancy.		
Chye et al. (1997), Malaysia .	Case report.	4 participants (2 puerperal women and neonates) were infected with the dengue virus.	**Case 1:** A 36-week pregnant woman, 25 years old, G2P0, with no history of comorbiditie s, MUC or allergies was admitted to hospital for control of pregnancy-induced hypertensio n proteinuria (BP: 160/100 mmHg). Two days after admission, she had a fever of 39.4ºC, with no obvious infectious focus,	The mother's clinical manifestatio ns of dengue began five days before giving birth and the pathology was confirmed on the second day of the puerperium by	**Birth:** prematurity (36 weeks), APGAR 6/10 and 7/10 (no need for resuscitation), low birth weight (2.2 kg), anemia (Hb: 7.1 g/L; hematocrit: 20%), pallor, moaning,	Vertical transmissio n of DENV can lead to severe illness in the newborn, similar to that seen in children and adult patients. Early awareness, diagnosis and manageme nt of this

ISSN: 2595-1378

			with gradual regression over the following 72 hours, after taking paracetamol. On the fifth day, he presented with generalized edema, hepatomegaly, mild and transient gingival bleeding, as well as hematomas at venipuncture sites, progressing to persistent thrombocytopenia and coagulopathy, requiring platelet transfusion and fresh frozen plasma. She progressed to suspected severe pre-eclampsia, with increased levels of liver enzymes, persistent hypertension, worsening proteinuria, generalized edema, ascites and oligohydramnios. The care team decided to induce labor employing artificial placental rupture and oxytocin infusion. The woman was discharged after 18 days. **Case 2**: Was not reported as it did not answer the research question.	detecting specific IgM for DENV. In the newborn, the diagnosis was confirmed by isolating DENV-2 in a blood sample taken on the second day of life, confirmed by RT-PCR analysis.	respiratory distress, drop in saturation, suspected sepsis. **24-36h. postpartum:** generalized and transient skin rash, low-grade fever (>38ºC), irritability, opisthotonus and mild, non-specific and generalized changes on chest X-ray. Presence of hemorrhagic cerebrospinal fluid on lumbar puncture, hematological alterations and coagulopathy. **60h. postpartum:** worsening respiratory condition, drop in O2 saturation, irregular, generalized and bilateral perihilar opacities on chest X-ray, suspicion of meningitis, hematological alterations and coagulopathy.	potentially lethal condition are necessary to reduce perinatal morbidity and mortality, especially in endemic communities.

ISSN: 2595-1378

					90-114h. postpartum: massive left intracerebral hemorrhage observed on cranial ultrasound, with midline deviation,	

					causing obliteration of the left lateral ventricle and dilation of the right lateral ventricle, convulsions, severe acute renal failure, hypotension, hypoglycemia, abnormal liver function, coagulopathy and death.	
Paixão et al. (2018), Brazil.	Retrospective observational cohort study.	16,103,312 births were included from 2006 to 2012 (before the introduction of the Zika virus), of which 13,634 (0.08%) had congenital anomalies.	Not reported.	The authors probabilistically linked records of mothers of live births with notification records for dengue to identify women who were notified of dengue during pregnancy. Gestational dengue was counted when DENV infection was reported during pregnancy and resulted in a live birth. Notification of congenital malformation was considered when ICD-10 Q00-Q07 "congenital malformations of the nervous	Dengue occurring during pregnancy increases the chances of neonatal congenital neurological anomalies (OR 1.5), anencephaly (OR 1.9), encephalocele (1.4), microcephaly (OR 1.7), congenital hydrocephalus (1.6), congenital malformations of the brain (OR 4.5), spina bifida (OR 0.8) and other congenital malformations of the spinal cord (OR 5.4). However, although the	The results of the study showed an association between dengue during pregnancy and congenital brain anomalies, suggesting that flaviviruses other than the Zika virus are associated with such malformations.

ISSN: 2595-1378

				system" was present. Symptoms of DENV infection occurred at the first	study showed an association between DENV infection during pregnancy and congenital brain anomalies, it was impossible to obtain sufficient statistical power to isolate the	
				gestational trimester in 50.00% of the patients notified.	effect of dengue on this outcome reliably.	

ISSN: 2595-1378

Alallah et al. (2020), Saudi Arabia.	Case report.	1 newborn participant.	A 33-year-old woman, G3P2, mother of two healthy children, was admitted to the emergency department at 13 weeks and two days gestation, presenting with fever, headache, body pain and nausea. In addition, she had no history or presence of petechiae at the time of the consultation and her blood smear showed a mild thrombus. Her clinical condition evolved positively with conservative treatment. The patient went into labor at 37 weeks and three days, giving birth to a vigorous baby girl with a good APGAR score.	The puerperal woman tested positive for DENV in the thirteenth week of pregnancy, both for the non-specific antigen and for dengue IgM. In the newborn, dengue serology was positive (IgM and IgG).	**Prenatal care:** the initial ultrasound at 22 weeks was normal, but a follow-up examination at 29 weeks and three days revealed microcephaly, with BPD and CP below 1% for gestational age, as well as a lemon-shaped skull and a cerebral cyst in the midline and to the right, posterior to the lateral ventricle. MRI of the fetus at 29 weeks and 6 days showed extensive loss of volume in the brain parenchyma, loss of the normal architecture of its hemispheres, which had been replaced by large cysts, and the formation of subcortical cysts. There was also marked ventricular dilatation, characterized by large extra axial spaces on the MRI. **Postpartum:** low weight (2.47 kg, 10th	Although the association between symptomatic dengue during pregnancy and congenital brain anomalies in the baby is not as frequent as that observed with the Zika virus, dengue infection suggests that other flaviviruses can also cause congenital malformations. In such cases, it is essential to maintain a high index of suspicion, make an early diagnosis and ensure close monitoring.

ISSN: 2595-1378

					percentile), length of 47 cm (50th percentile) and head circumference	

ISSN: 2595-1378

					of 27 cm (< 3rd percentile for age), absence of dysmorphic features, negative RT-PCR for Zika virus and normal abdominal ultrasound. Skeletal research revealed apparent microcephaly, with a vertebral fusion segmentation anomaly in the lumbar region, and brain MRI showed a significant reduction in brain volume (cortical thinning and loss of normal architecture), as well as small dystrophic calcifications at the junction of the cortical and subcortical areas of the frontal lobes and periventricular regions. Ventriculomegaly was also identified, with widening of the subarachnoid spaces and diffuse cerebellar hypoplasia. **Post-hospitalization:** the baby was discharged home in a stable state in the second week of life, under regular breastfeeding and medicated with	

					cholecalciferol drops. In his outpatient follow-up at one month of age, he thrived well, but showed microcephaly (head circumference of 29 cm), mild hypertonia in the limbs and self-limiting episodes of abnormal on and off movements.	
Singh et al. (2023), India.	Literature review.	Not applicable.	Not reported.	Vertical transmission of DENV should be considered when pregnant women acquire the infection in early pregnancy or at least 10 to 15 days before giving birth. DENV is transmitted to the fetus during maternal viremia, even if infected mothers remain asymptomatic. In addition, breastfeeding is also considered a mode of vertical transmission of DENV during the postnatal	**Prenatal:** congenital dengue occurs when there is insufficient timeansplacental induction/passage of protective antibodies after maternal infection. Infections in early pregnancy can result in spontaneous abortions or neural tube defects, but most cases do not present congenital anomalies. **Post-natal:** neonates with fever, maculopapular rash and thrombocytopenia in endemic regions should be suspected of DENV infection. When congenital DENV infection occurs, the resulting	DENV infections during pregnancy can increase the risk of neurological anomalies and congenital brain malformations in neonates. The outcomes of postnatal infections seem more promising, but more studies are still needed for a more complete understanding.

				period. In addition, DENV 2 has been the predominant serotype associated with this form of transmission due to its high circulation and ability to cross or break through the placental barrier.	neurological manifestations can manifest as: **(A)** direct infection of	

				The diagnosis of congenital DENV infections is based on a history of maternal fever and dengue non-structural antigen 1 (NS1) or specific antibodies to this virus.	neurological tissues (encephalitis, meningitis, myositis, myelitis, rhabdomyolysis); **(B)** systemic or metabolic imbalance (encephalopathy, stroke); and **(C)** early or late post-infection sequelae (transverse myelitis, acute disseminated encephalomyelitis). Babies with early intrauterine infection show microcephaly, anencephaly and hydrocephalus. Most babies with late-onset infections develop uneventful	

					recovery encephalopathy.	

Source: The authors. Ponta Grossa – PR, Brasil, 2025.

4 DISCUSSION

Most of the studies analyzed were conducted on the Asian continent (Sharma; Gulati, 1992; Chye et al., 1997; Alallah et al., 2020; Singh et al., 2023), with only one study carried out in the southern region of the American continent (Paixão et al., 2018). These findings corroborate information provided by the World Health Organization (WHO), which indicates that the regions most affected by DENV include Southeast Asia, the Americas, and the Western Pacific, with Asia accounting for more than 70% of global cases (WHO, 2022). This predominance is attributed to tropical conditions that favor the proliferation of the mosquito vector, consequently resulting in high endemic rates in these áreas (WHO, 2012).

The maternal characteristics observed, such as age and number of pregnancies, were not found to be decisive factors for the occurrence of neurological anomalies, nor were socioeconomic conditions in isolation (Sharma; Gulati, 1992; Chye et al., 1997). However, a systematic review of 95 studies demonstrated that low socioeconomic status, areas with high population movement, and high population density are associated with greater arbovirus spread (Santos et al., 2023), which conflicts with the findings gathered in the present study.

One of the critical issues identified in this review is the low clinical visibility of DENV infection in pregnant women, with mild and nonspecific maternal symptoms such as headache, body pain, fever, and náusea (Alallah et al., 2020), in addition to uncertainty regarding direct viral exposure (Sharma; Gulati, 1992), making diagnosis particularly challenging. This is especially relevant in endemic regions where multiple arboviruses with

overlapping clinical presentations circulate simultaneously (Fortuna; Marsili; Venturi, 2024). Since DENV infection can range from asymptomatic cases to severe forms, with associated neurological, lymphatic, ophthalmologic, and cardiovascular complications (Parveen et al., 2023), and in some cases require intensive care (Mulik; Dad; Buhmaid, 2023), it is essential to strengthen prenatal surveillance through protocols that include epidemiological and serological screening, even in asymptomatic pregnant women, in order to anticipate fetal risks and enable timely, targeted interventions.

This review also highlights that DENV infection during pregnancy, particularly in the first trimester, may be associated with severe neonatal outcomes, especially neural tube defects such as anencephaly, meningocele, meningomyelocele, hydrocephalus, and spina bífida (Sharma; Gulati, 1992; Paixão et al., 2018; Singh et al., 2023). Although neonatal neurological manifestations are most commonly linked to Zika virus, as demonstrated by a meta-analysis reporting increased risk of congenital brain defects (OR: 1.94), including microcephaly (OR: 2.7), ventriculomegaly (OR: 1.7), and corpus callosum anomalies (OR: 1.8) in children born to mothers infected with Zika virus (Ba et al., 2025), the findings in this review suggest that DENV may also pose a significant threat to fetal health and should be considered a potential teratogenic agent, particularly in regions with high endemicity.

Finally, the neonatal complications described in the analyzed studies highlight the neurotropic potential and severity of vertical DENV transmission (Singh et al., 2023). Among the critical outcomes reported were low birth weight, anemia, respiratory complications, intracranial hemorrhage, and motor abnormalities such as hypertonia and abnormal limb movements, suggesting possible functional neurological impairment in the neonate. In more severe cases, neonatal death occurred, along with systemic complications including encephalopathy, seizures, hematological alterations, and clinical signs consistent with meningitis (Chye et al., 1997). These conditions may increase the cost of neonatal care, as they often require intensive monitoring, specialized therapeutic resources, and prolonged multidisciplinary support, similar to the care of micro-preterm infants with neurological complications (WHO, 2012), representing a challenge for health services and reinforcing the need for early screening and intervention in neonates exposed to DENV in utero.

5 STUDY LIMITATIONS

A primary limitation of this study stems from the inherent characteristics of a scoping review, which does not include a critical appraisal of the methodological quality of the included studies. This limitation restricts the ability to establish definitive causal inferences. Moreover, a notable scarcity of research specifically addressing congenital dengue constrained both the

scope and depth of the analysis. Heterogeneity in study designs, absence of control groups, and variability in diagnostic criteria posed challenges to result comparison and hindered the formulation of generalizable conclusions. The geographic concentration of studies in specific regions introduced potential bias and limited the representation of the global context of the disease. This paucity of evidence highlights a critical gap in scientific knowledge and underscores the need for further research focused on understanding the impact of dengue on fetal and neonatal health, as well as the development of targeted clinical care protocols.

6 CONTRIBUTIONS TO PRACTICE

The findings of this scoping review offer valuable contributions to the work of healthcare professionals involved in maternal and child care. The identification of congenital neurological manifestations associated with DENV infection during pregnancy highlights the need for enhanced clinical surveillance in pregnant women exposed or potentially exposed to the virus, particularly in endemic regions, with emphasis on monitoring during the first trimester. Furthermore, the importance of early diagnostic investigation and neurological follow-up of neonates exposed in utero is underscored, even in the absence of evident clinical signs at birth.

7 CONCLUSION

By applying the scoping review methodology, it was possible to identify and compile evidence on neonatal neurological manifestations resulting from congenital DENV infection. Additionally, the mapping of the available scientific literature yielded an accessible and informative synthesis with the potential to improve prenatal and neonatal care, strengthen maternal and child health interventions, support early clinical recognition, and inform the development of targeted care strategies to mitigate the impacts of this condition.

REFERENCES

Alallah, J., Albrah, A., & Alkhaldi, S. (2020). Congenital dengue in a Saudi neonate: A case report. Journal of Neonatal-Perinatal Medicine, 13(2), 279–282. https://doi.org/10.3233/NPM-190346

Anuradha, G., Sandya, M. R., & George, S. (2019). Spectrum of dengue morbidity in pregnancy and its impact on maternal and perinatal outcome. International Journal of Reproduction, Contraception, Obstetrics and Gynecology, 8(4), 1511–1517. https://doi.org/10.18203/2320-1770.ijrcog20191209

Arksey, H., & O'Malley, L. (2005). Scoping studies: Towards a methodological framework. International Journal of Social Research Methodology, 8(1), 19–32. https://doi.org/10.1080/1364557032000119616

Arragain, L., Dupont-Rouzeyrol, M., Folcher, N., Baudouin, L., Calvez, E., & Biron, A. (2017). Vertical transmission of dengue virus in the peripartum period and viral kinetics in newborns and breast milk: New data. Journal of the Pediatric Infectious Diseases Society, 6(4), 324–331. https://doi.org/10.1093/jpids/piw069

Ahuja, S., & Gharde, P. M. (2023). A narrative review of maternal and perinatal outcomes of dengue in pregnancy. Cureus, 15(11), e49429. https://doi.org/10.7759/cureus.49429

Ba, F., Diallo, A. K., Dia, I., & Diallo, M. (2025). Zika virus-related birth defects and neurological complications: A systematic review and meta-analysis. Reviews in Medical Virology, 35(2), e2596. https://doi.org/10.1002/rmv.2596

Basurko, C., Carles, G., Youssef, M., & Guindi, W. E. (2018). Estimating the risk of vertical transmission of dengue: A prospective study. The American Journal of Tropical Medicine and Hygiene, 98(6), 1826–1832. https://doi.org/10.4269/ajtmh.17-0798

Brasil, Ministério da Saúde, & Federação Brasileira das Associações de Ginecologia e Obstetrícia. (2024a). Manual para prevenção, diagnóstico e tratamento da dengue na gestação e no puerpério. São Paulo, Brazil: FEBRASGO; Brasília, Brazil: Ministério da Saúde.

Brasil, Ministério da Saúde. (2024b). Banco de dados do Sistema Único de Saúde – DATASUS. Brasília, Brazil: Ministério da Saúde.

Brasil, Ministério da Saúde, Centro de Operações de Emergências. (2024c). Número de casos prováveis de dengue por semana epidemiológica, Brasil, 2023 e 2024 (Informe Semanal, Edição nº 11, SE 01 a 16/2024). Brasília, Brazil: Ministério da Saúde.

Brasil, Ministério da Saúde. (2023). Saúde de A a Z: Dengue. Brasília, Brazil: Ministério da Saúde.

Brasil, P., & Lupi, O. (2017). Dengue infection during pregnancy and risk of preterm birth. The Lancet Infectious Diseases, 17(9), 885–886. https://doi.org/10.1016/S1473-3099(17)30406-7

Chye, J. K., Lim, C. T., Ng, K. B., Lim, J. M., George, R., & Lam, S. K. (1997). Vertical transmission of dengue. Clinical Infectious Diseases, 25(6), 1374–1377. https://doi.org/10.1086/516126

Fortuna, C., Marsili, G., & Venturi, G. (2024). Special issue “Arbovirus Diagnostics”. Viruses, 16(8), 1182. https://doi.org/10.3390/v16081182

Joanna Briggs Institute. (2021). Manual for evidence synthesis: Appendix 11.2 – PRISMA ScR extension fillable checklist. Adelaide, Australia: JBI Global Wiki.

Levac, D., Colquhoun, H., & O’Brien, K. K. (2010). Scoping studies: Advancing the methodology. Implementation Science, 5(1), 69. https://doi.org/10.1186/1748-5908-5-69

Maurice, A. S., Ervin, E., & Chu, A. (2021). Ebola, dengue, chikungunya, and Zika infections in neonates and infants. Clinics in Perinatology, 48(2), 311–329. https://doi.org/10.1016/j.clp.2021.03.006

Mulik, V., Dad, N., & Buhmaid, S. (2021). Dengue in pregnancy: Review article. European Journal of Obstetrics & Gynecology and Reproductive Biology, 261, 205–210. https://doi.org/10.1016/j.ejogrb.2021.04.036

Munn, Z., Peters, M. D. J., Stern, C., Tufanaru, C., McArthur, A., & Aromataris, E. (2018). Systematic review or scoping review? Guidance for authors when choosing between a systematic or scoping review approach. BMC Medical Research Methodology, 18(1), 143. https://doi.org/10.1186/s12874-018-0611-x

Paixão, E. S., Teixeira, M. G., Costa, M. D. C. N., & Rodrigues, L. C. (2018). Symptomatic dengue during pregnancy and congenital neurologic malformations. Emerging Infectious Diseases, 24(9), 1748–1750. https://doi.org/10.3201/eid2409.170361

Paixão, E. S., Barreto, F., Teixeira, M. D. G., Costa, M. D. C. N., & Rodrigues, L. C. (2016). Dengue during pregnancy and adverse fetal outcomes: A systematic review and meta-analysis. The Lancet Infectious Diseases, 16(7), 857–865. https://doi.org/10.1016/S1473-3099(16)00088-8

Parveen, S., Riaz, Z., Saeed, M., Javed, M., Khan, M. A., & Khan, A. H. (2023). Dengue hemorrhagic fever: A growing global menace. Journal of Water and Health, 21(11), 1632–1650. https://doi.org/10.2166/wh.2023.164

Peters, M. D. J., Godfrey, C., McInerney, P., Munn, Z., Tricco, A. C., & Khalil, H. (2020). Updated methodological guidance for the conduct of scoping reviews. JBI Evidence Synthesis, 18(10), 2119–2126. https://doi.org/10.11124/JBIES-20-00167

Pollock, D., Tricco, A. C., & Khalil, H. (2021). Undertaking a scoping review: A practical guide for nursing and midwifery students, clinicians, researchers, and academics. Journal of Advanced Nursing, 77(4), 2102–2113. https://doi.org/10.1111/jan.14743

Rathore, S. S., Oberoi, S., Hilliard, J., & Rathore, S. S. (2022). Maternal and foetal-neonatal outcomes of dengue virus infection during pregnancy. Tropical Medicine & International Health, 27(7), 619–629. https://doi.org/10.1111/tmi.13776

Santos, L. L. M., de Aquino, E. C., Sabino, E. C., & Duarte, A. J. S. (2023). Dengue, chikungunya, and Zika virus infections in Latin America and the Caribbean: A systematic review. Revista Panamericana de Salud Pública, 47, e103. https://doi.org/10.26633/RPSP.2023.103

Sharma, J. B., & Gulati, N. (1992). Potential relationship between dengue fever and neural tube defects in a northern district of India. International Journal of Gynecology & Obstetrics, 39(4), 291–295. https://doi.org/10.1016/0020-7292(92)90257-8

Singh, S., Kumar, A., & Bhatt, N. (2023). Neurological manifestations of perinatal dengue. Newborn, 2(2), 158–172. https://doi.org/10.5005/jp-journals-11002-0062

Tricco, A. C., Lillie, E., Zarin, W., O'Brien, K. K., Colquhoun, H., Levac, D., Moher, D., Peters, M. D. J., Horsley, T., Weeks, L., Hempel, S., Akl, E. A., Chang, C., McGowan, J., Stewart, L., Hartling, L., Aldcroft, A., Wilson, M. G., Garritty, C., … Straus, S. E. (2018). PRISMA extension for scoping reviews (PRISMA-ScR): Checklist and explanation. Annals of Internal Medicine, 169(7), 467–473. https://doi.org/10.7326/M18-0850

Usama, S., Assawawiroonhakarn, S., & Soonsawad, S. (2023). Vertical dengue transmission complicated with neonatal encephalitis. BMJ Case Reports, 16(12), e256589. https://doi.org/10.1136/bcr-2023-256589

World Health Organization. (2022). Dengue fever – Peru: Disease outbreak news. Geneva, Switzerland: World Health Organization.

World Health Organization. (2012). Global strategy for dengue prevention and control, 2012–2020. Geneva, Switzerland: World Health Organization.

Zander, L. R. M., de Aquino, E. C., Sabino, E. C., & Duarte, A. J. S. (2024). Neonatal congenital neurological sequelae resulting from maternal dengue: Scoping review protocol. Open Science Framework, 1–9. https://doi.org/10.17605/OSF.IO/3K7N4