

IMPACTO CIENTÍFICO
EDITORA

EQUINE LAMINITIS ASSOCIATED WITH GASTROINTESTINAL IMBALANCES AND SYSTEMIC INFLAMMATORY RESPONSE SYNDROME: A REVIEW OF THE CLINICAL IMPLICATIONS AND THERAPEUTIC OPTIONS

10.56238/edimpacto2025.007-002

Paulo Antônio Lourençoni Ferreira[1], Jaqueline Aparecida Sousa Pereira[2], Clara Alves Araujo Almeida[3], Fatima Christina França Alexandrowitsch[4], André Luiz de Souza Rezende[5], Lauren Souza Mendes[6], Yasmim Kelly Fernandes Ferreira[7], Rafael Angelo Duarte Costa[8], José Oswaldo de Souza Scarpa[9].

ABSTRACT

Laminitis consists of inflammation of the dermal lamellae of the hoof and digital vascular dysfunction that can result in deformation and/or loss of the hooves, and can be a serious pathology in horses. In most cases, these conditions are preceded by gastrointestinal imbalances. Any damage to the intestinal barrier can allow the systemic invasion of toxins derived from the intestine that can act as a "trigger" for the development of the disease. Laminitis related to sepsis is acute, and sepsis is characterized as a systemic inflammatory state with the presence of an infection. The study of laminitis induction models allows a better understanding of the mechanisms involved, although its pathophysiology has not been completely elucidated. Clinical signs may be more evident in the thoracic limbs, causing the patient to try to transfer the support of their weight to the pelvic limbs. Treatment, on the other hand, consists of a multifactorial approach, depending on the cause and clinical signs. In this sense, this study aimed to perform a literature review to better evidence the relationship between the occurrence of laminitis and gastrointestinal disorders

[1] Bachelor of Veterinary Medicine from the University Center of Southern Minas (UNIS)
E-mail: pauloferreira.boi@yahoo.com
[2] Master's student in Animal Health and Collective Health at the Federal University of Lavras (UFLA)
Email: jaqueline.pereira2@estudante.ufla.br
[3] Undergraduate student in Veterinary Medicine at the Federal University of Lavras (UFLA)
E-mail: clara.almeida@estudante.ufla.br
[4] Undergraduate student in Veterinary Medicine at the Federal University of Lavras (UFLA)
E-mail: fatima.alexandrowitsch@estudante.ufla.br
[5] Graduating in Veterinary Medicine at the University Center of Belo Horizonte
Email: luisrezende70@gmail.com
[6] Undergraduate student in Veterinary Medicine at the Federal University of Lavras (UFLA)
E-mail: lauren.mendes@estudante.ufla.br
[7] Graduating in Veterinary medicine by the Federal University of Lavras (UFLA)
E-mail: yasmimkelly151627@gmail.com
[8] Master in Veterinary Sciences from the Federal University of Lavras (UFLA).
E-mail: rafaelduartevet@gmail.com
[9] Professor of Veterinary Medicine at the University Center of Southern Minas (UNIS)
E-mail: jose.scarpa@gmail.com

that lead to systemic inflammatory response syndrome and sepsis. Addressing the possible pathophysiology of the condition, and possible treatments to be applied.

Keywords: Sepsis. Horses. Distal phalanx. Carbohydrate overload.

INTRODUCTION

In the equine species, the most common predisposing cause of laminitis comprises the systemic inflammatory response syndrome/sepsis with consequent multiple organ dysfunction. In most cases, these conditions are preceded by gastrointestinal imbalances. Any damage to the intestinal barrier, such as strangulation, colitis/enteritis or carbohydrate overload can allow the systemic invasion of toxins derived from the intestine that can act as a "trigger" for the development of the disease (Almeida; Queiroz; Biava, 2017).

In antiquity, the Greeks recorded evidence of the occurrence of laminitis, when the Greek philosopher, Aristotle, described horses with acute fever associated with hoof lesions, after ingestion of barley in the year 350 B.C. Apsyrtus, a veterinarian and Roman soldier who dedicated much of his life to the study and treatment of horses, in the year 330 B.C. stated that this pathology was multifactorial, determining it as "gout" and that light exercise, bloodletting, and dietary restrictions would be necessary (Van Eps; Burns, 2019). Even after so long since its first descriptions, laminitis is still characterized by a challenge for veterinarians. This is because it requires multimodal therapy and because it presents a complex pathophysiology and little elucidation (Dos Santos Mendes et al., 2021).

Due to the fact that the hoof is defined as a highly specialized integumentary portion, created to support the weight and dissipate reaction forces of the soil, this complexity exists. It is the suspensory apparatus of the distal phalanx of the hoof that connects it to the appendicular skeleton, and a structural and functional failure of this apparatus will lead to the development of laminitis (Pollitt, 2010). Thus, it consists of inflammation of the dermal lamellae of the hoof and digital vascular dysfunction that can result in deformation and/or loss of the hooves. In the United States, it is estimated that 75% of horses admitted to reference veterinary hospitals with laminitis end up being euthanized (Laskoski et al., 2016).

Clinical signs may be more evident in the thoracic limbs, causing the patient to try to transfer the support of his weight to the pelvic limbs (Van Eps; Burns, 2019). However, it can also affect all four limbs, and ponies are described as being more sensitive to the onset of this problem, and can be up to four times greater than in other equids. Thus, the animals will present pain, lameness with the appearance of "walking on eggshells" and reluctance to move. In addition to the increase in temperature in the hoof wall and coronary belt, increased pulsation of the digital artery and exacerbated sensitivity to hoof impingement, among other signs (Coelho et al., 2023).

The study of laminitis is commonly carried out through experimentally induced inflammatory models. Such as by administering carbohydrate overload, or by inducing

endocrinopathic laminitis, such as by administering insulin. However, the occurrence of morphological lesions in the hoof lamellae can also be induced by gastrointestinal disorders, as in natural colic syndrome (Almeida; Queiroz; Biava, 2017). Although the exact mechanism that triggers this condition remains unknown, there is growing evidence that a systemic inflammatory response, such as that observed in endotoxemia, with consequent inflammation of the hoof laminae are important points to trigger the disease (Van Eps; Burns, 2019).

In this sense, this study aimed to perform a literature review to better evidence the association between the occurrence of laminitis and gastrointestinal disorders that lead to systemic inflammatory response syndrome and sepsis. Addressing the possible pathophysiology of the condition, and possible treatments to be applied.

LITERATURE REVIEW

EQUINE HOOF ANATOMY AND STRUCTURE

Horses have their digital bones fused into a single finger, and in the distal portion there is the second and third phalanx, and also the distal (navicular) sesamoid bone. It is the third phalanx that is completely internal to the hull, being protected by it, as well as the navicular bone. (Figure 1) (Pollitt, 2010).

The equine hoof is a portion with high integumentary specialization, composed of hypodermis, dermis and epidermis, functioning as a kind of "natural shoe" that offers support and protection. Through its structure, weight bearing and also dissipation of soil reaction forces are conferred. In its composition, one can see the presence of several layers, each interconnected and with a well-defined function (Dyce, 2004).

Figure 1. Longitudinal section of the distal portion of the equine limb. The number 1 is represented by the first phalanx, the number 2 is the second phalanx and the number 3 corresponds to the third phalanx. The number 5 represents the deep digital flexor tendon, with its insertion into the third phalanx indicated by the number 6. The number 9 indicates the hoof wall, number 10 is the white line, and number 12 the ranilla.



Source: Luz et al (2021).

The Hoof is produced by germ cells that are basal epidermal cells, and which form keratinocytes. These cells mature, keratinize continuously, and are deposited in the proximal wall of the hoof. It is possible to divide the equine hoof into four main structures: sole, frog, wall or rampart, and periople (Leise; Fugler, 2021).

The wall is the most visible part, that is, the epidermis can still be divided into internal or lamellar layer, middle and external (Figure 2). This is the part that is worn out when it comes into contact with the ground. The internal or lamellar extract is made up of primary and secondary epidermal lamellae. The external is derived from the periople corium and the middle from the coronary border. Both grow in a distal direction (Luz et al., 2021).

Figure 2. Dorsal hoof wall of a normal adult horse seen from the inner surface. The subdivisions of the case into external, middle, and internal extracts are seen.

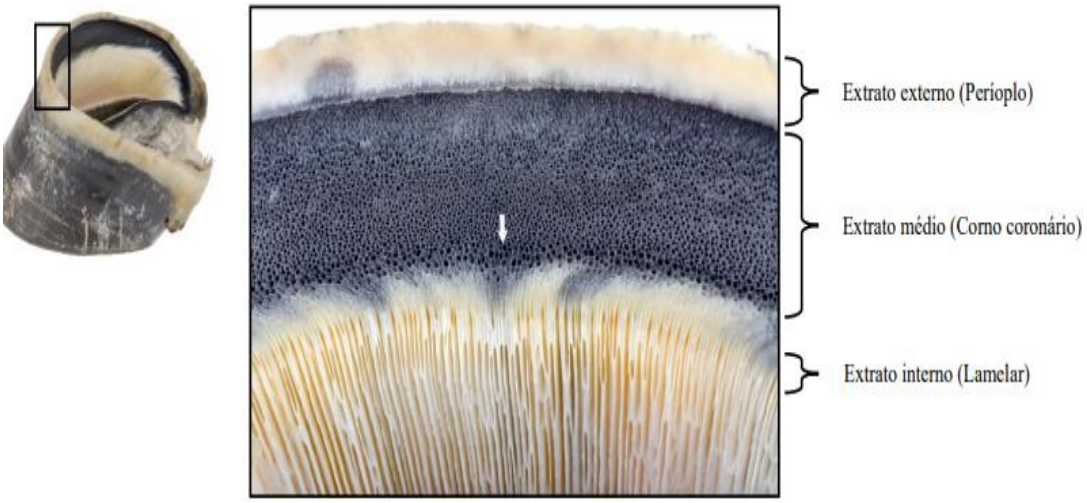

Source: Pollitt (2016).

The periople is also present in the outermost part, however, it is as a band near the crown extending to the bulbs of the frog beads. The sole of the hull joins the frog with the wall, being concave in shape (Marcato; Perillo, 2020).

The dermis, on the other hand, corresponds to the internal part and in it is found high vascularization and innervation, folding in the parietal dermis and forming primary and secondary dermal lamellae that are folds on the surface of the primary lamellae (Figure 3). There are approximately 550 to 600 primary dermal lamellae for each hull, and 150 to 200 secondary dermal lamellae for each primary lamella (Ehremann et al., 2021). They are in close contact with the third phalanx, fixing and suspending the distal phalanx. When vascular injuries occur in the laminar dermis, laminitis processes are caused, it is possible to result in necrosis in chronic cases and destabilization of the support of the third phalanx in relation to the wall, leading to the rotation of the third concave phalanx (Marcato; Perillo, 2020).

Figure 3. Equine hoof wall with dermal lamellae. SELs: secondary epidermal lamellae; PEL: primary epidermal lamellae.

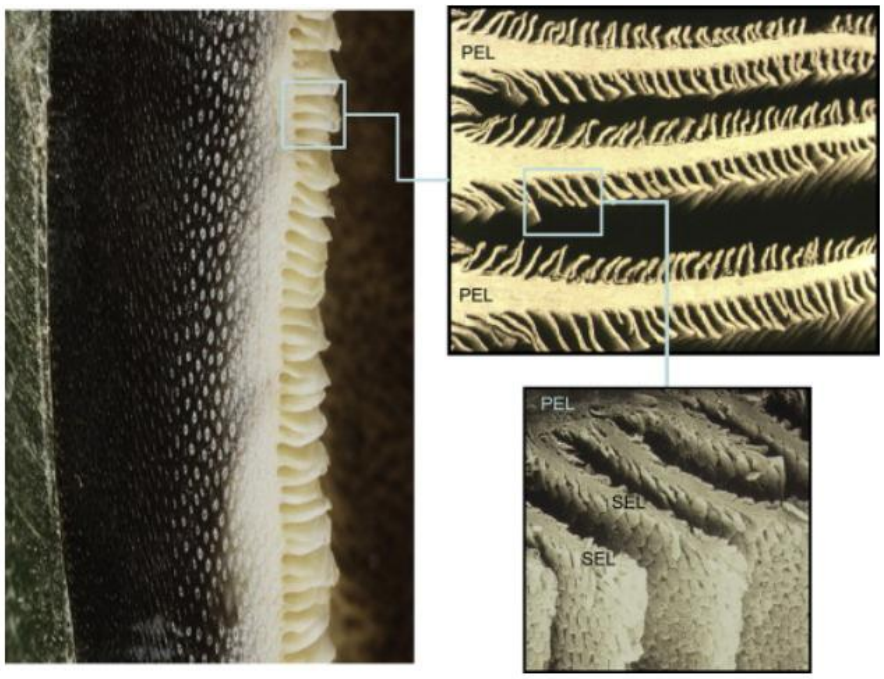

Source: Ehrmann et al (2021).

The vascularization of the entire structure is performed by branching the palmar, lateral plantar and medial digital arteries extending to the dorsal surface of the hoof, where there is the occurrence of anastomosis giving rise to the terminal arch. It is these vessels that are responsible for nourishing the entire hoof, while at the same time constituting a gateway for inflammatory cells (Leise; Fugler, 2021).

PATHOPHYSIOLOGY OF ENDOTOXEMIA-RELATED LAMINITIS, SYSTEMIC INFLAMMATORY RESPONSE SYNDROME/SEPSIS

The term laminitis is reported as a consequence of pathological events that culminate in the failure of the suspensory apparatus of the distal phalanx of the horse. Although the pathophysiology of this alteration has not been completely elucidated, it is possible to differentiate the clinical situations in which it manifests itself (Pollitt, 2010). Thus, its main presentations are related to sepsis, mechanical overload and endocrinopathies. Although the triggering events are different, there is a disconnection of the lamellar epithelium and cell stretching, which are characteristic of the failure of the suspensory apparatus of the distal phalanx (Ehremann et al., 2021).

It is seen that the structural integrity of the lamellae depends on the maintenance of the cell cytoskeleton as well as the connection between the lamellar basal epidermal cells. When stretching forces occur between the corneal case and the distal phalanx, there is a structural failure that overcomes the resistance of the suspensory apparatus of the distal

phalanx. Thus, the extent of the damage, severity and sum of the forces acting on this apparatus are directly related to the evolution of the condition (Marcato; Perillo, 2020).

Laminitis related to sepsis is acute, and sepsis is characterized as a systemic inflammatory state with the presence of an infection. Sepsis can occur due to several factors in the equine species, some of them are: metritis, broncho and pleuropneumonia, gastrointestinal disorders that include duodenitis/proximal jejunitis, grain overload, enterocolitis, dysbiosis, as well as strangulative obstructions (Leise; Fugler, 2021). However, the most common main cause of this complication is in fact gastrointestinal imbalances. A study conducted at a university veterinary hospital found that the main and most common conditions in 54% of horses that developed laminitis are: surgical colic, acute diarrhea, and proximal enteritis (Galantino; Brooks, 2020).

When gastrointestinal lesions and imbalances occur, there will be a favor for the multiplication of gram-negative bacteria that release lipopolysaccharides (LPS) into the circulation, also known as endotoxin. The LPS precedes the entry of the bacteria themselves into the vessels. Thus, it will initiate the triggering of endotoxemia and an acute phase inflammatory response (Coelho et al., 2023).

Endotoxemia is characterized by the presence of endotoxins (lipopolysaccharides; LPS) of bacterial origin in the systemic circulation. LPS are present in the outer membrane of Gram-negative bacteria that make up the gut microbiota of animals, along with Gram-positive bacteria and protozoa. Endotoxins are released when a gastrointestinal imbalance occurs for some reason, leading to rapid replication, lysis, or bacterial death (Laskoski et al., 2016). Horses are particularly sensitive to the effects of endotoxins, because species that have populations of fixed macrophages (Kupffer cells), like them, are more susceptible to generating these conditions. Plasma concentrations in the range of 10-10 to 10-7 g/mL are related to the presence of severe clinical signs, including cardiovascular and hemodynamic disorders (Marcato; Perillo, 2020).

Endotoxins have a hydrophobic region, and therefore tend to form aggregates in the plasma interacting with high-density lipoproteins, which prolongs their half-life in the circulation, and reduces their ability to interact with pro-inflammatory cells. However, when LPS joins the lipopolysaccharide-binding protein, the molecule is removed from the aggregate, facilitating its interaction with a CD14 cell surface receptor, existing in mononuclear phagocytes (Leise; Fugler, 2021). To transmit the signal into the cell, it is necessary to activate a pattern recognition receptor, which activates the synthesis of pro-inflammatory mediators. The inflammatory cascade will be variable according to the type of receptor triggered, virulence of the pathogen, and the presence of co-stimulation.

Endotoxemia is a major risk factor for the development of acute laminitis in horses during hospitalization for medical or surgical conditions (Ehremann et al., 2021).

Thus, the fundamentals regarding the involvement of systemic inflammatory response syndrome (SIRS) in the pathogenesis of laminitis are based on the presence of LPS, circulating proinflammatory cytokines such as tumor necrosis factor (TNF-) and interleukins (IL)-1 and -6, reactive oxygen species, leukocyte tissue infiltration. (Galantino; Brooks, 2020). If its origin is infectious, it becomes sepsis and also allows the association with organ failure, where this inflammatory response causes injuries in places far from the site of the problem. The possible explanation for this may be the low amount of the enzyme superoxide dismutase (SOD) in the laminar tissue of horses. This enzyme reduces the deleterious tissue effects of reactive oxygen species, playing an antioxidant role, and is present in small quantities in dermal lamellae, when compared to other organs (Leise; Fugler, 2021).

The barrier mechanisms of the hoof resemble those of the skin, as it is an extension of it. The primary aptitude of the integument is the ability to recognize pathogen-associated molecular patterns (PAMPs) and damage-associated molecular patterns (DAMPs). When absorbed in the intestinal mucosa, these patterns circulate through the body and reach the lamellae (Laskoski et al., 2016). When pattern recognition receptors (PRRs) such as Toll-like receptors (TLR) and Nod are activated, activation of resident immune cells and hoof keratinocytes occurs, which promote inflammatory signaling, rolling, and adhesion of leukocytes to the endothelium. Resident macrophages can also secrete metalloproteinases (MMPs), which degrade the extracellular matrix, culminating in a lamellar inflammatory response, leading to local damage, dysfunction and organ failure such as the failure of the suspensory apparatus of the horse's distal phalanx (Marcato; Perillo, 2020).

Recently, there have been a large number of studies to better investigate the mechanisms involved in the pathogenesis of this disease, among which the enzymatic mechanism is suggested. Initially, the enzymes involved are type 2 and 9 matrix MMPs. Their activity occurs constantly in situations of physiological stress (Laskoski et al., 2016). When they are released, the result is collagen degradation during the physiological remodeling of the extracellular matrix, interruption of lamellar connections, leading to degradation of corneal lamellae and collagen (Galantino; Brooks, 2020). The mechanism by which they are activated is not yet well known, however, bacterial toxins from the gastrointestinal tract and inflammatory cytokines triggered by SIRS are suggested as triggers. Thus, it is proposed that the dysregulation of the lamellar matrix is characterized as an important event in the pathophysiology of this condition (Leise; Fugler, 2021).

EXPERIMENTAL MODELS OF LAMINITIS ASSOCIATED WITH SYSTEMIC INFLAMMATORY RESPONSE SYNDROME

Different conditions lead to structural failure of the suspensory apparatus of the distal phalanx of horses, and the study of laminitis induction models allow a better understanding of the mechanisms involved (Coelho et al., 2023).

There are three experimental induction models used to study SIRS-associated laminitis. The first model developed is the carbohydrate overload (CHO), established in order to mimic grain overload in the horse's diet. In this model, the animal receives a mixture of 17.6 g/kg of corn starch (85%) and wood flour (15%) through nasogastric intubation (Leise; Fugler, 2021). Alterations in the cecum microbiota will result in a drop in pH and increase the population of gram-positive bacteria, with consequent death of gram-negative bacteria. A release of endotoxins and increased mucosal permeability will result in SIRS, with clinical signs of fever, diarrhea, colic, and dehydration. After 24 to 48 hours, there is the onset of Obel's grade 1 laminitis, and after 40 to 72 hours, Obel grade 3 laminitis (Laskoski et al., 2016).

There is another carbohydrate model developed to mimic laminitis as a consequence of eating fructans in lush pastures. By administering 7.5 to 12.5 mg/kg of body weight through nasogastric intubation of non-structural oligofructose carbohydrate extracted from chicory roots. Resulting in self-limited diarrhea, septic with fluid and electrolyte losses very similar to animals with colitis (Galantino; Brooks, 2020). In this case, there is also an alteration in the cecal microbiota and the production of endotoxins, lactic acid and a sudden reduction in pH. In approximately 20 to 30 hours there will be the appearance of clinical signs of Obel grade 1 laminitis (Leise; Fugler, 2021).

The last model associated with SIRS is black walnut extract. The animals receive 2g/kg of body weight through nasogastric intubation obtained by immersing shavings from the heartwood of a black walnut tree. In approximately 3 to 4 hours there is leukopenia followed by rapid-onset claudication (Dos Santos Mendes et al., 2021).

In the meantime, similarities between these models and the sepsis models studied in mice are observed. The (CHO) model can mimic polymicrobial cecal ligation and puncture, leading to an inflammatory response. The black walnut model, on the other hand, reproduces in a very similar way the intraperitoneal administration of endotoxin, resulting in a rapid and intense peak of inflammation (Almeida; Queiroz; Biava, 2017).

The main difference between them is the duration and severity of the inflammatory response. There are several studies that have been conducted using these models in order

to be able to determine the real pathophysiology of laminitis associated with sepsis/SIRS (Pollitt, 2010). When each of these foods is administered, changes in the gastrointestinal tract are evidenced, in addition to the alteration of the microbiota, lesions occur in the mucosa and facilitate the absorption of PAMPs and DAMPs. These molecular patterns can reach the liver, lungs, and kidneys (Van Eps; Burns, 2019).

It was observed that horses that did not develop SIRS after administration of these products were also not affected by laminitis. Thus suggesting that preventing SIRS also prevents lamellar failure (Dos Santos Mendes et al., 2021).

In addition to these experimental models, it is important to emphasize that there are factors in everyday life that can predispose to the occurrence of gastrointestinal disorders/SIRS/sepsis. One of them is the unnecessary administration of antibiotics, which can be associated with enterocolitis, leading to a great imbalance (Van Eps; Burns, 2019). Colon evacuation surgeries can also be a factor, as it greatly decreases the presence of the resident microbiota. Gastritis and ulcers can also favor bacterial translocations. The inappropriate use of non-steroidal anti-inflammatory drugs, as they inhibit the synthesis of prostaglandin E and E2 (Pollitt, 2010).

SIGNALING PATHWAYS INVOLVED IN SEPSIS-ASSOCIATED LAMINITIS AND SYSTEMIC INFLAMMATORY RESPONSE SYNDROME

The interaction of multiple pathways involved in the development of laminitis associated with SIRS and sepsis results in redundancies of complex mechanisms causing dysregulation of the inflammatory response at various stages of the disease.

As already discussed, SIRS begins with the recognition of immunogenic agents or injured cells through the receptors of the Toll-like innate immune system (TLR). Several cells in the body, as well as those of the innate immune system, have these receptors. There are 10 of these receptors that are known, and the first and best is TLR-4 that binds with the LPS of gram-negative bacteria, and together with CD14 an easy binding to the receptor will occur (Dos Santos Mendes et al., 2021). The transduction signal, after the interaction between the ligand and the receptor, culminates in the activation of intracellular molecular adapters such as MyD88 (myeloid differentiation protein) and TRIF (protein adaptor of cytoplasmic receptors of toll-interleukin-1, interferon-inducer), and with protein kinases. It will then initiate a signaling cascade, and nuclear factor-κB (NF-κB) is subsequently translocated to the nucleus, where it stimulates the transcription of more than 40 different pro-inflammatory genes (Leise; Fugler, 2021).

According to Sheats (2019), there is an increase in TLR-2 and TLR-4 expression found in lamellar epithelial basal cells of horses affected by laminitis due to carbohydrate overload. These are responsible for initiating the transcription of pro-inflammatory cytokines, such as IL-1, IL-6, IL-8, and TNF alpha.

STATs are signal transducer activators of transcription factors that, when activated, translocate to the nucleus and produce several inflammatory genes. These STATs form dimers and trigger the production of inflammatory mediators, eicosanoids, cytokines, chemokines, and enzymes (Laskoski et al., 2016). These, in turn, will alter the endothelial permeability of the vessels and activate platelets, increasing the influx of neutrophils into various tissues. With this, the coagulation cascade will also be activated. In this way, the inflammation will settle in the hoof (Sheats, 2019).

Cell death occurs by the activation of caspases, found in the form of proenzymes in the cell cytosol, causing DNA destruction, by activation of DNAase in the cell nucleus, and disorganization of the normal structure of the cell cytoskeleton (Leise; Fugler, 2021).

PATIENT ASSESSMENT

The rapid identification of the clinical picture allows the immediate initiation of therapies in order to limit inflammation and prevent lamellar lesions. An equine can be considered to be in SIRS if it manifests 2 out of 4 parameters (Divers, 2010). They are:

1. Cadic rate above 52bpm
2. Respiratory rate above 20bpm
3. Rectal temperature below 37°C or above 38.5°C
4. WBC count less than 5 x 109 or greater than 12.5 x 109

In addition to these parameters, other clinical findings may be associated with endotoxemia such as: prolonged capillary filling time, hyperemic or pale mucous membranes, hyperlactatemia, hemoconcentration, abdominal pain, diarrhea, depression, hyperglycemia in adults and hypoglycemia in foals, thrombocytopenia, and abortions (Luz et al., 2021).

When laminitis develops, it is possible to observe an increase in the temperature of the hoof wall and throbbing pulse of the palmar digital artery concomitant with claudication, pain and reluctance to move, change in posture, trying to remove pressure from the affected limb (Figure 4). It is more common to have an incidence in the thoracic limbs, however, all four limbs may be affected. The definitive

identification of sepsis is carried out through the isolation of the pathogen (Almeida; Queiroz; Biova, 2017).

Figure 4. Animal in typical laminitis posture, leaning back in order to relieve pressure on the affected thoracic limbs.



Source: Marcato; Perillo (2020).

The episodes can be recurrent and euthanasia has often been indicated due to the permanent damage caused to the hoof. This is because once the devastating pathophysiological cascade of the disease begins, anatomical deviations can occur so extensive that there is not much chance that the animal's foot will be able to return to its homeostasis (Luz et al., 2021).

When examining the equine hoof, considerable congestion of the dermal gills and/or bleeding phenomena is usually evident. In very acute cases, when the dermal-epidermal junction is undone, the third phalanx may detach from the hoof and descend ventrally into the hoof (Almeida; Queiroz; Biava, 2017). Rotation of the third phalanx in the opposite direction to the dorsal wall, or distal displacement of the third phalanx. Depression and hemorrhagic fusion in the coronary sulcus are also observed (Pollitt, 2010).

In horses, the distance between the outer wall of the hoof and the dorsal aspect of the third phalanx should be less than 18mm. By taking an X-ray of the patient's foot, it is possible to take the measurement. If there is an increase in distance, it is indicative of hemorrhage and inflammatory edema in the lamellae (Marcato; Perillo, 2020). This is because the tissue that keeps the bone aligned and in the correct place loses its consistency and fails, as the flexor tendon pulls on the phalanges and starts the rotation

of the bone and its tip goes towards the sole, tending to attach itself in this place. Then the sole protrudes from concave to convex, causing the deformation of the hoof. By continuing the rotation, the third phalanx can penetrate the sole of the foot (Galantino; Brooks, 2020).

Figure 5. A: Parasagittal section of a normal hoof. B: Parasagittal section of a hoof affected by severe chronic laminitis. It can be seen that the bone rotated and the sole became convex PB: third falnge. ET: flexor tendon. WL: white line. K: ceraphylocele.

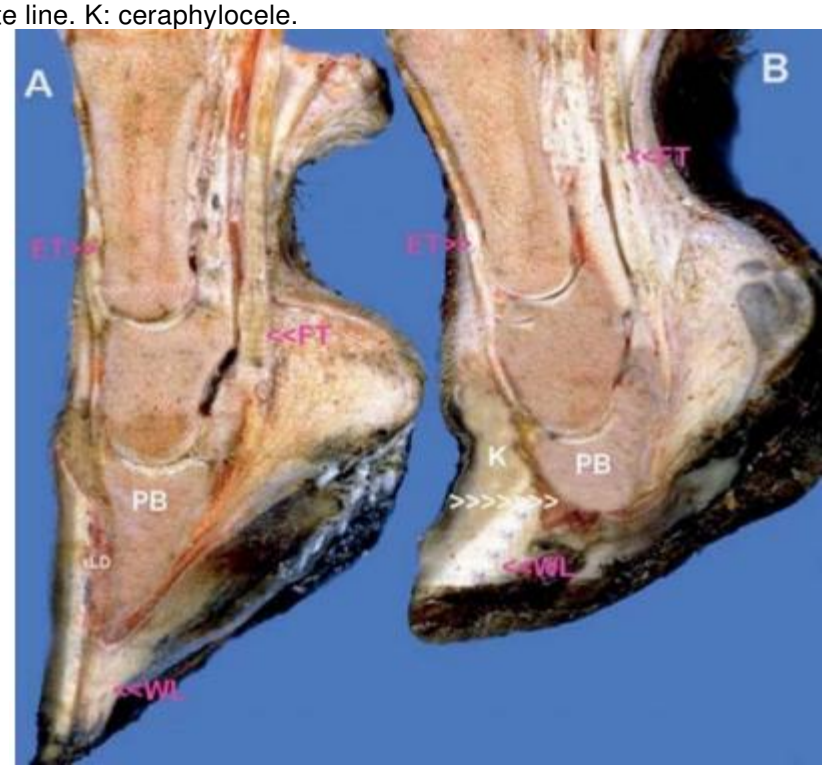

Source: Marcato; Perillo (2020).

Although several studies evaluating ideal biomarkers for this problem have not yet been identified. It is seen that SIRS-associated laminitis has identified an upregulation of some inflammatory cytokines within the lamellae, among them are interleukin 6, interleukin IL-1β, and cyclooxygenase-2 (COX-2) (Tuniyazi et al., 2021). Due to the difficulty of obtaining specific reagents in horses, it has been challenging to identify inflammatory mediators. However, the following were identified as potential markers: serum amyloid A, procalcytononia, and calprotectin (Ehrmann et al., 2021).

The Obel system (1948) is a classification used to define the severity of lameness. It is divided into:

- Grade 1: consists of altering and elevating the limbs incessantly.
- Grade 2: difficulty in supporting on hard ground, elevation of the limb with difficulty, despite moving voluntarily.
- Grade 3: reluctance to walk, resistance to lifting the limb.
- Grade 4: Refusal to move and lift the limbs.

The diagnosis should be made by obtaining the clinical history, characteristic clinical signs, radiographic and venographic findings. However, a complete examination of the hoof with special attention to palpation of the coronary band is very important. There are three pieces of information that are essential to be collected in the evaluation of a patient and in the formulation of a diagnostic, therapeutic and prognostic plan: the reason and cause of pain, location of pain and the degree of instability within the hoof (Welsh et al., 2017).

TREATMENT AND PREVENTION

To try to prevent laminitis it is necessary to start with the appropriate treatment for the disease or primary condition, and provide supportive care. With the administration of intestinal and/or cathartic adsorbents for grain overload; Surgical corrections with removal of ischemic follow-up and necrotic tissue; Use of antibiotic therapy in cases of bacterial infections; Correction of hyperglycemia/hypoglycemia; correction of acidosis, hypocalcemia, hypokalemia, hypomagnesemia; Correction of diarrhea and vomiting (Sheats, 2019). Thus, cardiovascular fluid resuscitation is a crucial point in animals with signs of shock, and should include sufficient crystalloids and colloids to provide adequate tissue perfusion to meet the oxygenation and energy demands of the slides. However, once the cardiovascular status is stable, judicious fluid therapy rates should be evaluated to minimize as much as possible the effect of Starling forces by which excess intravenous fluids can lead to lamellar edema (Leise; Fugler, 2021).

There are also factors such as race, age, weight, intensity of the primary insult, previous endocrinopathic disorders, immunocompetence, among others that will influence the susceptibility and degree of lamellar injury. That is why the treatment of laminitis can be so challenging (Welsh et al., 2017).

It is well documented that the gills of the equine digit characterize a strong pro-inflammatory response to systemic disease. In particular, an increase in COX-2 expression has been reported to occur with experimentally induced SIRS-associated laminitis. Thus, nonsteroidal anti-inflammatory drugs are the most common drugs used in the course of the disease. The preferred medication has been flunexin meglumine 1mg/kg IV SID (Sheats, 2019). However, it has recently been found that in cases of septic processes associated with disorders in the gastrointestinal tract, flunexin may not be as effective. This is because studies have shown that the inhibition of COX – 1 (cyclooxygenase-1) delays repair mechanisms in the intestine and slows down the recovery process of the jejunal mucosa in

ischemic lesions. As a result, Firocoxib has been recommended, which is a high selective inhibitor of COX-2, reducing the risk of gastrointestinal side effects (Leise; Fugler, 2021).

The use of dimethylsufoxide (DMSO) is supported for its purported anti-inflammatory effects and free radical scavenging ability when administered before, during, and several hours after the insult. It can be used from 20 to 50mg/kg SID (Tuniyazi et al., 2021).

Pentoxifylline is a phosphodiesterase inhibitor used by clinicians in the treatment of laminitis for its rheological and anti-inflammatory effects. It has been widely recommended for improving capillary blood flow, increasing red blood cell deformability, and reducing blood viscosity (Sheats, 2019). In addition, this drug has been suggested as a possible effective treatment against endotoxemia/SIRS due to its ability to inhibit tumor necrosis factor-alpha (TNF-α) and other proinflammatory cytokines. It is recommended to administer 8.5 to 10 mg/kg orally every 8 to 12 years. It can also be administered slowly IV at a dose of 8.5 mg/kg every 8 to 12 hours (Tuniyazi et al., 2021).

As an antimicrobial, it is possible to mention polymyxin B that binds to the lipid-A portion of LPS, preventing it from activating the macrophage neutralizing the actions of endotoxin. It also neutralizes the gram-positive toxins lipoteichoic acid (LTA) and peptidoglycan. at substantially lower serum concentrations it may exert antiendotoxic effects (Leise; Fugler, 2021). When used in the antimicrobial dose, caution should be exercised as there is the possibility of nephrotoxicity. It can be administered at a dose of 6000 U/kg IV every 8 to 12 hours diluted in 1 L of saline. It is important that it is administered early in the course of treatment, as it has been shown that its effect is most effective before the release of endotoxin (Coelho et al., 2023).

The activation of proteases makes the generic dependence of one digit per limb susceptible to the deleterious effects of the disease. Interestingly, the process of laminitis development can be disrupted if enzyme activity in the hoof is inhibited by exposing the limb to temperatures close to 5°C. Digital hypothermia, or digital therapeutic cryotherapy, is the only proven therapy capable of preventing the occurrence of laminitis (Leise; Fugler, 2021). It is stated that this therapy can significantly reduce the expression of MMP-2 and other pro-inflammatory mediators within the lamellae when initiated prior to the onset of claudication. In addition, it also prevents the migration of leukocytes to the lamellae. However, no benefits were observed after the onset of claudication. The suggested protocol requires maintenance of hoof temperatures ≤5°C through submersion in a boot of ice water until resolution of the primary disease (Welsh et al., 2017).

Systemic inflammation can activate coagulation factors and lead to a downregulation of thrombin production and coagulation pathways. Also, it is possible that there is an

influence on the function of endothelial cells, further contributing to inflammation. In view of this, drugs that inhibit platelet activation can help, such as low molecular weight heparin 40 to 80IU/kg IV or subcutaneous every 8 hours (Tuniyazi et al., 2021). According to Welsh et al (2017), it inhibits the prothrombotic state, in addition to helping to reduce the occurrence of laminitis in postoperative cramps. The adenosine diphosphate P2Y receptor antagonist, clopidogrel, has also been shown to inhibit platelet aggregation, prolonging this effect up to six days after being administered. Therefore, although it is a good option, studies are still needed to determine its effects. It is administered as a loading dose, 6 to 6.5 mg/kg of body weight, followed by 2 mg/kg orally at 24-hour intervals (Galantine; Brooks, 2020).

Lidocaine can also be used in these cases, due to its analgesic and also anti-inflammatory properties. Although it is still somewhat questioned, its use can bring benefits to the patient (Sheats, 2019).

In addition, a mechanical support is essential to reduce the forces exerted on the digit and limit the injury. Thus, the therapeutic horseshoe stands out, which aims to compensate for the mechanical limitations of the limb and favor healing (Leise; Fugler, 2021). Due to the relationship between the digital structures, when any part of the hull is injured due to various factors, there will be a cascade of events that imply an erroneous growth and distortion of the hull capsule, and so when an area is affected, more areas will fail. With this, there is also the option of therapeutic trimming of the hoof, with special techniques for trimming and shoeing (Galantino; Brooks, 2020).

There are several therapies that are being studied in order to reduce the risk of developing the pathology in question (Tuniyazi et al., 2021). There is a drug called reparexin that can inhibit the migration of neutrophils, reduce the expression of cytokines such as: and IL-1β and IL-6 and thus reduce clinical signs. There is also leukapheresis used experimentally, which removes leukocytes from the systemic circulation. In research, it can be observed that there was a reduction in neutrophils and monocytes in the circulation, reducing the chances of developing SIRS and laminitis (Welsh et al., 2017).

FINAL CONSIDERATIONS

Equine laminitis in association with SIRS is a complex, multifactorial condition that requires a multidisciplinary approach to its treatment and management. Understanding the signaling pathways involved and the pathophysiology is critical to developing effective treatments and improving the prognosis of affected horses. However, both are not yet fully elucidated, and more research and studies are needed in order to guide the establishment of the prognosis, guide the therapy and improve the quality of life of the animals.

Numerous treatments are proposed, but many of them have not proven their effectiveness. There are still divergences, and the veterinarian needs to choose the one that seems most assertive. Likewise, treatment needs to be started as soon as possible, or even before laminitis sets in, so that the patient's chances of recovery can be increased.

REFERENCES

1. Almeida, C. P.; Queiroz, S. S.; Biava, Janaína Socolovski. Radiographic and histopathological alterations in an equine with chronic laminitis–case report. Academic Journal of Equine Science, v. 1, n. 1, p. 1-6, 2017. Accessed on: October 31, 2024. Available at: https://www.gege.agrarias.ufpr.br/grupeequi/racequi/artigos/2017/laminite%20cronica.pdf.

2. Coelho, Nathália das Graças Dorneles et al. Chronic laminitis in horses: radiographic aspects. JOURNAL OF ACADEMIC WORKS – UNIVERSO BELO HORIZONTE, v. 1, n. 8, 2023. Accessed on: October 30, 2024. Available at: revista.universo.edu.br/index.php?journal=3universobelohorizonte3&page=article&op=view&path%5B%5D=12423&path%5B%5D=7142.

3. Dos Santos Mendes, Ana Beatriz et al. Therapeutic potential of mesenchymal stem cells in equine laminitis. Research, Society and Development, v. 10, n. 10, p. e436101018902-e436101018902, 2021. Accessed on: October 31, 2024. Available at: https://rsdjournal.org/index.php/rsd/article/view/18902.

4. Dyce, K. M.; Sack, W. O.; Wensing, C. J. Treatise on Veterinary Anatomy. 3. ed. Rio de Janeiro: Elsevier Editora Ltda, 2004. 813p.

5. Divers, Thomas J. Clinical application of current research findings toward the prevention and treatment of acute laminitis in horses with systemic inflammatory diseases: An internist's perspective. Journal of Equine Veterinary Science, v. 30, n. 9, p. 517-524, 2010. Accessed on: October 30, 2024. Available at: https://www-sciencedirect-com.ez26.periodicos.capes.gov.br/science/article/pii/S0737080610003515?via%3Dihub.

6. Ehrmann, Carolin et al. Evaluation of platelet biology in equine patients with systemic inflammatory response syndrome. Journal of Veterinary Diagnostic Investigation, v. 33, n. 2, p. 300-307, 2021. Accessed on: October 30, 2024. Available at: https://journals.sagepub.com/doi/full/10.1177/1040638720983791

7. Galantino-Homer, Hannah; Brooks, Samantha A. Genetics and signaling pathways of laminitis. Veterinary Clinics: Equine Practice, v. 36, n. 2, p. 379-394, 2020. Accessed on: October 30, 2024. Available at: https://www-sciencedirect-com.ez26.periodicos.capes.gov.br/science/article/pii/S0749073920300262?via%3Dihub.

8. Leise, Britta Sigrid; Fugler, Lee Ann. Laminitis Updates: Sepsis/Systemic Inflammatory Response Syndrome–Associated Laminitis. Veterinary Clinics: Equine Practice, v. 37, n. 3, p. 639-656, 2021. Accessed on: October 30, 2024. Available at: https://www-sciencedirect-com.ez26.periodicos.capes.gov.br/science/article/pii/S0749073921000559?via%3Dihub#bib30.

9. Laskoski, Luciane Maria et al. Oxidative stress in hoof laminar tissue of horses with lethal gastrointestinal diseases. Veterinary immunology and immunopathology, v. 171, p. 66-72, 2016. Accessed on: October 30, 2024. Available at: https://www-sciencedirect-com.ez26.periodicos.capes.gov.br/science/article/pii/S0165242716300125?via%3Dihub.

10. Luz, Gabriela Bueno et al. Laminitis in horses: review. Brazilian Journal of Development, v. 7, n. 3, p. 32635-32652, 2021. Accessed on: October 30, 2024. Available at: https://ojs.brazilianjournals.com.br/ojs/index.php/BRJD/article/view/27355/21651.

11. Marcato, Paolo Stefano; Perillo, Antonella. Equine laminitis, new insights into the pathogenesis: A review. Large Animal Review, v. 26, n. 6, p. 353-363, 2020. Accessed on: October 30, 2024. Available at: https://www.largeanimalreview.com/index.php/lar/article/view/155.

12. Pollitt, Christopher C. The anatomy and physiology of the suspensory apparatus of the distal phalanx. The Veterinary Clinics of North America. Equine Practice, v. 26, n. 1, p. 29-49, 2010. Accessed on: October 30, 2024. Available at: https://www-sciencedirect-com.ez26.periodicos.capes.gov.br/science/article/pii/S0749073910000064?via%3Dihub.

13. Sheats, M. Katie. A comparative review of equine SIRS, sepsis, and neutrophils. Frontiers in veterinary science, v. 6, p. 69, 2019. Accessed on: October 30, 2024. Available at: https://www.frontiersin.org/journals/veterinaryscience/articles/10.3389/fvets.2019.00069/full.

14. Tuniyazi, Maimaiti et al. Changes of microbial and metabolome of the equine hindgut during oligofructose-induced laminitis. BMC veterinary research, v. 17, p. 1-13, 2021. Accessed on: October 30, 2024. Available: https://link.springer.com/article/10.1186/s12917-020-02686-9

15. Van Eps, Andrew W.; BURNS, Teresa A. Are there shared mechanisms in the pathophysiology of different clinical forms of laminitis and what are the implications for prevention and treatment?. Veterinary Clinics: Equine Practice , v. 35, n. 2, p. 379-398, 2019. Accessed on: October 30, 2024. Available at: https://www.vetequine.theclinics.com/article/S0749-0739(19)30022-7/abstract.

16. Welsh, C. E.; Duz, M.; Parkin, T. D.; et al. Disease and pharmacologic risk factors for first and subsequent episodes of equine laminitis: A cohort study of free-text electronic medical records. Preventive veterinary medicine, v. 136, p. 11-18, 2017. Accessed on: October 30, 2024. Available at: https://www.sciencedirect.com/science/article/pii/S0167587716305815?casa_token=h6EhjapWPXAAAAAA:4vk-uNjeI4MKN7n2W8WmzSS_uGo_JHVJU45v6gtnfL6TD_eaaBklrp83-gVsE26p8clBtfbBF-0.