

SONOGRAPHIC CHARACTERISTICS OF ACCESSORY CORPORA LUTEA IN PREGNANT ACYCLIC AND CONVENTIONAL PREGNANT CYCLIC RECIPIENT MARES



<https://doi.org/10.56238/arev7n4-267>

Submitted on: 03/25/2025

Publication date: 04/25/2025

Laura Escáfura Ramalho¹, Eduardo Shimoda² and José Frederico Straggiotti Silva³

ABSTRACT

The finding that hormonally treated acyclic recipient mares can maintain pregnancy through their endogenous production, after the formation of accessory corpora luteum, would reduce the expenses with P4 supplementation in Embryo Transfer programs. The experiment consisted of ultrasonographic evaluations of the ovaries of acyclic recipient mares supplemented with exogenous progesterone (anestrus period) and conventional cyclic mares (breeding season). Pregnancy was found at 15 days of gestation, and the following evaluations were made in the period of formation of the corpora luteum at 30 days of gestation and at gestational follow-up, at 60 and 90 days. The images were recorded and cropped in the region of the corpora lutea and treated in the Pixel Analyser application with the objective of analyzing their dimensions through the pixel color density. The areas of importance were the hyperechoic ones, which represent the parenchyma of these structures, up to 120 days of gestation, estimating whether the P4 production capacity per area in the experimental group would be similar to that of the control group. This would allow us to suppose the possibility of maintaining the pregnancy without exogenous P4 supplementation, which would reduce the costs of hormonal treatment. The statistical analysis consisted of comparing the means between the treatments of the control and experimental groups. Considering that, although at 60 days there is no statistical difference in the size of the hyperechogenic areas, due to the differences between the groups at 90 days of gestation, it would not be advisable to cease hormone supplementation with complete safety, and more information on the subject is needed.

Keywords: Recipient mares. Reproduction. Accessory corpus luteum. Ultrasound. Pregnant. Progesterone.

¹Master of Science in Animal Sciences

Institution: State University of Norte Fluminense (UENF)

Address: Campos dos Goytacazes, Rio de Janeiro, Brazil

Email: lah.ramalho@hotmail.com

²Dr. in Animal Production

Institution: Cândido Mendes University (UCAM)

Address: Campos dos Goytacazes, Rio de Janeiro, Brazil

Email: shimoda@ucam-campos.br

³Dr. of Veterinary Medicine

Institution: State University of Norte Fluminense (UENF)

Address: Campos dos Goytacazes, Rio de Janeiro, Brazil

Email: straggio@uenf.br

Lattes ID: 1845406575748415

INTRODUCTION

Research released by the IBGE shows that equine breeding in the country maintains a positive growth and reached close to six million head in 2020. Thus, equine reproduction biotechnologies are essential for this sector to develop more and more.

The use of the biotechnological tool called Embryo Transfer (ET) is a way to increase the birth rates of products better selected in the stud farms (Lira, 2009). The donor mares, which are zootechnically superior mares, donate the embryos that will be transferred to the recipient mares and generated by them, due to their lower zootechnical value. There is a high demand and a limited number of cyclic receiver mares available during the transitional phase. The availability of recipient mares has become a limiting factor, especially during the beginning of the breeding season, since part of the recipients are in anestrus due to seasonal reproductive activity.

Ultrasonography and transrectal palpation should be routine exams for reproductive control of mares, as it allows the evaluation of the morphology and functionality of the reproductive system, follicular control and classification of the corpus luteum (CL), responsible for producing progesterone (P4). Pregnancy maintenance is done by the concentration of P4. The mare has the peculiarity of having, in addition to the primary corpus luteum (CLp), originating from the ovulated follicle, the accessory corpora lutea (CLa), originating from new follicular waves and responsible for complementing the production of P4 from 36 to 40 days of gestation until about 150 days, when the placenta becomes responsible for this function until the end of gestation (Silva et al., 2012). Knowing that the development of accessory corpora lutea (CLa) is responsible for supplemental progesterone synthesis until gestation becomes placental-dependent, it is likely that treatment with exogenous progesterone in acyclic pregnant recipient mares can be stopped earlier during gestation.

BACKGROUND

Embryo transfer (ET) is a technique developed worldwide and disseminated in most horse breeders' associations, with Brazil, Argentina and the United States being the countries that have the largest number of embryos transferred per year. However, an important limiting factor in ET programs is the reduced number and quality of recipient mares during the breeding season. There is a high demand and a limited number of cyclic receiver mares available during the transitional phase. The availability

of recipient mares has become a limiting factor, especially during the beginning of the breeding season, since part of the recipients are in anestrus due to seasonal reproductive activity. In addition, the differential feeding management usually provided to donor and recipient mares may delay the onset of cyclicity in recipients.

To increase the supply of recipient mares in ET programs, estrogen and/or progesterone (P4) treatments can be administered to non-cyclic recipient mares.

Considering that the development of accessory corpora lutea (Cla) is responsible for supplemental progesterone synthesis until gestation becomes placental-dependent, it is likely that exogenous progesterone treatment in acyclic pregnant recipient mares can be stopped earlier during gestation. To test the hypothesis that non-cyclic pregnant recipient mares develop Cla capable of maintaining pregnancy, we evaluated: ultrasonographic images of the accessory corpora lutea of acyclic pregnant recipient mares supplemented with P4, comparing with the corpora lutea of cyclic pregnant recipient mares to infer the possibility of supplementation being able to cease before 90 days of gestation, which represents savings for the equine owner.

OBJECTIVES

The objective of this study was to verify the presence and development of accessory corpora lutea in pregnant acyclic recipient mares supplemented with exogenous progesterone, seeking to infer whether the sonographic image of the accessory body(s) luteum (s) of hormonally treated acyclic recipient mares could predict the possibility of maintaining the pregnancy through its endogenous production. In this way, it would be possible to reduce expenses with hormonal treatments in Embryo Transfer programs, since exogenous progesterone represents a large part of these.

THEORETICAL FRAMEWORK

In the last 20 years, several countries such as the USA, Brazil and Argentina have widely used Embryo Transfer in horses. Some factors can alter the results of ET, such as the quality of the stallion's semen, the selection of the donor, and the transfer method chosen. However, the most important factors in this program are the reproductive control and synchronization of mares and the selection of recipients, considering first the general

physical state of the female, temperament for management, reproductive history and maternal aptitude (Hartman 2011).

The reproductive cycle of the mare can be divided into the follicular phase, called estrus, in which there is the action of Estrogen (E2) and the mare is sexually receptive to copulation, with her genital tract ready for covering. The other phase of the reproductive cycle is the luteal phase, called diestrus, in which there is the action of progesterone (P4) and the mare is not receptive to copulation, and her genital tract is prepared for the implantation and development of an embryo. The diestrus period ends with the regression of the corpus luteum (CL), followed by the follicular phase (Daels; Hughes, 1993).

The average length of the equine estrous cycle is 21.7 ± 3.5 days, with the follicular phase having an average duration of 6.5 ± 2.6 days and the luteal phase of 14.9 ± 2.8 days during the physiological mating season (Ginther, 1992).

The corpus luteum was discovered in 1573 by Coiter (Luz, 2004). After several studies, it was concluded that the corpus luteum is a transient endocrine gland that develops in the ovary after ovulation, through the growth, differentiation, reorganization and luteinization of the remaining theca and granulosa cells of the ovulated follicle (Davis; Rueda, 2002). It is made up of small and large steroidogenic luteal cells that in each cycle, together with fibroblasts, are responsible for the production of progesterone (Bertan, 2006), identified in 1929 by Corner and Allen as the main hormone secreted by the corpus luteum. In 2007, Stocco concluded that CL is essential to regulate the estrous cycle and allow the maintenance of pregnancy.

After gaining blood circulation, P4 performs physiological action on several target tissues. This hormone promotes the formation of a uterine environment suitable for embryonic development, with the glandular development of the endometrium, responsible for the production of uterine milk (Mc Kinnon; Voss, 1992) who nourishes the embryo until the end of the placentation. In the absence of fertilization or in the inability of the conceptus to signal its existence in utero, prostaglandin pulses (PGF2 α) are released by endometrial cells, promoting luteolysis. Thus, diestrus ends, starting a new estrus (Webb et al., 2002; Bertan, 2006). In horses there is the formation of accessory CL in the gestational period. Around 38 days, the trophoblastic cells of the chorionic belt of the embryonic vesicle invade the uterine epithelium, differentiating into endometrial calyces. These placental structures secrete equine chorionic gonadotropin (eCG), a glycoprotein hormone with a similar action to FSH, stimulating the growth of follicles, which can ovulate and luteinize, forming

accessory corpora lutea around 40 days of gestation. (Silva et al., 2012) CLa(s) increase the production of P4, which helps to maintain pregnancy up to about 150 days of gestation. From that moment on, the placenta fully assumes this function (Niswender et al., 2000; Thibault; Levasseur, 2001).

For the transfer of equine embryos, there is the surgical method, by incision in the flank, and the non-surgical method through the transcervical route, which is the most practical, fast and least invasive, since it is enough to deposit the embryo in the uterine body with the help of an artificial insemination pipette, using the covered technique, that is, coating the equipment with a plastic sheath to avoid contamination, which increases the pregnancy rate from 23% to 54% (Squires et al., 1999).

The main limiting factor related to the Embryo Transfer program is the acquisition and maintenance of recipient mares due to its high cost, in addition to the technique of the veterinarian who will perform the transfer (Hinrichs, 1987).

Embryo recipient mares are those who receive and generate the embryo, that is, they will have to recognize it and provide the necessary conditions for its development (Fleury et al., 2007). Therefore, the selection of recipients is decisive in the results of pregnancies, since they will have to create the product. The group of donors are those who donate the genetic material for the formation of the embryo and also demand attention, since the success of the ET program also depends on high rates of embryo retrieval.

The preparation of the embryo recipient mare begins when the donor mare shows signs of heat, and follicular growth and ovulation should be monitored, defining the best time for the insemination of this animal (Vanderwall et al., 2007). It is desirable that at least two or three recipients are available for each donor (McKinnon; Squires, 2007). Thus, at the time of ovulation, it will be possible to choose the one that presents the best reproductive conditions and the best progesteronic profile to receive the embryo.

Estrous synchronization of mares to ET assumes that ovulation of the recipient mare should occur on average one day before or up to three days after ovulation of the donor mare (Squires, 1999). In other words, the best pregnancy rates in recipients occur when the synchronization window is established between -3 (recipient ovulation occurs three days after the donor's) and +1 (recipient's ovulation occurs one day before the donor's) in relation to donors (Squires et al., 1985; McKinnon et al., 1988).

In cyclic mares, the synchronization procedure is simple, using a single intramuscular (IM) injection of prostaglandin F2-alpha in the donor mare, about one or two

days before the same application used in the recipients, when both are between the 6th and 14th days of diestrus and in the absence of a large pre-ovulatory follicle (Allen, 2001).

To increase the supply of recipient mares in ET programs, estrogen and/or progesterone (P4) treatments can be administered to non-cyclic recipient mares. Several studies have reported pregnancy rates after estrogen and/or progesterone injections (Hinrichs et al., 1986; Greco et al., 2013). According to Allen (2001), acyclic recipient mares are normally supplemented with exogenous P4 from the moment of embryo in ovulation until 120 days of gestation, when progestogen production is completely placental-dependent.

As it has been shown that estradiol (E2) increases the expression of uterine receptors for progesterone and that the equine embryo secretes estrogens during the early gestational phase (Zavy, et al. 1979), estrogen was administered before and together with P4 in ovariectomized mares and pregnancy rates ranging from 70 to 80% were obtained within the different hormonal protocols evaluated (McKinnon et al., 1988).

It has been suggested that, regardless of E2 injection, the main requirement for the establishment and maintenance of gestation in non-cyclic recipient mares is an adequate concentration of exogenous progesterone (McKinnon et al., 1988). In recent years, several doses of E2 have been administered to intact non-cyclic recipient mares and, after the observation of uterine edema, long-acting progesterone (LA P4) (Rocha Filho et al., 2004; Greco et al., 2012) or altrenogest (Silva et al., 2014; Silva et al., 2015) were administered three to eight days before embryo transfer.

Recently, it has been shown that the administration of a single dose of 2.5 mg of estradiol benzoate (BE) to mares in anestrus produces estrogen concentration similar to that found in cyclic mares (Silva et al., 2016). In addition, the plasma concentration of P4 after injection of 1500 mg of long-acting P4 (LA) at seven-day intervals is known to be compatible with the P4 concentrations found in cyclic mares during the luteal phase (> 4 ng/mL) (Bringel, et al., 2003).

The 2.5 mg dose of BE caused endometrial edema and estrogen concentrations consistent with those observed at the end of estrus in cyclic mares. In addition, administration of 1500 mg of LA of P4 increased uterine tone to characteristic levels of diestrus found in cyclic mares and acceptable P4 concentrations with those observed during the early luteal phase (Silva et al., 2017).

On the other hand, a good alternative in these cases is the use of receptors with an artificially induced cycle. Therefore, estrogen and P4 injections can be administered to mares in the transition period or even in the anestrus period to mimic the natural cycle (Squires 2008). Pregnancy rates in recipients receiving estrogen and P4 were similar to those of mares cycling naturally (Carnevale et al., 2000).

Caiado et al., (2007) found that daily treatment with P4 resulted in a pregnancy rate of almost 70.0% after ET. In a commercial ET program, Rocha Filho et al., (2004) prepared recipient mares for 2 days with BE and administered P4 on the third day. They found similar pregnancy rates between treated and control mares in a study with four different P4 treatments.

In addition, recipients of ovariectomized mares are able to establish and maintain pregnancy when treated with progesterone until the 100th day of gestation (Hinrichs et al., 1987). For these reasons, hormonal protocols using progestenes (Hinrichs et al., 1986; McKinnon et al., 1988; Shoemaker et al., 1989), progesterone (Hinrichs et al., 1987; Vanderwall et al., 2007), estradiol benzoate plus progestene (Wiepz et al., 1988) or progesterone (Kaercher et al., 2013) have been successfully used to maintain pregnancy in mares receiving anovulatory and ovariectomized embryos. Thus, hormone administration in anovulatory mares may make them suitable as embryo recipients, thus reducing the problems associated with donor/recipient estrus synchronization and allowing the use of more recipients at the end of the breeding season (Silva et al., 2014).

MATERIALS AND METHODS

In this study, 16 to 24 embryo recipient mares were used to check the corpus luteum (s) on D0, D15, D30, D60 and D90 of Haras Galopante (Imburi – São Francisco do Itabapuana – RJ), during the anestrus period and the breeding season. All recipients are part of the conventional procedures of the ET program of this stud farm, carried out during the breeding season and outside the breeding season. The mares used were of the Mangalarga Marchador breed with an average age of 7.5 years and with a good body score. These animals were kept in cost-cross grass grazing with mineral salt ad libitum.

An individual form was made of all mares, which contained information regarding their respective histories and findings in the general clinical and reproductive examination. Ultrasound evaluations of the reproductive tract of all recipient mares were performed using a US Pie Medical Falco 100 equipment, with a multiangular sectoral transducer of

5.0–7.5 Mhz. The first evaluation was performed to determine the most suitable recipient to be inseminated, the second to verify pregnancy (12 – 15 days of gestation) and the third in the period of formation of the accessory corpora luteum (40 – 60 days of gestation). The images obtained through these examinations were stored digitally for later evaluation of the ovarian structures, follicle(s) and corpus luteum(s).

The experimental design was based on the follow-up of the Embryo Transfer procedure, mainly with regard to the embryo recipient from the time of insemination and during her early gestational period until 90 days of gestation. The follow-up of the characteristics of the ovarian structures occurred at the time of insemination, in the early diagnosis of pregnancies at about 15 days, before (D30) and after the moment of formation of the accessory corpora luteum (D60) and at 90 days of gestation.

During the breeding season, the group monitored was that of cyclic mares synchronized with PGF2 α . Cyclic mares were those that have follicular growth with ovulation and CL formation. The acyclic mares were followed up in the winter months, thus considering those that had follicles with a diameter of less than 20 mm and absence of CL (mares in anestrus, in the months of June, July and August) and those that presented follicles between 15 and 25 mm and absence of CL (mares in transition, April, May).

In the protocols for synchronizing the acyclic recipients with the donors, three doses of Estradiol Benzoate with 5, 3 and 2 mg, respectively, were used on consecutive days, on the first day (D1) or second day (D2) after the donor's ovulation. On the third day (D3), IM application of long-acting P4 of 150 mg was performed, when level 3 uterine edema was detected, according to the classification of Canesin (2013). In the protocols of synchronization of the cyclic recipients with the donors, among a group of recipient mares, the application of a dose of prostaglandin to the one with corpus luteum was used one to two days before the application of the luteolytic to the embryo donor.

To induce ovulation in donor mares, a single dose of 1 ml (250 μ g) of Strelin (synthetic analogue of GnRH - Gonadotropin-releasing hormone) was applied intramuscularly to mares with ovarian follicles with diameters equal to or greater than 35mm in diameter and degree of uterine edema above 2 to 3. Insemination occurred following several protocols, fresh semen (diluted, refrigerated), native semen and frozen semen.

The interval to proceed with inoovulation was when the presence of a corpus luteum was found in the recipient from 4 days and a maximum of 9 days after ovulation, being ideal from 5 days after ovulation.

Embryo collection was performed between the 7th and 9th day after the donor's ovulation, preferably on the 8th day. This procedure was done using the uterine lavage method. This procedure was repeated three times in each collection.

The diagnosis of early pregnancy occurred in the period of 12 to 15 days of gestation or 4 to 6 days after the innoavulation of the recipients to verify pregnancies and structures present in the ovaries. And in the period from 50 to 60 days, the maintenance of pregnancies and structures present in the ovaries was found in this period, ending the examination at 90 days of gestation. All data on the structures present in the ovaries (follicles and corpora lutea) of the control group (cyclic mares) and the experimental group (acyclic mares) were analyzed to verify the presence and/or absence of follicles and corpora lutea, determining the size of the diameter, area and echotexture by ultrasonography.

Metric and texture analyses of the data obtained for the various evaluated characteristics of the ovarian structures (follicle(s) and corpus luteum(s)) were carried out, using chi-square (2χ), considering a level of 5% probability ($p < 0.05$), in order to verify the independence between the observed data and the various treatments to which the mares were submitted.

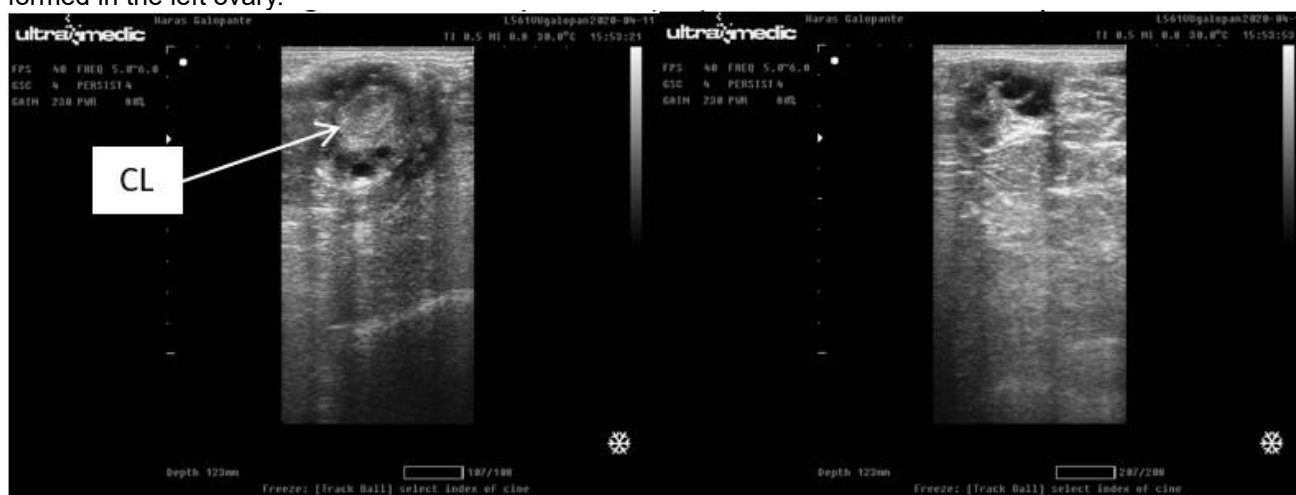The graphic formatting of the ultrasound images was performed for the treatment of images, by tonality frequency, when an objective software (Pixel Analyser 6.6) was used to evaluate these images (analysis of the pixel staining density). The statistical analysis used the SAEG 9.1 application to obtain descriptive statistics parameters; Standard error (represents how close the sample mean is to the population mean); confidence interval ($P=0.95$) (Pimentel; Gomes, 1966) in relation to the tonality of the pixels.

RESULTS AND DISCUSSION

The sonographic images of the right and left ovaries of each cyclic recipient mare (control group) recorded to evaluate the presence of corpora luteum at the time of inoovulation (D0) and in the different gestational periods, at 30, 60 and 90 days, are demonstrated in some examples below, since the "n" of the samples is very high.

In the D0 period, i.e., the day of ovulation, a total of 20 ultrasound images of the right and left ovaries were performed in the control group to evaluate the corpora luteum of each recipient mare (Figure 1).

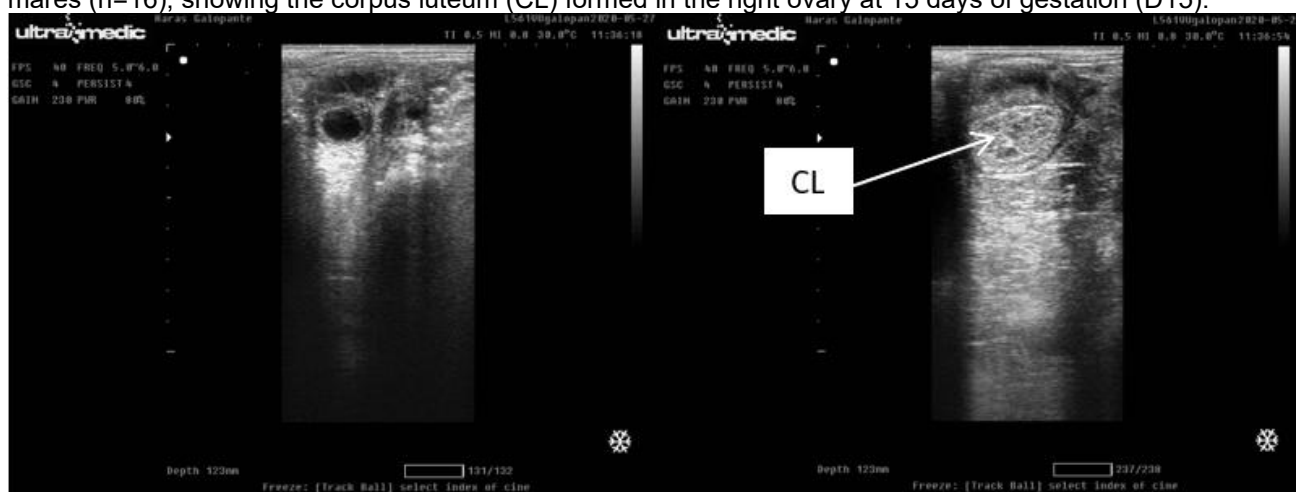Figure 1: Representative images of the right and left ovaries, respectively, of conventional cyclic recipient mares (n=20) on the day of ovulation (D0), showing the hemorrhagic body, future corpus luteum (CL) formed in the left ovary.



Source: Prepared by the authors.

At 15 days after embryo transfer, pregnancy was confirmed by ultrasonography and a total of 16 ultrasound images of the ovaries were recorded, such as those recorded in Figure 2.

Figure 2: Representative images of the right and left ovaries, respectively, of conventional cyclic recipient mares (n=16), showing the corpus luteum (CL) formed in the right ovary at 15 days of gestation (D15).

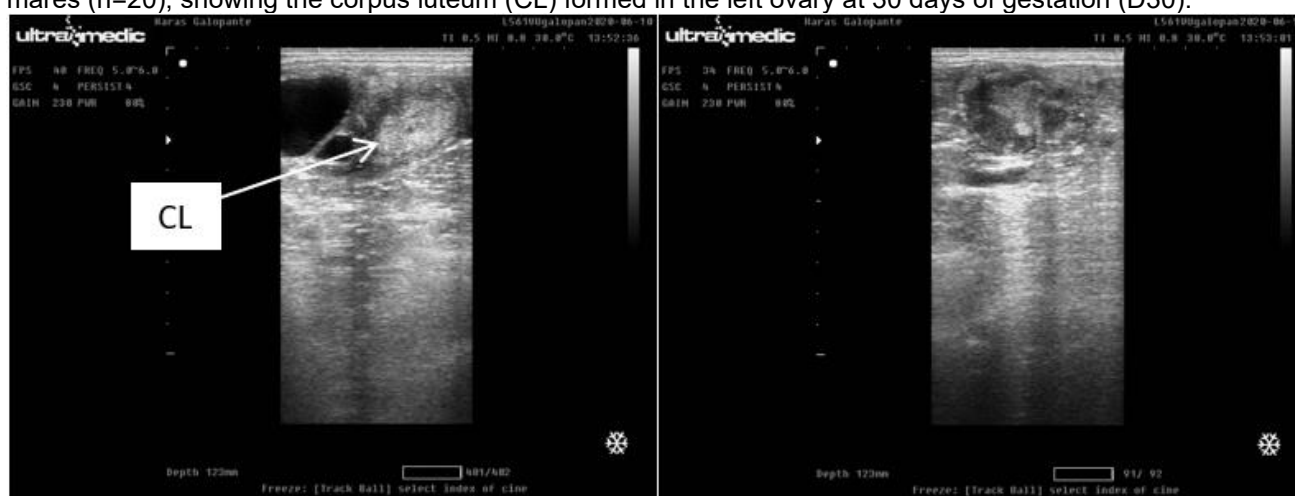


Source: Prepared by the authors.

At 30, 60 and 90 days of gestation, images of the right and left ovaries and their corpora luteum were taken during gestational follow-up, as exemplified in figures 3, 4 and 5 below, respectively.

At D30, a total of 20 images were recorded, where Figure 3 shows as a representative image of the right and left ovaries, respectively, of conventional cyclic recipient mares at 30 days of gestation (D30).

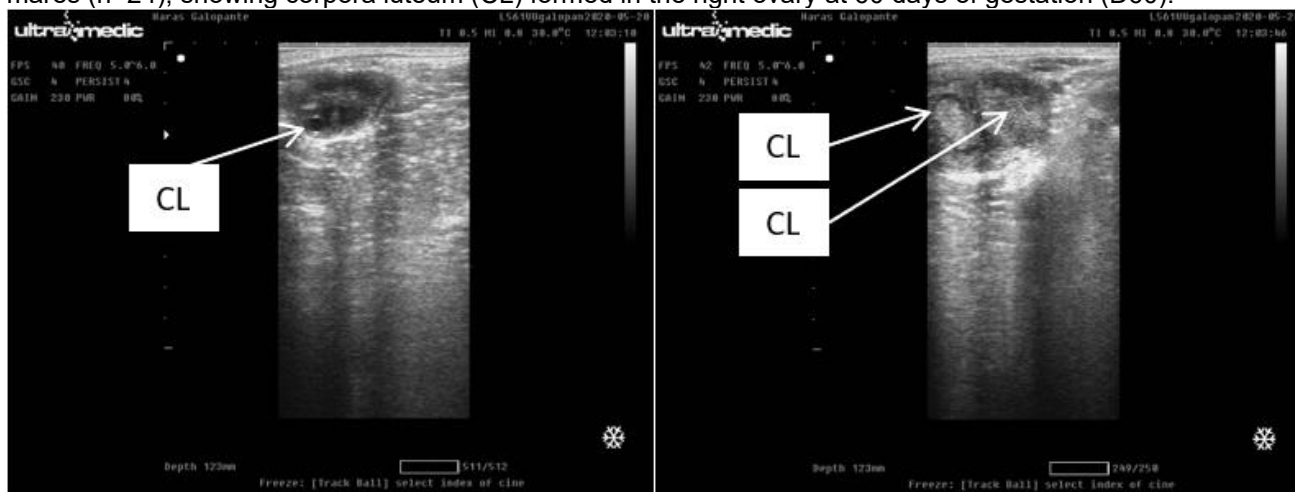Figure 3: Representative images of the right and left ovaries, respectively, of conventional cyclic recipient mares (n=20), showing the corpus luteum (CL) formed in the left ovary at 30 days of gestation (D30).



Source: Prepared by the authors.

On D60, a total of 24 images were recorded, and Figure 4 shows a representative image of the right and left ovaries, respectively, of conventional cyclic recipient mares at 60 days of gestation (D60).

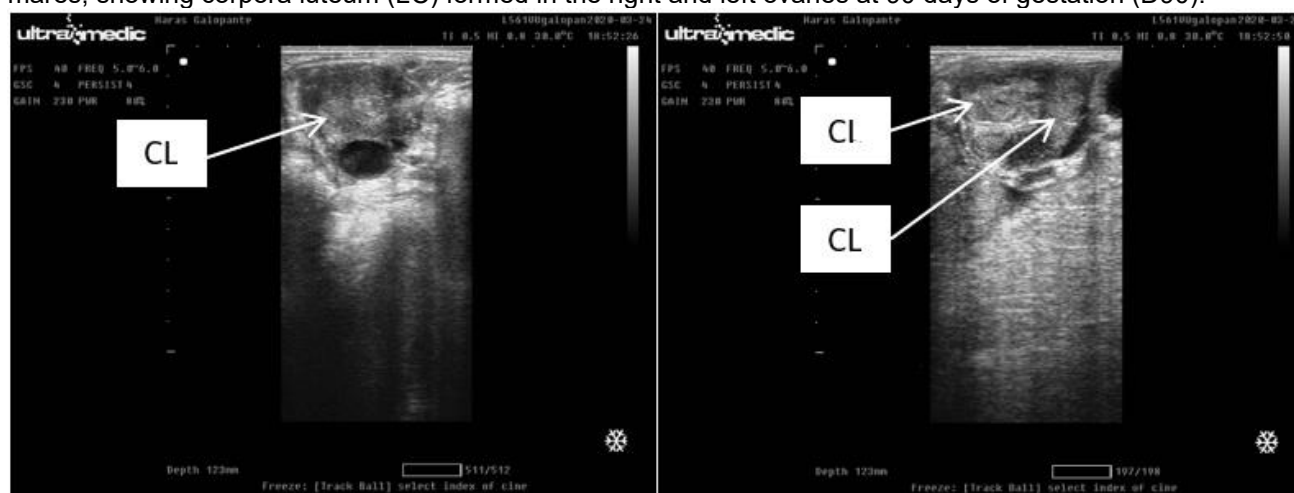Figure 4: Representative images of the right and left ovaries, respectively, of conventional cyclic recipient mares (n=24), showing corpora luteum (CL) formed in the right ovary at 60 days of gestation (D60).



Source: Prepared by the authors.

On D90, a total of 16 images were recorded, where Figure 5 shows as a representative image of the right and left ovaries, respectively, of conventional cyclic recipient mares at 90 days of gestation (D90).

Figure 5: Representative images of the right and left ovaries, respectively, of conventional cyclic recipient mares, showing corpora luteum (LC) formed in the right and left ovaries at 90 days of gestation (D90).

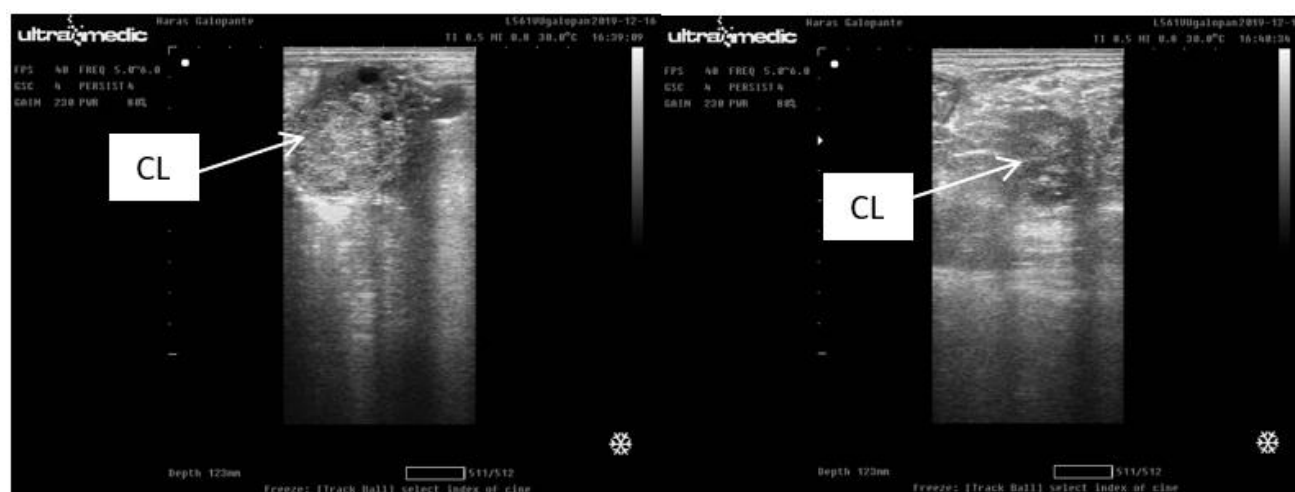

Source: Prepared by the authors.

Ultrasound images of the right and left ovaries of each acyclic recipient mare supplemented with exogenous progesterone (experimental group) were recorded to evaluate the presence of accessory corpora luteum at 60 and 90 days of gestation. Some examples are shown below, since the "n" of the samples is high.

A total of 16 images were recorded on D60, and Figure 6 shows the representative image of the right and left ovaries, respectively, of acyclic recipient mares supplemented with exogenous P4 at 60 days of gestation.

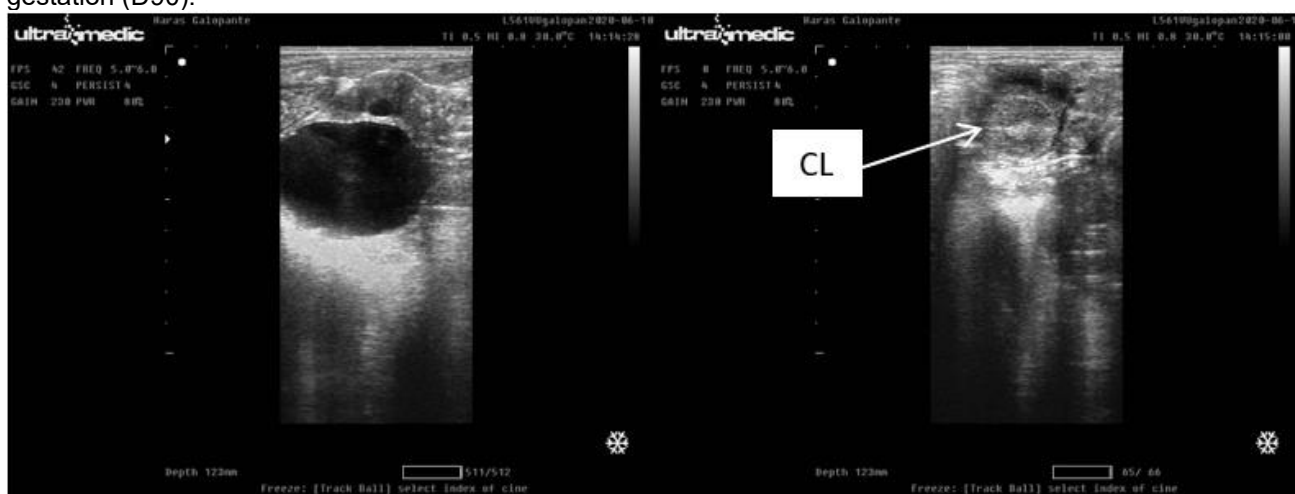Figure 6: Representative images of the right and left ovaries, respectively, of acyclic recipient mares supplemented with exogenous P4 (n=16), showing corpus luteum (CL) formed in the left ovary at 60 days of gestation (D60).



Source: Prepared by the authors

On D90, a total of 22 images were recorded, showing Figure 7 a representative image of the right and left ovaries, respectively, of acyclic recipient mares supplemented with exogenous P4 at 90 days of gestation.

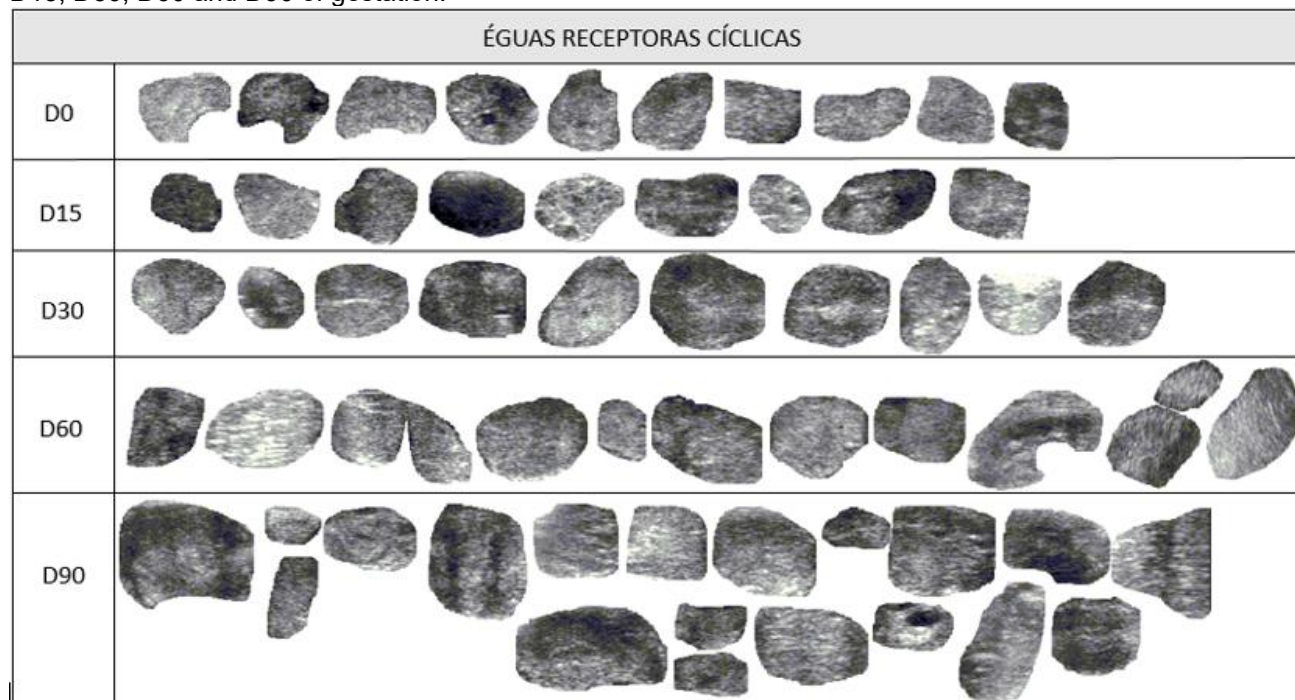
Figure 7: Representative images of the right and left ovaries, respectively, of acyclic recipient mares supplemented with exogenous P4 (n=22), showing corpus luteum (CL) formed in the right ovary at 90 days of gestation (D90).



Source: Prepared by the authors.

Figures 8 and 9 show the cutouts of the corpus luteum regions, made in the original sonographic images recorded of the left and right ovaries of each of the cyclic recipient mares on D0, D15, D30, D60 and D90, with D0 being the moment of ovulation and D90 the last follow-up performed at 90 days, and of the acyclic recipient mares treated hormonally on days D60 and D90. It is worth mentioning that no cutouts were made in the previous periods in the experimental group because these mares do not have primary corpus luteum and only after about 40 days the formation of accessory corpora lutea occurs, which were evaluated in this work.

Figure 8: Ultrasound images delimited for the analysis of corpora lutea of cyclic recipient mares on days D0, D15, D30, D60 and D90 of gestation.



Source: Prepared by the authors

In the cyclic recipient mares, 10 clippings were made on D0, nine clippings on D15 (due to embryonic loss), 10 clippings on D30, 13 clippings on D60 and 16 clippings on D90. This increasing difference in the number of structures cut is expected due to the appearance of accessory corpora lutea in the 60- and 90-day groups, and the appropriate statistical corrections were made for the difference between the sample of the periods.

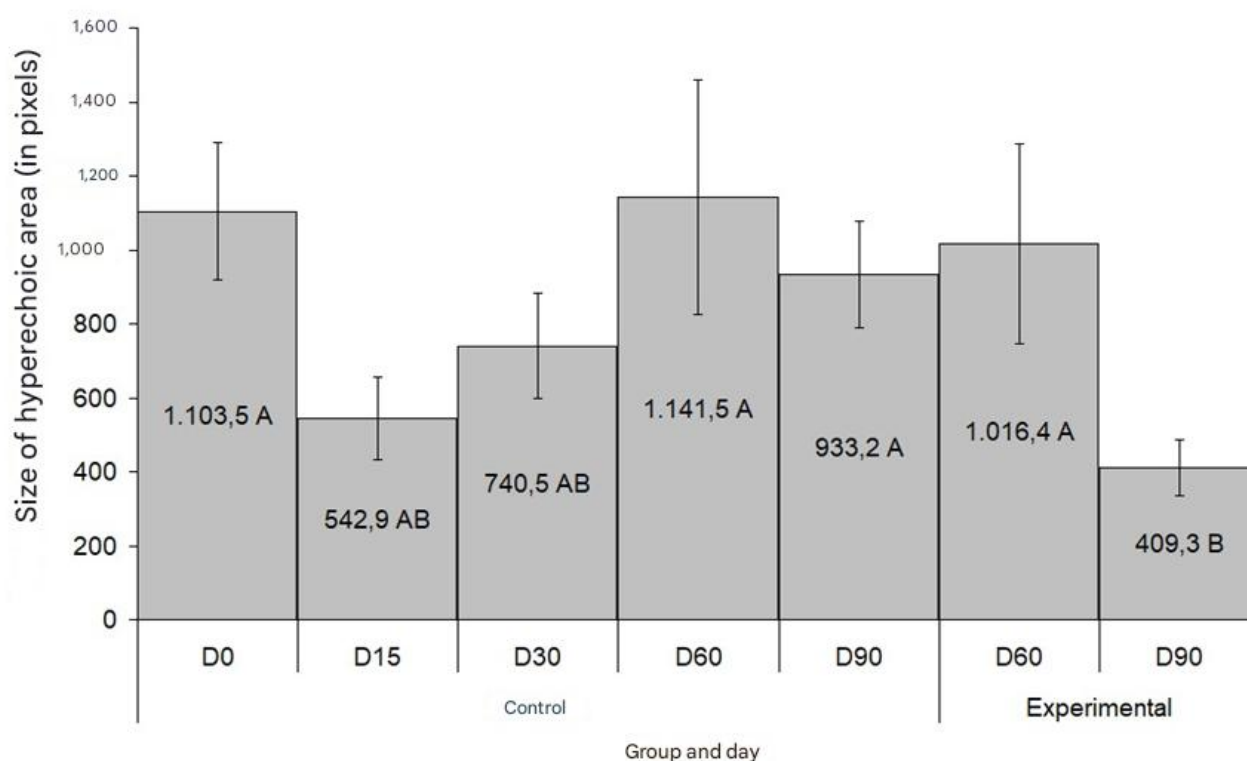
Figure 9: Ultrasound images delimited for the analysis of corpora luteum of acyclic recipient mares supplemented with exogenous P4 at 60 (D60) and 90 (D90) days of gestation.



Source: Prepared by the authors.

Acyclic recipient mares supplemented with exogenous P4 were made with 12 clippings on D60 and 15 clippings on D90. Statistical corrections were also made for the difference between the sample of the periods in this group. Figure 10 shows the statistical results of the analysis of the corpora lutea of the control and experimental groups, regarding the size of the hyperechogenic area, in pixels, in each of the periods evaluated between the group of cyclic receptor mares (control) and the experimental group of acyclic recipient mares treated hormonally, considering $P < 0.05$.

Figure 10: Comparative evaluation of the statistical means of the size of the hyperechogenic area, in pixels, in each of the periods evaluated between the group of cyclic receptor mares (control) and the experimental group of hormonally treated acyclic receptor mares, considering $P < 0.05$.



Source: Prepared by the authors.

The fact that on D0 the hyperechogenic area tends to be larger than on D15 corroborates the findings of Pierson and Ginther (1985), who found that in the period of diestrus the echogenicity of the corpus luteum can be used to help estimate the age of both the corpus luteum solidum and the corpus luteum with central hemorrhage. During the first days after ovulation, echogenicity is high, decreasing until D8 and from then on it begins to increase at the time of regression of the corpus luteum in the last days of diestrus. Complementing the data of Pierson and Ginther, who did not continue the study beyond

D15, the present study verified the continuity of the increase in the echogenic area on D30 until D60. As Ginther (1986) described, on the day of ovulation the centrally non-echogenic gland becomes echogenic in 75 to 100 percent of its image, and in most mares before the CL cavity appears, the gland shows a high initial proportion of echogenic tissue that apparently represents the collapsed luteinized walls of the newly ovulated follicle.

In addition, it is known that the fibrinous tissue is more hyperechoic in relation to the tissues of the parenchyma of the organs, so one can think about the hypothesis of the later verification of ovulations, where it is expected to find a larger area of fibrinous tissues, such as fibrinous cords where granulosa and theca cells begin to proliferate and luteinize over time, and the fibrinous tissue starts to give way to this new type of cell. Continuing the analysis, in D15, according to Ginther (1986), there is probably a decrease in the proportion of fibrous tissue and the granulosa and theca cells are still in the process of densification and progressive luteinization, so that the aspect is still less hyperechoic than in D30.

In D30, with the advance of luteinization and densification of this tissue, it becomes more hyperechoic and in D60, cell proliferation and luteinization reach their apex.

In D90 of the control group, as well as the experimental group, a trend of decrease in hyperechogenic tissue is observed, which corroborates the progressive loss of the importance of this organ for the maintenance of pregnancy due to its replacement by the production of progestins by the placenta.

In the experimental group, the same trend is observed, since the follicles of pregnant mares from D40 onwards begin to produce accessory corpora lutea, becoming hemorrhagic and later luteinizing due to the proliferation of granulosa and theca cells over this fibrous area. Thus, this structure has a larger hyperechogenic area than in the same group on D90, where a retraction of this structure is already observed, which is physiologically explained by its loss of function in maintaining pregnancy, noting that those of the corpora luteum progressively lose their importance, since the placenta begins to replace them from D70 onwards. As stated by Silva et al., (2013), that the placenta becomes progressively responsible for the maintenance of pregnancy and that, in addition, the researchers state that the interruption of progesterone treatment on day 70 of pregnancy in non-cyclic pregnant recipient mares contributes to the understanding of the physiology of equine pregnancy, suggesting that the interruption of progesterone treatment

in non-cyclic recipient mares at 70 days of gestation maintains the gestation when present accessory corpus luteum in the ovary of these acyclic receptors.

The statistically assured difference in D90 between the control and experimental groups was fundamental for us to reach the conclusion of this research work. It is not possible to observe, comparing the means between the control and experimental treatments, on D60, a statistically significant variation in the size of the hyperechogenic area of the corpora lutea, since the means followed by the same letter do not differ significantly from each other, at the level of 5% of probability, and both values are followed by the letter "A". At 60 days, the hyperechogenic area of the corpora lutea of the control group was equal to 1,141.5 pixels. At 60 days, this area corresponded to 1,016.4 pixels in the experimental group.

At 90 days, it can be observed that the hyperechogenic area of the corpora lutea of the control group, which was equal to 933.2 pixels, corresponds to more than twice the area of the experimental group, which corresponded to 409.3 pixels. In addition, this data was statistically assured, verifying that the values of the means were followed by different letters. This finding suggests that the accessory corpora luteum of acyclic recipient mares involute faster in the time lapse from D60 to D90 of gestation than the corpora luteum of cyclic recipient mares. This event of faster regression of the corpora lutea between the groups analyzed in the time interval from D60 to D90 suggests that caution should be exercised in interrupting the application of exogenous progesterone in acyclic recipient mares from D70 onwards.

Funding source: **CNPq**

REFERENCES

1. Allen, W. R., & Rowson, L. E. A. (1975). Surgical and non-surgical egg transfer in horses. *Journal of Reproduction and Fertility*, 23, 525–530. <https://pubmed.ncbi.nlm.nih.gov/1060836/>
2. Aurich, C. (2011). Reproductive cycles of horses. *Animal Reproduction Science*, 124(3–4), 220–228. <https://doi.org/10.1016/j.anireprosci.2011.02.006>
3. Bringel, B. A., Jacob, J. C. F., Zimmerman, M., Alvarenga, M. A., & Douglas, R. H. (2003). Biorelease progesterone LA 150 and its application to overcome effects of premature luteolysis on progesterone levels in mares. *Revista Brasileira de Reprodução Animal*, 27(3), 498–500. https://www.researchgate.net/publication/281509029_Biorelease_progesterone_LA_150_and_its_application_to_overcome_effects_of_premature_luteolysis_on_progesterone_levels_in_mares
4. Caiado, J. T. C., Fonseca, F. A., Silva, J. F. S., & Fontes, R. S. (2007). Hormonal treatment of recipient mares of the Mangalarga Marchador breed for embryo transfer on the second day post ovulation. *Revista Brasileira de Zootecnia*, 36(1), 99–103. <https://doi.org/10.1590/S1516-35982007000100012>
5. Canesin, H. S. (2013). Caracterização da hemodinâmica uterina de éguas durante o ciclo estral [Dissertação de mestrado, Universidade Estadual Paulista]. Repositório UNESP. <https://repositorio.unesp.br/server/api/core/bitstreams/3f2ec904-3624-473e-879e-adb7219b1fa5/content>
6. Carnevale, E. M., Ramirez, R. J., Squires, E. L., Alvarenga, M. A., & McCue, P. M. (2000). Factors affecting pregnancy rates and early embryonic death after equine embryo transfer. *Theriogenology*, 54(6), 965–979. [https://doi.org/10.1016/S0093-691X\(00\)00405-2](https://doi.org/10.1016/S0093-691X(00)00405-2)
7. Gonsalves, P. B. D., Figueiredo, J. R., & Freitas, V. J. F. (2002). Biotécnicas aplicadas à reprodução animal. Varela.
8. Greco, G. M., Burlamaqui, F. L. G., Pinna, A. E., Queiroz, F. J. R., Cunha, M. P. S., & Brandao, F. Z. (2012). Use of long-acting progesterone to acyclic embryo recipient mares. *Revista Brasileira de Zootecnia*, 41(3), 607–611. <https://doi.org/10.1590/S1516-35982012000300021>
9. Hartman, D. L. (2011). Embryo transfer. In A. O. McKinnon, E. L. Squires, W. E. Vaala, & D. D. Varner (Eds.), *Equine reproduction* (2nd ed., pp. 2871–2879). Wiley-Blackwell. https://books.google.com.br/books/about/Equine_Reproduction.html?id=QPJQT6-g-YMC
10. Hinrichs, K., Sertich, P. L., & Kenney, R. M. (1986). Use of altrenogest to prepare ovariectomized mares as embryo transfer recipients. *Theriogenology*, 26(4), 455–460. [https://doi.org/10.1016/0093-691X\(86\)90038-2](https://doi.org/10.1016/0093-691X(86)90038-2)

11. Hinrichs, K., Sertich, P. L., Palmer, E., & Kenney, R. M. (1987). Establishment and maintenance of pregnancy after embryo transfer in ovariectomized mares treated with progesterone. *Journal of Reproduction and Fertility*, 80(2), 395–401. <https://doi.org/10.1530/jrf.0.0800395>
12. Instituto Brasileiro de Geografia e Estatística. (2020). Produção da pecuária municipal: Equinos. EquiAgro Consultoria. <https://www.ibge.gov.br/explica/producao-agropecuaria/equinos/br>
13. Kaercher, F., Kozicki, L. E., Camargo, C. E., Weiss, R. R., Santos, I. W., Muradas, P. R., & Bertol, M. A. F. (2013). Embryo transfer in anovulatory recipient mares treated with estradiol benzoate and long-acting progesterone. *Journal of Equine Veterinary Science*, 33(3), 205–209. <https://doi.org/10.1016/j.jevs.2012.06.009>
14. Lira, R. A., Peixoto, G. C. X., & Silva, A. R. (2009). Transferência de embrião em equinos: Revisão. *Acta Veterinária Brasilica*, 3(4), 132–140. https://www.researchgate.net/publication/277150533_TRANSFERENCIA_DE_EMBRIO_EM_EQUINOS_REVISAO
15. McKinnon, A. O., & Squires, E. L. (1988). Morphologic assessment of equine embryo. *Journal of the American Veterinary Medical Association*, 192(3), 401–406. <https://avmajournals.avma.org/view/journals/javma/192/3/javma.1988.192.03.401.xml>
16. McKinnon, A. O., Squires, E. L., Carnevale, E. M., & Hermenet, M. J. (1988). Ovariectomized steroid-treated mares as embryo transfer recipients and as a model to study the role of progestins in pregnancy maintenance. *Theriogenology*, 29(5), 1055–1063. [https://doi.org/10.1016/0093-691X\(88\)80029-3](https://doi.org/10.1016/0093-691X(88)80029-3)
17. Ministério da Agricultura, Pecuária e Abastecimento. (2016). Relatório anual. <https://www.gov.br/agricultura/pt-br/>
18. Pimentel, G. F. (1966). Curso de estatística experimental (3rd ed.). Escola Superior de Agricultura “Luiz de Queiroz”, USP.
19. Rocha Filho, N. A., Pessôa, M. A., Gioso, M. M., & Alvarenga, M. A. (2004). Transfer of equine embryos into anovulatory recipients supplemented with short or long acting progesterone. *Animal Reproduction*, 1(1), 91–95. <https://www.animal-reproduction.org/article/5b5a608bf7783717068b4810>
20. Shoemaker, C. F., Squires, E. L., & Shideler, R. K. (1989). Safety of altrenogest in pregnant mares and on health development of offspring. *Journal of Equine Veterinary Science*, 9(2), 69–72. [https://doi.org/10.1016/S0737-0806\(89\)80030-9](https://doi.org/10.1016/S0737-0806(89)80030-9)
21. Silva, E. S. M., Ignacio, F. S., Pantoja, J. C. F., Puoli Filho, J. N. P., & Meira, C. (2014). Supplementary corpora lutea monitoring allows progestin treatment interruption on day 70 of pregnancy in non-cyclic recipient mares. *Animal Reproduction Science*, 144(3–4), 122–128. <https://doi.org/10.1016/j.anireprosci.2013.12.004>

22. Silva, E. S. M., Pantoja, J. C. F., Puoli Filho, J. N. P., & Meira, C. (2015). Ultrasonography of the conceptus development from days 15 to 60 of pregnancy in non-cyclic recipient mares. *Ciência Rural*, 45(3), 512–518. <https://doi.org/10.1590/0103-8478cr20140617>
23. Silva, E. S. M., Puoli Filho, J. N. P., Meira, C., & cols. (2012). Aspectos relacionados à formação, função e regressão dos corpos lúteos suplementares em éguas. *Veterinária e Zootecnia*, 19(3), 283–293. <https://repositorio.unesp.br/server/api/core/bitstreams/083c898a-ecd0-461b-a7b1-fd445dfbe473/content>
24. Silva, E. S. M., Roser, J. F., Gomes, A. R. C., Fritsch, S. C., Pantoja, J. C. F., Oliveira-Filho, J. P., & cols. (2016). Comparison of different regimens of estradiol benzoate treatments followed by long-acting progesterone to prepare noncycling mares as embryo recipients. *Theriogenology*, 86(7), 1749–1756. <https://doi.org/10.1016/j.theriogenology.2016.05.041>
25. Silva, E. S. M., Silva, F. S., Ignacio, S. C., Fritsch, D. S., Zanoni, J. C. F., Pantoja, J. P., Oliveira-Filho, C., & Meira, C. (2017). Administration of 2.5 mg of estradiol followed by 1,500 mg of progesterone to anovulatory mares promote similar uterine morphology, hormone concentrations and molecular dynamics to those observed in cyclic mares. *Theriogenology*, 97, 159–169. <https://doi.org/10.1016/j.theriogenology.2017.04.031>
26. Squires, E. L. (2008). Hormonal manipulation of the mare: A review. *Journal of Equine Veterinary Science*, 28(11), 627–634. <https://doi.org/10.1016/j.jevs.2008.10.001>
27. Vanderwall, D. K., Marquardt, J. L., & Woods, G. L. (2007). Use of compounded long-acting progesterone formulation for equine pregnancy maintenance. *Journal of Equine Veterinary Science*, 27(2), 62–66. <https://doi.org/10.1016/j.jevs.2006.12.004>
28. Wiepz, G. J., Squires, E. L., & Chapman, P. L. (1988). Effects of norgestomet, altrenogest, and/or estradiol on follicular and hormonal characteristics of late transitional mares. *Theriogenology*, 30(1), 182–193. [https://doi.org/10.1016/0093-691X\(88\)90276-0](https://doi.org/10.1016/0093-691X(88)90276-0)
29. Zavy, M. T., Mayer, R., Vernon, M. W., Bazer, F. W., & Sharp, D. C. (1979). An investigation of the uterine-luminal environment of nonpregnant and pregnant pony mares. *Journal of Reproduction and Fertility Supplement*, 27, 403–411. <https://pubmed.ncbi.nlm.nih.gov/289817/>