


## PRERATION OF THE LOWER MOLAR CANAL WITH ROTARY FILES IN A SINGLE SESSION – CASE REPORT

 <https://doi.org/10.56238/arev7n4-139>

Submitted on: 14/03/2025

Publication date: 14/04/2025

**Rosana Maria Coelho Travassos<sup>1</sup>, Gustavo Moreira de Almeida<sup>2</sup>, Vanessa Lessa Cavalcanti de Araújo<sup>3</sup>, Emmanuel Brito Carvalho de Sá<sup>4</sup>, Josué Alves<sup>5</sup>, Alexandre Batista Lopes do Nascimento<sup>6</sup>, Izabella Christina Xavier Lins<sup>7</sup>, Pedro Guimarães Sampaio Trajano dos Santos<sup>8</sup>, Verônica Maria de Sá Rodrigues<sup>9</sup>, Priscila Prosini<sup>10</sup>, Kattyenne Kabbaz Asfora<sup>11</sup>, Ronaldo de Carvalho Raimundo<sup>12</sup>, Vânia Cavalcanti Ribeiro da Silva<sup>13</sup>.**

### ABSTRACT

A 49-year-old male patient with no history of systemic diseases sought a private practice, complaining of spontaneous pain in tooth 36. The X-ray showed deep caries with possible pulp exposure. After anesthesia, the tooth was isolated and the coronary access was obtained. Irrigation was performed with 2% chlorhexidine gel. After establishing the actual working length, the Solla Collors 50.04 instrument was moved in and out along the entire

<sup>1</sup> PhD in Dentistry and Endodontics

University of Pernambuco, Brazil

Email: rosana.travassos@upe.br

<sup>2</sup> Doctorate in Endodontics

Research and Teaching Institute College

Email: drgustavoalmeida01@gmail.com

<sup>3</sup> PhD (FORP-USP)

Faculty: University of Pernambuco

Email: vanessa.lessa@upe.br

<sup>4</sup> Specialist in endodontics

Federal University of Pernambuco

Email : emmanuel.de.sa@hotmail.com

<sup>5</sup> PhD in Oral Rehabilitation - FOB- USP.

Faculty of Dentistry of Pernambuco

<sup>6</sup> PhD in Dentistry and Endodontics

Faculty of Dentistry of Pernambuco

<sup>7</sup> PhD (UFPE)

Faculty: UPE

Email: bellalinns2@gmail.com

<sup>8</sup> Undergraduate student in dentistry

Faculty of Dentistry of Recife

<sup>9</sup> PhD in Dentistry and Endodontics

Faculty of Dentistry of Pernambuco

<sup>10</sup> PhD in Dentistry

University of Pernambuco

<sup>11</sup> PhD in Dentistry and Endodontics

Faculty of Dentistry of Pernambuco

<sup>12</sup> PhD in Oral and Maxillofacial Surgery and Traumatology

Faculty of Dentistry of Pernambuco

<sup>13</sup> PhD in Dentistry

Faculty: University of Pernambuco

Email: Vânia.silva@upe.br

length of the root canal until the established working length was reached. The foraminal patency, exceeding the apical foramen outlet by 1 mm, was performed with the Solla Collors Glide path file 16/02. Filling was performed using the single-cone technique associated with Bio-C Sealer cement. It is concluded that the preparation with Solla Collors files determines an adequate formatting and modeling of root canals of the lower molar.

**Keywords:** Endodontics. Lower molar. Solla Collors. Endodontic filling. Root canals.

## INTRODUCTION

Endodontics is a specialty of extreme importance for dentistry and is composed of several steps, including the instrumentation phase of root canals. The mechanical chemical preparation has the functions of cleaning, disinfecting and modeling the root canal, so that it can receive the filling material. The search to improve the quality of root canal treatments led to a transition from manual to automated instrumentation. However, before choosing the system they will use, the dental surgeon must know the capabilities and limitations of each system. (Corrêa, 2015).

The success of endodontic treatment depends on many challenges. The anatomical complexity of root canals is a limiting condition in instrumentation, and imposes on the operator the need to perform different maneuvers to achieve it. In view of this situation, the development of mechanized systems that use nickel-titanium instruments with rotational and/or reciprocating movements provides greater safety to the preparation of the root canal, has presented several advantages, such as the increase of the irrigating solution at the apical level, greater elimination of debris and tissue, reduction of non-instrumented areas of the root canal, reduction of microorganisms, thus enabling a better filling (Tenuta, 2024).

The instrumentation stage in endodontic treatment must comply with some principles so that it is well executed. To this end, endodontic instruments have evolved a lot in recent years, with the intention of making treatments safer, more precise and more efficient. Alternatives have emerged in an attempt to improve the mechanical properties of conventional Nickel-Titanium (NiTi) endodontic files, such as thermomechanical treatments and different metal alloys in order to improve fracture resistance. (Belala, 2021).

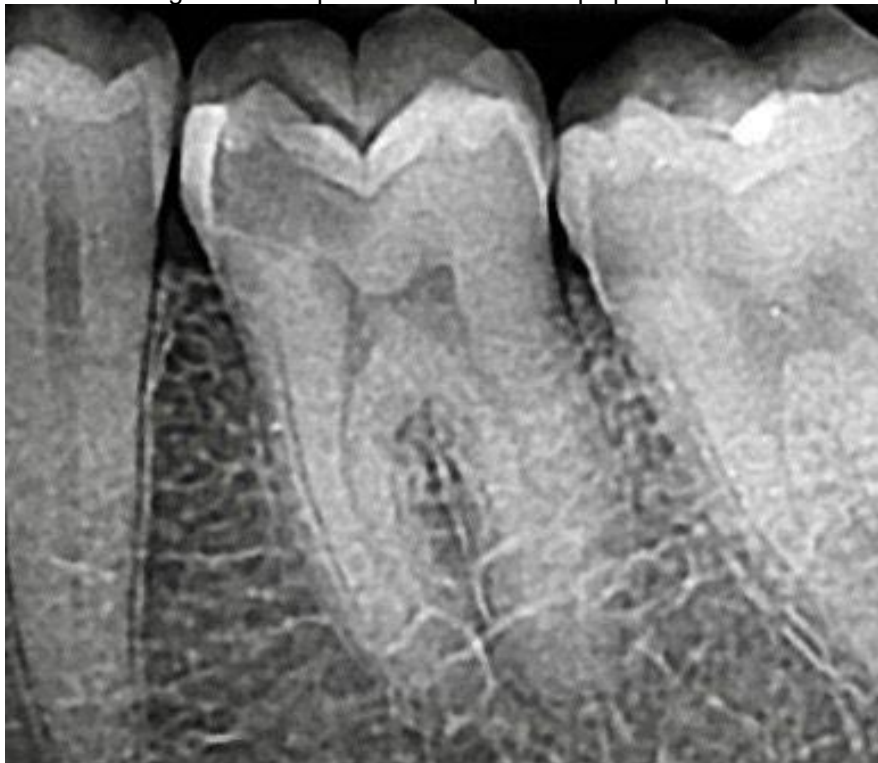The objective of this study was to describe the preparation of the root canal in the mandibular molar, with rotational instrumentation, using Solla Collors files and filling of the root canal system by the single cone technique.

## CASE REPORT

A 49-year-old male patient with no history of systemic diseases sought a private practice, complaining of spontaneous pain in tooth 36. Regarding the ethical terms, the patient signed the Informed Consent Form and the ethical principles described in the Declaration of Helsinki were respected. Clinically, caries was observed. The tooth responded positively to the pulp sensitivity test to cold performed with Endo-Frost

refrigerant gas (Roeko-Wilcos, Rio de Janeiro, RJ, Brazil). The X-ray showed deep caries with possible pulp exposure and atretic canals. (Figure 1).

Figure 1 - Deep caries with possible pulp exposure

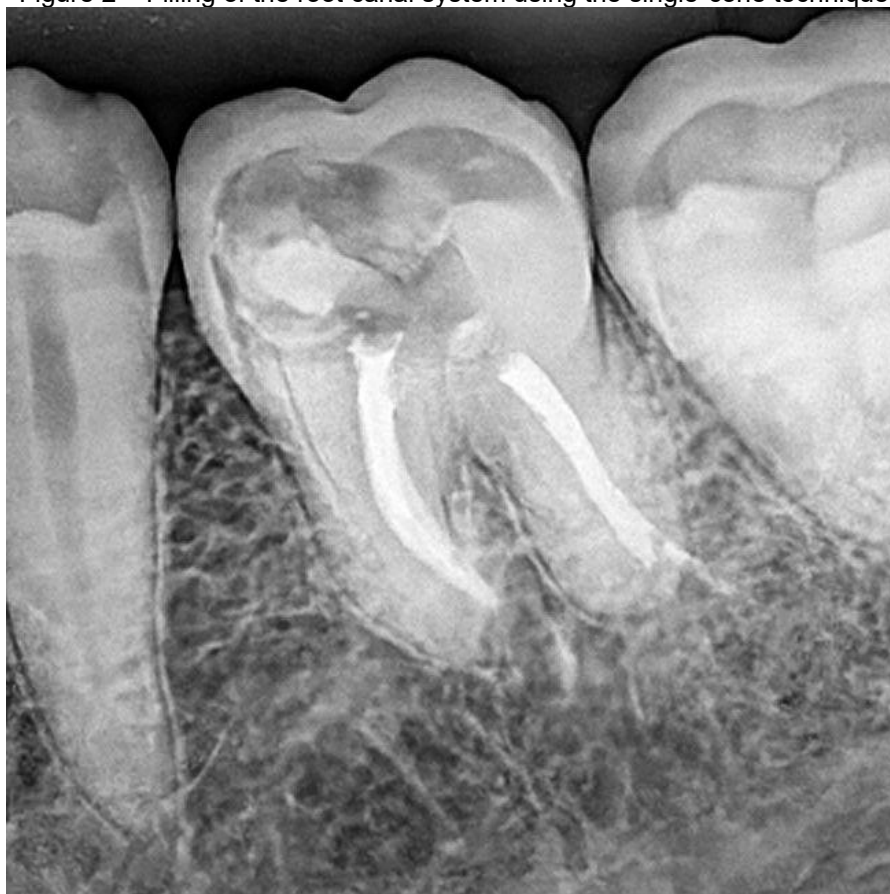

After anesthesia, the tooth was isolated and coronary access was performed using a 1014 diamond drill (KG Sorensen, Cotia, SP, Brazil). Irrigation was performed with 2% chlorhexidine. After exploration of the root canal, radiographic odontometry was performed.

After establishing the actual working length, the Solla Collrs 50.04 instrument was moved in and out along the entire length of the root canal until the established working length was reached. The foraminal patency, exceeding the apical foramen outlet by 1 mm, was performed with the Solla Collors Glide path file 16/02. The irrigating solution used was 2% chlorhexidine gel and saline solution.

The filling was performed using the single cone technique associated with Bio-C Sealer (Angelus) cement. The restoration was performed with Filtek Z250 XT microhybrid composite resin (3M, Two Harbors, Minnesota, USA). (Figure 2). The restoration was performed with Filtek Z250 XT microhybrid composite resin (3M, Two Harbors, Minnesota, USA).

Figure 2 – Filling of the root canal system using the single-cone technique



## DISCUSSION

Solla Collors rotary files have the ideal flexibility of the instrument to preserve the cutting characteristics of the instruments well, thus being ideal for most cases. Heat treatment with memory control with nanoparticle deposition increases resistance to torsion and cyclic fatigue, thus making this instrument ideal for everyday clinical use. Learning is very simple for its use, resulting in considerable savings in time and money since these files are the cheapest on the market being developed by Professor Samuel Nogueira Lima with this purpose, to be ideal for health plans, health insurance and popular clinics, logically, that those who attend private have the gain of using the instrument once and discarding it if they want. (Travassos et al. 2024).

The use of quality technologies and materials in endodontics helps in the quality, effectiveness and precision of endodontic treatment. The success of the treatment depends on the complete elimination of microorganisms responsible for the development of pulp pathologies. The in-depth knowledge of the anatomy of the root canal and materials of excellence collaborate for a more effective and safe treatment. (Galvão et al.2023). The

superelasticity effect is a special case of shape memory, which shape recovery happens only with the removal of tension, without the need for heat treatment. In general, there is a large recoverable strain under loading and unloading, at appropriate temperature. The recovery of the shape occurs only with the removal of the voltage, without the need for heating, that is, as soon as the instrument is removed from the inside of the channel, the instrument returns to its original shape. (Ananias et al. 2024).

The evolution of mechanized systems that use nickel titanium instruments with rotational and/or reciprocating movements is a reality in dental offices. The rotary instruments preceded the reciprocating instruments and both brought new ideas regarding the preparation of the root canal, especially when compared to stainless steel instruments, in relation to their characteristics, such as the NiTi metal alloy, or the heat-treated M-Wire, which has greater flexibility and greater resistance to fracture, inactive tip, taper variation, Neutral cutting angle, negative or even radial band, variable helical angle, among other characteristics. In addition, with the evolution of rotary and reciprocating instrumentation and the safety that it has brought to the preparation of the root canal, it has presented several benefits, such as the increase of the irrigating solution at the apical level, greater elimination of pulp tissue remains, reduction of non-instrumented areas of the root canal, reduction of microorganisms that allow a better filling of the root canal system. (Fornari, 2016).

The main advantages of using rotary instruments are the shorter time spent on preparation and the possibility of easily following the curvature of the channel due to the greater flexibility of NiTi files, preserving their original shape, with less extrusion of excised material via apical. As a disadvantage, these instruments act by widening and rotate around the same axis, causing a circle wear on the walls of the flattened root canals (Vila-Boa et al 2013). Thus, automated instrumentation was chosen for this case because it provides varied conicities and has the following benefits: better apical control of the instruments, greater capacity to clean the root canal and better adaptation of the main cone of gutta-percha during filling. One of the most relevant benefits is that the shape of the instrument would be closer to the morphology of the root canal, providing a simpler and more satisfactory preparation and, consequently, a more efficient filling, therefore, the technical procedures of instrumentation must always respect the root anatomy, as it is what dictates how the root canal should be prepared. In view of the complexity of the root canal system, such as areas of flattening and curvatures that cause interference to the

preparation, we must have techniques and different instrument systems that facilitate the preparation of the root canal. (Travassos et al. 2024).

It is considered necessary for the operator to have scientific knowledge and manual skill to perform the necessary operative steps that have a higher learning curve. Factors such as a good prognosis, longevity of the treatment and, above all, the health and function of the tooth in question must be achieved. (Travassos et al. 2023). Familiarity with the systems, the ability to use them, and knowledge of best practices are essential to ensure effective and safe retreatment. Ongoing training, along with updating on the latest techniques and technologies, is a valuable approach for professionals seeking high-quality results. In the present case, the operator has been a specialist in endodontics for more than 20 years and with a lot of skill in performing instrumentation with files that have been launched in the dental market.

## **CONCLUSION**

It is concluded that the preparation with Solla Collors files determines an adequate formatting and modeling of root canals of the lower molar.



## REFERENCES

1. Ananias, J. S., et al. (2024). Fractured lima removal and endodontic treatment: Case report. *\*Revista Brasileira de Saúde*, 7\*(1), 6033–6045.
2. Belala, I. C. (2021). Minimally invasive endodontics: Comparison between VDW aslimas, ROTATE™, and TruNatomy—Narrative review (Master's thesis). Fernando Pessoa University, Faculty of Health Sciences, Porto.
3. Corrêa, B. (2015). Influence of single-use rotary files and reciprocating movement on chemical-mechanical preparation of root canals (Monograph). Faculty of Dentistry of Piracicaba.
4. Fornari, V. J. (2016). Histomorphometric analysis of the cleaning of the apical third of root canals prepared with reciprocating and continuous rotational instruments—In vivo study. Piracicaba: State University of Campinas, Faculty of Dentistry of Piracicaba.
5. Galvão, A., et al. (2023). Endodontic treatment in the mandibular molar using endodontic technologies. *\*Brazilian Journal of Implantology and Health Sciences*, 5\*(5), 3801–3820.
6. Tenuta, M. C. M. (2024). Hybridization of endodontic instrumentation systems: Case report. *\*Facsete\**.
7. Travassos, R. M. C., et al. (2023). Re-aggravation of extensive periapical lesions: Case report. *\*Ibero-American Journal of Humanities, Sciences and Education*, 9\*(7), 1–12.
8. Travassos, R. M. C., et al. (2024). Preparation of the lower molar with periapical lesion with Solla Files Collors files. *\*Brazilian Journal of Implantology and Health Sciences*, 6\*(10), 4343–4352.
9. Vilas-Boa, R. C., et al. (2013). Reciproc: Comparison between reciprocating and rotational kinematics in curved channels. *\*Revista Odontológica do Brasil Central*, 22\*(63).