


## ENDODONTIC TREATMENT OF UPPER SECOND PREMOLAR WITH 3 ROOTS AND 3 RADICULARS – CLINICAL CASE REPORT

 <https://doi.org/10.56238/arev7n4-085>

Date of submission: 09/03/2025

Date of publication: 09/04/2025

**Rosana Maria Coelho Travassos<sup>1</sup>, Pedro Henrique Pereira de Souza<sup>2</sup>, Pedro Guimarães Sampaio Trajano dos Santos<sup>3</sup>, Priscila Prosini<sup>4</sup>, Alexandre Batista Lopes do Nascimento<sup>5</sup>, Kattyenne Kabbaz Asfora<sup>6</sup>, Mônica Maria de Albuquerque Pontes<sup>7</sup>, Adriane Tenório Dourado Chaves<sup>8</sup>, Josué Alves<sup>9</sup>, Verônica Maria de Sá Rodrigues<sup>10</sup> and Maria Tereza Moura Cavalcanti<sup>11</sup>**

### ABSTRACT

Variations in the root canal anatomy of a maxillary first molar are often challenging to diagnose and treat; thus, clinicians must have a thorough knowledge of the same. This case report highlights the successful nonsurgical endodontic management of a maxillary first molar with an unusual morphology. Three canals were prepared using Sequence Niti rotary instruments (MK Life) to #25.06, and the root canals were irrigated with 2,5% sodium hypochlorite solution. Root canal filling was performed using the single cone technique associated with Bio-C Sealer cement and 25.06 taper gutta-percha tip were used. It is concluded that thorough knowledge of the variations in root canal anatomy is necessary for the successful outcome of the endodontic procedure.

**Keywords:** Endodontic. Premolar. Root canal. Anatomical variation.

---

<sup>1</sup> PhD

University of Pernambuco, Brazil

<sup>2</sup> General practitioner

University of Nova Iguaçu -RJ

<sup>3</sup> Undergraduate student

Recife Dental School

<sup>4</sup> PhD

University of Pernambuco, Brazil

<sup>5</sup> PhD

University of Pernambuco, Brazil

<sup>6</sup> PhD

University of Pernambuco, Brazil

<sup>7</sup> PhD

University of Pernambuco, Brazil

<sup>8</sup> PhD

University of Pernambuco, Brazil

<sup>9</sup> PhD

University of Pernambuco, Brazil

<sup>10</sup> PhD

University of Pernambuco, Brazil

<sup>11</sup> PhD

University of Pernambuco, Brazil

## INTRODUCTION

The variation in the number of roots, canals, root direction, longitudinal depressions of the roots, the various shapes of the pulp cavity and the problems in visualizing the apical limit by radiographs make the endodontic procedure of these teeth quite challenging. (Khan et al. 2024).

Numerous factors influence the variations found in the root canal morphology including ethnic background, gender, method of data collection, sample size and the mode of studying the root canal space. Three-rooted premolars are more frequent in Caucasian populations and practically non-existent in Asian populations. (Soares, Leonardo, 2003).

Visualization of three canals in a maxillary premolar on pre-operative radiographs can often be difficult. Although the pre-operative radiograph gives a two dimensional image of a three dimensional object, there are some guides that suggest the presence of a third canal/root. Whenever there is an abrupt straightening or loss of radiolucent canal in the pulp cavity, a third canal should be suspected, either in the same root or in the other independent root. Also, whenever the mesio-distal width of the mid-root area is equal to or greater than the mesio-distal width of the crown, the tooth most likely has three roots and multiple canals are common when a radiograph shows an eccentrically placed instrument in roots. (Sieraski et al. 1985).

Maxillary second premolars present significant challenges in pulp treatment due to their variable root number, complex root canal structure, diverse root orientation and longitudinal depression, and varying pulp cavity configurations. The variation in maxillary second premolars is significant, with the majority exhibiting two root canals, while the incidence of three root canals ranges from 0.5% to 7.5% (Kong et al. 2020). Determining the number of root canals and the location of root canal orifices in the early stage of treatment is crucial for the success of root canal therapy.

The objective of this study is to report a similar case of maxillary first premolar having three roots with separate 3 canals. Endodontic success requires a thorough understanding of root canal anatomy. The variation in the number of roots, canals, root direction, longitudinal depressions of the roots, the various shapes of the pulp cavity and the problems in visualizing the apical limit by radiographs make the endodontic procedure of these teeth quite challenging

## CASE REPORT

The aim of this case was to understand and treat the intricate root canal anatomy observed in complex maxillary second premolar, particularly those exhibiting three root canals, emphasizing the significance of understanding root canal morphological variations in their treatment.

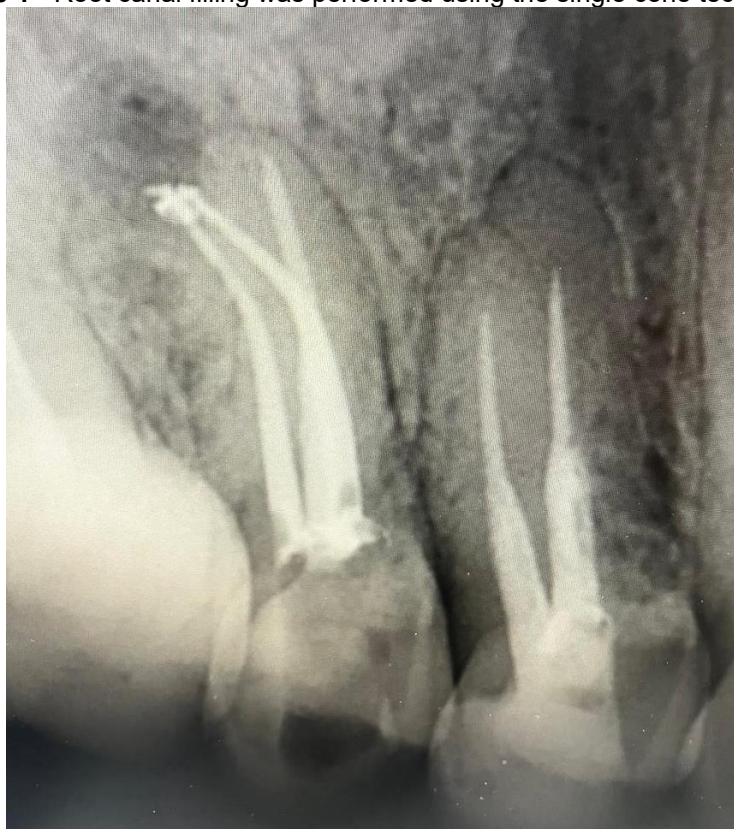The patient was a 23-year-old male. On November 23, 2022, he presented with occasional intermittent spontaneous pain due to secondary caries in the right upper posterior tooth. Clinical Examination: The distal adjacent surface of the left maxillary second premolar exhibited resin filling, with visible edges and loose filling material upon probing. Pain was elicited upon exploration, with slight percussion tenderness noted. No evidence of loosening or redness and swelling of the gingiva was observed. The temperature test was sensitive. The radiograph confirmed the presence of 3 root canals of the upper right second premolar.

Treatment, discovery, and confirmation of three root canals: Root canal therapy of left upper second premolar. Informed consent was obtained from the patient. Epinephrine-containing lidocaine local infiltration anesthesia for dental procedures, with the rubber septum. In the maxillary left second premolar, the pulp was accessed following pulp exposure, and the mesiobuccal root canal was detected using the DG-16 probe. The triangular access cavity of this premolar resembled that of a molar and three distinct orifices were located corresponding to three canals. Mesio-buccal (MB) and disto-buccal (DB) orifices were located in close proximity to each other and the palatal orifice was found to be located in line with the palatal cusp tip.

One root canal was identified on the palatal side. The root canals were unobstructed with 10 stainless steel C-Pilot (VDW). Two root canals were found to be unobstructed and curved at an angle. Additionally, two pulp extraction needles were removed during the procedure. The length of the root canal was measured using the root canal length measuring instrument (Root ZX, Morita, Japan), with the palatal root canal measuring 21 mm and the buccal root canal also measuring 21 mm. Images were observed in the distal buccal root canals, raising suspicion regarding the presence of additional distal buccal root canals. When the dentin canals of the isthmus were repaired under the microscope, two root canals, namely, the proximal buccal and distal buccal root canals, were observed a few millimeters away from the original buccal root canal.

Three canals were prepared using Sequence Niti rotary instruments (MK Life) to #25.06, and the root canals were irrigated with 2,5% sodium hypochlorite solution. Root canal filling was performed using the single cone technique associated with Bio-C Sealer cement and 25.06 taper gutta-percha tip were used. The postoperative X-ray showed that all the 3 canals were filled (Figure 1).

**Figure 1** - Root canal filling was performed using the single cone technique.



## DISCUSSION

Thorough knowledge of anatomic variations of the root canal system, careful interpretation of the angled radiographs and adequate access cavity preparation and exploration of the canals are required for successful endodontic therapy. The variation in the number of roots, canals, root direction, longitudinal depressions of the roots, the various shapes of the pulp cavity and the problems in visualizing the apical limit by radiographs make the endodontic procedure of maxillary second premolars quite challenging.. Khan et al. 2024). Additional radiographs with different angulations can be taken to confirm any uncommon anatomical features when a preoperative radiograph reveals an irregular contour and shape of the tooth.<sup>16</sup> An abrupt straightening or loss of a radiolucent channel in the pulp cavity might be suggestive of an additional canal in the same or a separate root.

In premolars, the existence of an eccentric orifice that is not in its normal place raises the possibility that there may be an additional canal. (Chaniotis , Ordinola-Zapata, 2002).

The x-ray examination is essential for a correct endodontic treatment, in both the diagnosis and treatment plan or to assess the outcome; however, it frequently fails in the detection of roots and auxiliary canals because the amount of data obtained by conventional film and periapical x-rays is limited by a series of events: (i) the 3D anatomy of the zone that has been x-rayed compresses into a 2D image, (ii) superposition of structures, (iii) geometric distortion of the anatomical structures. These issues can be overcome by the use of CBCT, which can produce 3D images of the individual teeth and surrounding tissues, allowing exploration on the sagittal and coronal planes, deprojecting the anatomical structures and providing accurate information about the number of roots and canals. (Patel et al. 2007).

This case was treated with a rubber stamp and a microscope. The rubber dam helped maintain a clear field of view during the treatment. In dental treatment, a clear field of view is crucial for clinicians, as it prevents saliva, blood, and medication from obstructing vision, thus improving the efficiency and accuracy of treatment.( Krasner, Rankow, 2004). The morphology of the pulp floor can be observed under the microscope, which helped reduce the likelihood of missing root canals (Lin, 2020).

The clinical management of premolars with three canals is complex due to their different anatomical variations. Nowadays, for root canal treatment, magnification (magnifying glasses, microscope), biomechanical preparations with mechanized instruments (rotary, reciprocating) and ultrasonic irrigation are used and are very helpful (Crozeta et al. 2020). In this case, the dentine shoulder collar of the distal buccal root canal orifice was accurately removed under the microscope, facilitating the establishment of a straight path for root canal clearance. Compared with traditional root canal therapy, the widely popularized microroot canal therapy is particularly significant in terms of both curative effect and root canal detection rate. In this case, the ProTaper Nickel titanium system was used to treat the root canal. the use of a nickel–titanium system can reduce the operation time, preserve the original shape of the root canal, and reduce the complications after root canal treatment, and the success rate of root canal treatment over time is more than 96%.( Mengya et al. 2024). Clinically, the access opening for the upper premolars is generally oval in the bucco-palatal direction. In cases of premolars with three roots, it is recommended that the access opening be modified, slightly expanding it in a more

mesiodistal direction to discover the second buccal canal, completing the preparation of the cavity by giving it a triangular shape, similar to the access opening for an upper first molar, but smaller. (Velmurugan et al. 2005).

Failure in root canal treatment can be attributed to many factors such as lack of knowledge of canal anatomy, unfilled or incompletely debrided canals, persistence of bacteria, iatrogenic procedural errors, such as poor cavity conformation at the time of chamber opening, as well as complications at the time of biomechanical preparation. (Vera, 2020). New technological tools, such as dental study microscopy, greatly enhance the viewing area of root canal holes, allowing the work area to be enlarged and illuminated to a greater extent. Considering these advantages, de Carvalho, Zuolo, 2000, explained the importance of microscopes, which can significantly improve the prognosis of treatment.<sup>15</sup> In order for the root canal treatment to be successful, a dental microscope was used for the detection of extra canals and the appropriate chemomechanical preparation.

Knowledge of the relevant tooth's root canal anatomy and its variations from the normal is important for the success of root canal treatment. A detailed interpretation of radiographs coupled with accessibility and inspection of the pulpal floor under magnification can play an important role in the root canal treatment of complex root canal anatomy in endodontics. (Saklar et al. 2023). Therefore, the case report presented here suggests that the dentist's lack of knowledge about the probable changes in anatomy that may occur in premolar pulpectomy can lead to its failure. Therefore, the professional must know how to perform correct coronary access, since it is an essential factor to locate all the canals and instrument them correctly. (Silva et al. 2023).

The case report design, while valuable for highlighting unique clinical scenarios, has inherent limitations. Our study is limited by the small sample size, which restricts the generalizability of the findings. Additionally, the lack of a control group or comparative analysis with alternative treatment modalities may affect the interpretation of the results. It can be stated, therefore, that this case report brings the relevance of knowledge of internal dental anatomy and its variations, which together with a good coronal opening and contour shape/convenience, are favorable prerequisites for the identification and confirmation of the number and position of the canals. Since the combination of these factors offers an improvement in the optical field and in the distinction of microstructures, favoring the success of pulpectomy, especially in cases of additional canals. As well as, it brings another case of anatomical variation from the literature, this one, in an upper second premolar, so



that dentists know the importance of prior knowledge of these alterations, and that even in low incidence, they can exist and lead to the failure of the procedure if they are not identified and treated correctly, thus, the professional needs to be ready to face and act in the face of these anatomical changes.

Future research involving larger cohorts and controlled studies would provide a more comprehensive understanding of the treatment approaches for complex endodontic cases.

## **CONCLUSION**

The prognosis of endodontic treatment is closely related to proper cleaning and shaping of the root canal, three-dimensional sealing of the canals and coronal restorations with good marginal seal. Thorough knowledge of the variations in root canal anatomy is necessary for the successful outcome of the endodontic procedure.

## REFERENCES

- CARVALHO MC, ZUOLO ML. Orifice locating with a microscope. J Endod. 2000; 26(9): 532-4.
- CHANLOTIS A, ORDINOLA-ZAPATA R. Present status and future directions: Management of curved and calcified root canals. International Endodontic Journal. 2022 May;55:656-84.
- CROZETA BM, CHAVES DE SOUZA L, CORREA SILVASOUSA YT, SOUSA-NETO MD, JARAMILLO DE, SILVA RM. Evaluation of passive ultrasonic irrigation and gentlewave system as adjuvants in endodontic retreatment. J Endod [Internet]. 2020; 46(9): 1279- 1285.
- KHAN, D., AHMED A., SABANA HAQ, S. et al. Endodontic Treatment Of Upper First Premolar With 3 Canals- Case Report. Journal of Rawalpindi Medical College, 2024, v. 28, n.2, p. 352-55
- KONG Q., LIANG L., WANG G., SHIQI Q., Cone beam CT study of root and root canal morphology of maxillary premolars, *Prevention and Treatment of Oral Diseases*. (2020) 28, no. 4, 246–251
- KRASNER P, RANKOW HJ. Anatomy of the pulp-chamber floor. Journal of endodontics. 2004;30(1):5-16.
- LIN T., Analysis of the curative effect of traditional root canal therapy and microscopic root canal therapy on difficult root canals, *Family Medicine Medicine Choice*. (2020) 5, no. 5, 81–82.
- MENGYA L., LU Y., AND XU Q.'A., Progress in root canal irrigation techniques and irrigation, *The Chinese Journal of Practical Stomatology*. (2024) 17, no. 2, 247–252.
- PATEL S, DAWOOD A, FORD TP, WHAITES E. The potential applications of cone beam computed tomography in the management of endodontic problems. Int Endod J 2007; 40: 818-830.
- SAKLAR F, ÖNCÜ A, SEVGI S, ÇELIKTEN B. Endodontic Treatment of Premolar Teeth with Different Root Canal Anatomy: Two Case Reports and Literature Review. Cyprus J Med Sci. 2023 Dec;8(6):453-456.
- SILVA, L. B. G. da; SOUSA, W. V. de; OLIVEIRA, J. R. B. de . Endodontic treatment of upper premolar with three root conducts – case report. Research, Society and Development, v. 12, n. 11, p. 1-9, 2023
- SIERASKI SM, TAYLOR GT, KOHN RA; Identification and endodontic management of three canalled maxillary premolars. J Endod, 1985; 15:29-32.
- SOARES JA, LEONARDO RT; Root canal treatment of three rooted maxillary first and second premolars- a case report. IntEndod J, 2003; 36:705-10.



VELMURUGAN N, PARAMESWARAN A, KANDASWAMY D, SMITHA A, VIJAYALAKSHMI D. Maxillary second premolar with three roots and three separate root canals-case reports. Aust Endod J 2005; 31: 73-75.

VERA MM. Valoración de éxitos y fracasos en endodoncia [Trabajo de grado en Internet]. Guayaquil: Universidad de Guayaquil; 2020. Available from: <http://repositorio.ug.edu.ec/handle/redug/48351>.