


**SIMPLIFIED PROTOCOL FOR INTRA OR EXTRA SINUS ZYGOMATIC  
IMPLANTOLOGY: NEW CLASSIFICATION METHOD**

**PROTOCOLO SIMPLIFICADO PARA IMPLANTOLOGIA ZIGOMÁTICA INTRA OU  
EXTRA-SINUSAL: NOVO MÉTODO DE CLASSIFICAÇÃO**

**PROTOCOLO SIMPLIFICADO PARA IMPLANTOLOGÍA ZIGOMÁTICA INTRA O  
EXTRASINUSAL: NUEVO MÉTODO DE CLASIFICACIÓN**

 <https://doi.org/10.56238/arev8n3-169>

Submitted on: 02/28/2026

Publication date: 03/31/2026

**Reginaldo Mário Miglioranza<sup>1</sup>, João Ricardo Almeida Grossi<sup>2</sup>**

**ABSTRACT**

Branemark developed a protocol for edentulous patients who had no residual bone by using bone of the same embryonic origin, i.e. zygomatic bone, in combination with the installation of conventional implants. Over time, there has been a significant increase in demand for zygomatic implants and we have witnessed the evolution of the technique, such as Professor Reginaldo Miglioranza's outsourced methodology. In this study, 279 zygomatic implants were placed in 126 patients, observing the relevance of an already established technique (with 25 years) and by far the most desirable, with the author proposing a new classification for zygomatic implant installation, following the original externalised technique in a simple and intuitive way; the simplified protocol for Externalised Zygomatic Implantation (ZES) includes only two possibilities ZETA (Zygomatic Externalised Fully Supported) and ZEPA (Zygomatic Externalised Partially Supported), supported by the lateral sinus wall.

**Keywords:** SEZ classification (Simplified Exteriorization Zygomatic). ZETA (Fully Supported Outsourced Zygomatic). ZEPA (Partially Supported Outsourced Zygomatic).

**RESUMO**

Branemark desenvolveu um protocolo para pacientes edêntulos que não possuíam osso residual, utilizando osso de mesma origem embrionária, ou seja, o osso zigomático, em combinação com a instalação de implantes convencionais. Ao longo do tempo, houve um aumento significativo na demanda por implantes zigomáticos, e observou-se a evolução da técnica, como a metodologia exteriorizada do professor Reginaldo Miglioranza. Neste estudo, 279 implantes zigomáticos foram instalados em 126 pacientes, observando-se a relevância de uma técnica já consolidada (com 25 anos) e, de longe, a mais desejada, com o autor propondo uma nova classificação para a instalação de implantes zigomáticos, seguindo a técnica original exteriorizada de forma simples e intuitiva; o protocolo simplificado para Implantação Zigomática Exteriorizada (ZES) inclui apenas duas possibilidades: ZETA (Zigomático Exteriorizado Totalmente Suportado) e ZEPA (Zigomático Exteriorizado Parcialmente Suportado), sustentados pela parede lateral do seio maxilar.

<sup>1</sup> Dr. in Implant Dentistry, São Leopoldo Mandic. E-mail: [miglioranza@outlook.com](mailto:miglioranza@outlook.com)  
Orcid: <https://orcid.org/0009-0000-6217-5269>

<sup>2</sup> Dr. in Dentistry, Dental Design School. E-mail: [grossinobel@gmail.com](mailto:grossinobel@gmail.com)  
Orcid: <https://orcid.org/0000-0003-2426-0686> Lattes: <https://Lattes.cnpq.br/2613113500115920>

**Palavras-chave:** Classificação ZES (Exteriorização Zigomática Simplificada). ZETA (Zigomático Exteriorizado Totalmente Suportado). ZEPA (Zigomático Exteriorizado Parcialmente Suportado).

#### **RESUMEN**

Branemark desarrolló un protocolo para pacientes edéntulos que no presentaban hueso residual, utilizando hueso del mismo origen embrionario, es decir, el hueso cigomático, en combinación con la colocación de implantes convencionales. Con el tiempo, ha habido un aumento significativo en la demanda de implantes cigomáticos y se ha observado la evolución de la técnica, como la metodología exteriorizada del profesor Reginaldo Miglioranza. En este estudio, se colocaron 279 implantes cigomáticos en 126 pacientes, observándose la relevancia de una técnica ya consolidada (con 25 años) y, con diferencia, la más deseada, proponiendo el autor una nueva clasificación para la instalación de implantes cigomáticos, siguiendo la técnica original exteriorizada de manera simple e intuitiva; el protocolo simplificado para la Implantación Cigomática Exteriorizada (ZES) incluye solo dos posibilidades: ZETA (Cigomático Exteriorizado Totalmente Soportado) y ZEPA (Cigomático Exteriorizado Parcialmente Soportado), sustentados por la pared lateral del seno maxilar.

**Palabras clave:** Clasificación ZES (Exteriorización Cigomática Simplificada). ZETA (Cigomático Exteriorizado Totalmente Soportado). ZEPA (Cigomático Exteriorizado Parcialmente Soportado).

## 1 INTRODUCTION

Simplicity is the height of sophistication said Leonardo Da Vinci's refined mind. However, after the superiority of the Externalized Technique in zygomatic implantology was proven, the need arose for a simple and complete classification for this new extra-sinus approach is more needed ever [1]. Intrasinus technique avoid bone grafts, in addition to potentially causing sinusitis, requiring long periods of rehabilitation and have low long term success rates [2]. The zygomatic implant technique was initially developed by Brånemark in the late 1980s (1988-1989), aimed at maxilectomized patients or those with major facial loss, allowing functional and aesthetic rehabilitation with oral and maxillofacial prostheses and only from the end of 1998 and the beginning of 1999 that the technique began to be applied to patients with severe atrophic maxillae, without the need for oncological procedures, expanding its use in conventional implantology [3]. In addition, the Brånemark technique which was preconized inside the sinus, lead to cause prosthetic discomfort with phonetic problems, but above all, it complicated the maintenance, resulting in failure of the zygomatic implants due to the persistence of sinus diseases, derived by the surgery was totally blind, as the operator performed it only by touch, with greater surgical invasion and longer surgical times [4].

Although innovative, the intrasinus technique presented significant limitations in clinical practice, as the anatomy of the maxillary sinus and the concavity of the anterolateral wall often forced the implant to emerge in the palatal position, hindering hygiene, phonetics, comfort, and prosthetic maintenance. The anatomical limitation also prevented the implant from anchoring itself properly in the zygomatic bone, generating biomechanically unfavorable trajectories and as a consequence, this approach progressively began to lose acceptance among implantodontists. Several authors, such as Stella and Warley (2000), have proposed appendices to the intrasinus technique, improving orientation and stability, but remaining fully within the intrasinus concept, and these improvements did not solve the prosthetic limitations, reinforcing that, in clinical practice, there are only two fundamental approaches, or intrasinus or extrasinus [1, 5, 6]. With the development of the externalized enhancement technique or Miglioranza technique, all of these problems have been significantly reduced, as it has resulted in less surgical invasion, full surgical visibility, and a considerable improvement in the placement of zygomatic implants, to the right prosthetic position and may be cleaned as conventional implants [7].

It also eliminated sinus diseases caused by antrostomy or sinus perforation during implant placement [8]. Zygomatic surgery is considered advanced implantology, but it is expected to be as simple as possible, as any surgery should be, respecting the principle of minimum invasiveness and the well-being of the patient [9]. From 2003 onwards, there was a significant conceptual change with the development of the extrasinusal technique, proposed by Miglioranza, which positions the zygomatic implant completely outside the maxillary sinus, close to the insertion of the masseter muscle, and in this region it allows greater bone volume and extensive anchorage, often greater than 15 mm, providing optimal primary stability, dissipation of biomechanical forces and favorable prosthetic positioning [1]. Unlike intrasinus trajectories, the extrasinusal technique avoids palatal emergence, reduces sinus complications, and facilitates implant maintenance and hygiene [10]. The introduction of the ZES (Zygomatic Externalized Simplified) classification, dividing implants into ZETA (fully supported) and ZEPa (partially supported), consolidates this approach as a safe, intuitive and predictable method. Unlike other classifications, such as the Aparicio ZAGA, which propose multiple intra- and extrasinusal trajectories, the present study focuses exclusively on the extrasinusal technique, applied consistently since the first cases, ensuring standardization, safety, and better clinical outcomes complete different from ZAGA concept Table 1.

**Table 1**

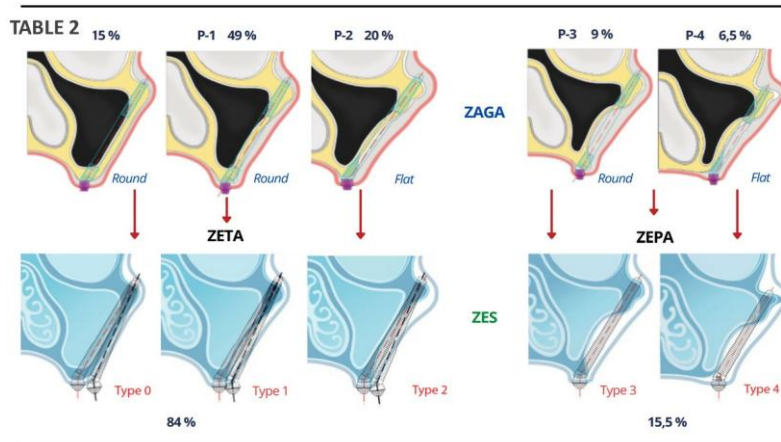
*Zaga Classification: Trajectory, Incidence and Clinical Indication*

**TABLE 1** ZAGA Classification: Trajectory, Incidence, and Clinical Indication

Classification	Trajectory	Percentage of Cases	Clinical Indication
ZAGA Type 0	Intrasinusal	Represents approximately 15% of cases	Contraindicated, not recommended
ZAGA Type 1	Combined intra-extra sinus trajectory	Represents approximately 49% of cases and involves invasion of the respiratory space	Not recommended in cases of diseased maxillary sinuses
ZAGA Type 2	Combined trajectory, predominantly extra-sinusal	Represents approximately 20% of cases	Not recommended in cases of diseased maxillary sinuses
ZAGA Type 3	Completely extra-sinusal trajectory	Represents approximately 9% of cases	Recommended for all patients
ZAGA Type 4	Extra-maxillary trajectory, without stabilization on the residual alveolar crest	Represents approximately 6.5% of cases	Recommended for all patients

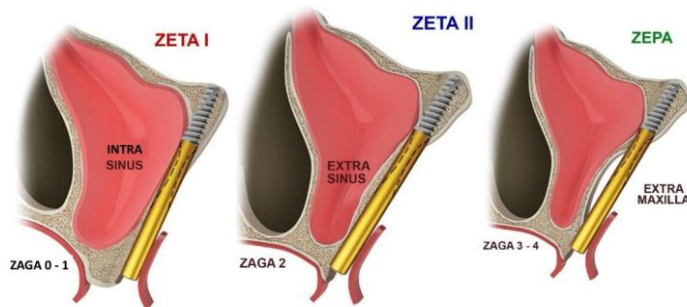
The existing classification, known as ZAGA, combines internal, combined, and external sinus techniques and includes methods that are often contraindicated because they are not free of complications Table 2 [11].

**Table 2**



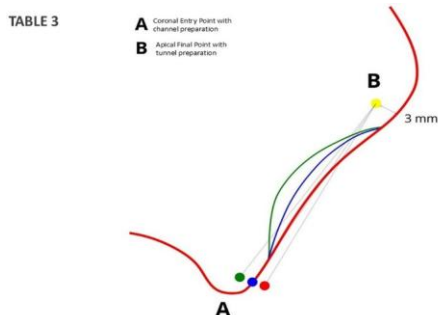
Although the extrasinusal technique was developed in the early 2000s, its international dissemination occurred gradually. Initially, the application was limited to pioneering groups, especially in Brazil, due to the absence of digital resources and efficient global scientific communication. In the last five years, with the advancement of digital scientific communication and greater international interest, the technique has become widely recognized and adopted worldwide, consolidating itself as a reference for the rehabilitation of severely atrophic maxillas.

**Figure 1**



The new ZES Classification (Fig. 1a, b, c) outsourced implant methodology classified by Miglioranza, which has been widely recognized with a consensus from which there is no turning back [10, 12]. Unlike ZAGA, it focuses exclusively on the extrasinus technique, which makes it a much simpler and more intuitive classification, summarizing the most recommended methodologies for zygomatic implantology in the scientific literature [13]. Therefore, the placement of zygomatic implants can always be performed externally it depends the entry poin of the first drill as shown in the Table 3, and the authors introduces a new classification for the technique (ZES) being used since 2004 by the authors.

**Table 3**

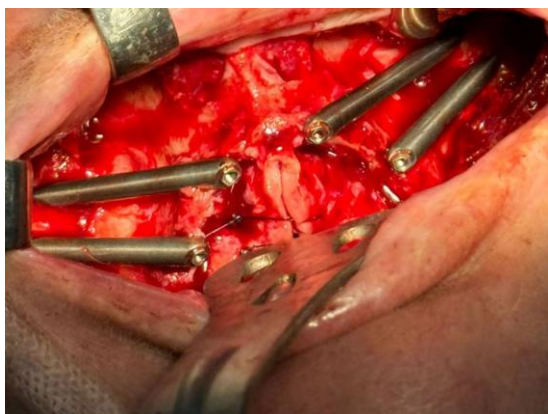

## 2 MATERIALS AND METHODS

This study preserved the anonymity of patients, as well as their rights, care, and information, as recommended by the 1964 Declaration of Helsinki. The work protects the secrecy and confidentiality of the data and the preservation of the names of the participants, and only the data provided and described in this study will be characterized and used together. In order to avoid unpredictable and unavoidable complications of anatomically guided zygomatic implant dentistry, the techniques ZAGA Type 0 and 1, i.e., combined intra-sinus and intra-extrasinus, are not trajectories addressed in this study [11]. Prior to surgical procedures, patients were washed with 0.12% chlorhexidine gluconate (ColgatePalmolive Company, New York, USA). Extraoral disinfection was performed with 10% povidone-iodine (São José do Rio Preto, São Paulo, Brazil) and local anesthesia was applied with 4% articaine with epinephrine 1:100,000 (DFL Indústria e Comércio S/A, Rio de Janeiro, RJ, Brazil). The surgical preference in this study considered the anatomical profile of the frontal sinus wall and the amount of residual crestal bone as the technique of choice for our study and it was a simplified protocol of extrasinus zygomatic anchorage or externalized Miglioranza technique improved in 2004, with immediate loading [9].

The present study applied the author's proposal in three different institutions, with a total of 279 zygomatic implants, all installed with immediate loading and the surgeries were performed by the course coordinator, Dr. Reginaldo Miglioranza and Dr. João Grossi, with the installation of four zygomatic implants. Of these patients, 138 cases were performed under local anesthesia and 72 under conscious sedation totaling 82 different patients. Complete rehabilitation with immediate loading was performed in all patients with advanced severe atrophy. The Balan diamond drill was extremely useful in preparing the bed or canal in which the implant body is housed, eliminating implant flexion in all patients [14]. Following the evolution of zygomatic implants, only two techniques can be highlighted, called the Intra-Sinus Technique and the Extra-Sinus Technique [15]. The Intra-Sinus Technique was introduced by Brånemark in 1998, and the Extra-Sinus Technique was introduced by Miglioranza in January 2006, with cases performed since 2003 (Fig. 2).

**Figure 2**

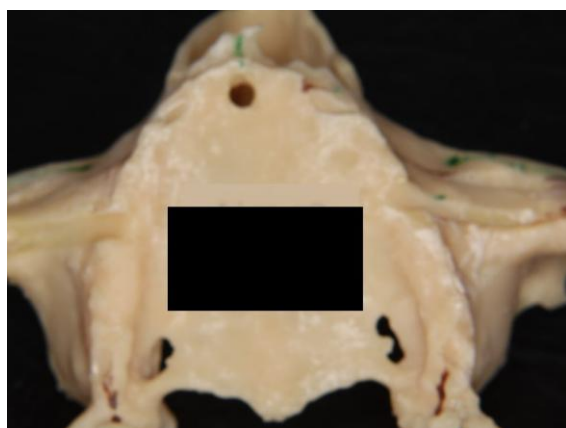


### 3 RESULTS

In all 279 implants placed, no postoperative complications of the paranasal sinuses, paresthesias, bleeding or rupture of the parotid ducts that could cause subcutaneous leakage of salivary fluids and infect the surgical region were observed (Figure 3-8).

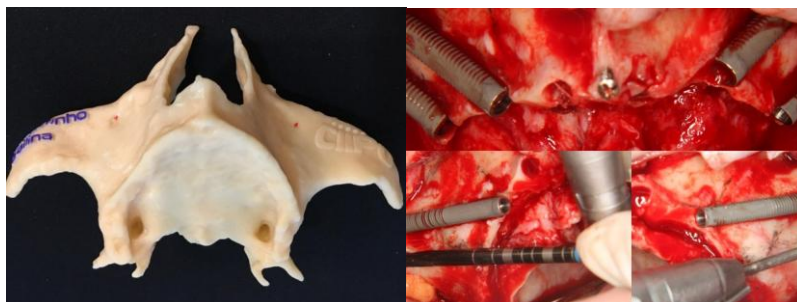**Figure 3**

*Clinical case 1: Printed Biomodel*



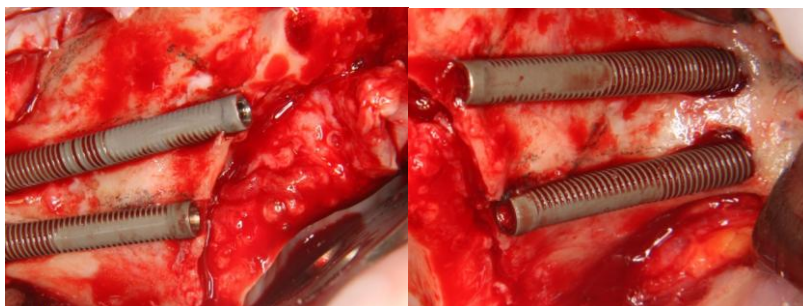
**Figure 4**

*Clinical case 1: Rehabilitation with four zygomatics according to the ZES classification printed Biomodel*



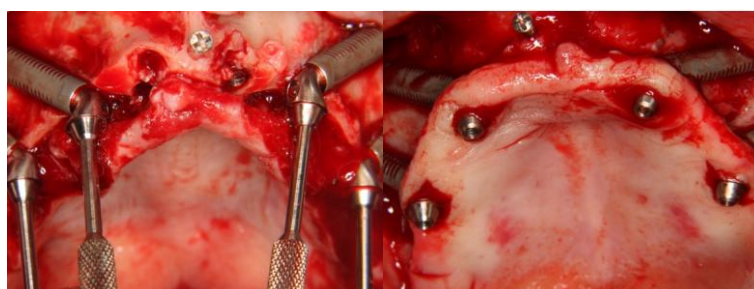
**Figure 5**

*Clinical case 1: Double Zigoma Right and left*



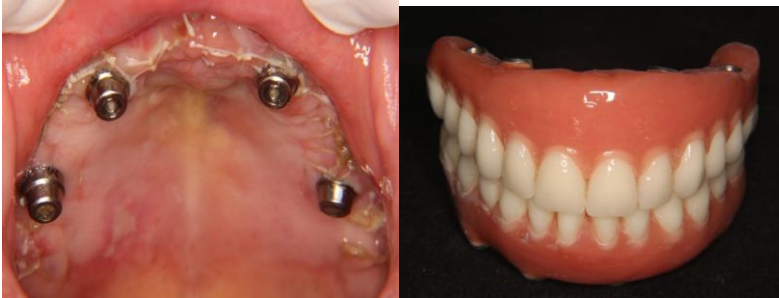**Figure 6**

*Clinical case 1: Multi-Unit 45 degrees, and soft tissue thickness*



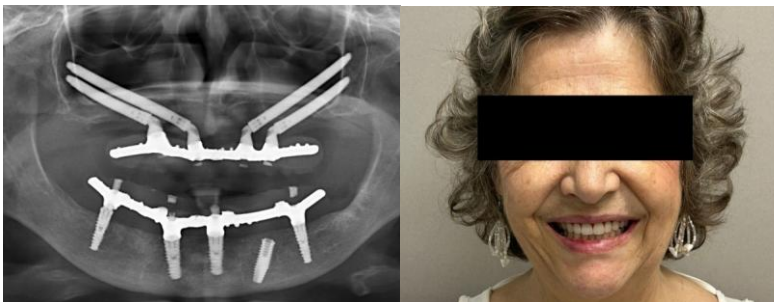**Figure 7**

*Clinical case 1: Final suture and final prosthesis with bar*



**Figure 8**

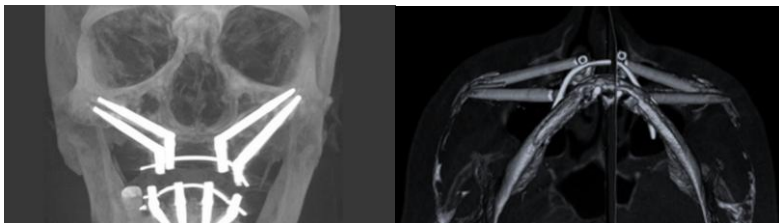
*Clinical case 1: Final panoramic and facial final smile.*



Placing the implants on top of the crest, improving the prosthetic positioning where in hybrids the palatal flap is worked, which increases considerably, reducing the space of the tongue and impairing phonetics.

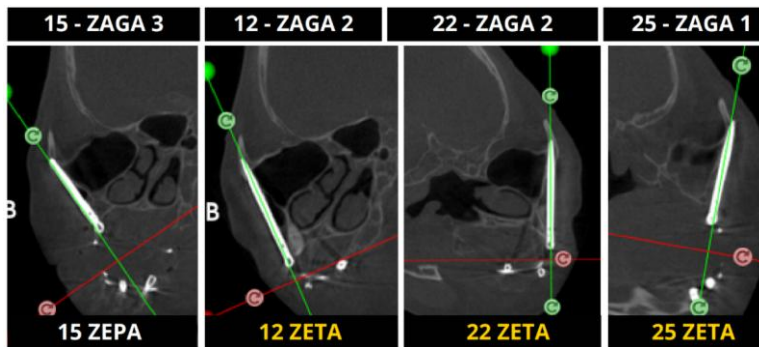
**Figure 9**

*Clinical case 2: Rehabilitation with four zygomatics according to the ZES classification*



**Figure 10**

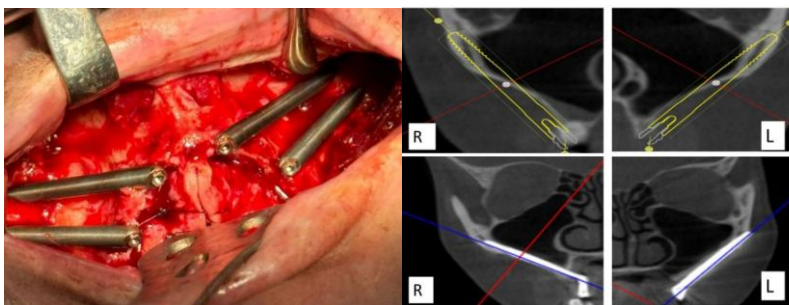
*Clinical case 2: Software 3D view of rehabilitation with four zygomatics according to the ZES classification comparing to ZAGA classification*



The first choice it was always the All-On-4 Hybrid Technique, so it is crucial to ensure the initial installation of conventional sub-paranasal implants as anterior abutments. Only if this technique is not feasible, one should switch to the Quad Zygoma technique. From 2019 onwards, the author completely changed his thinking, opting for Quad zygoma technique as his first option by giving priority to a rehabilitation of excellence.

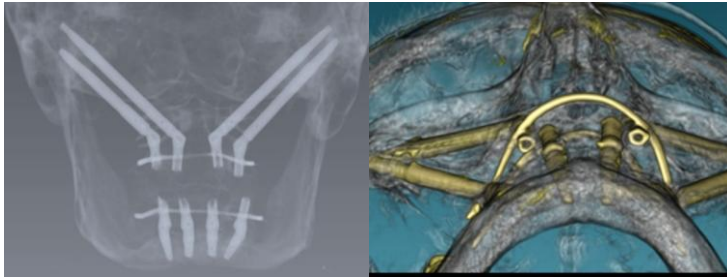**Figure 11**

*Clinical case 3: Rehabilitation with four zygomatics following the ZES classification with computer-aided planning*



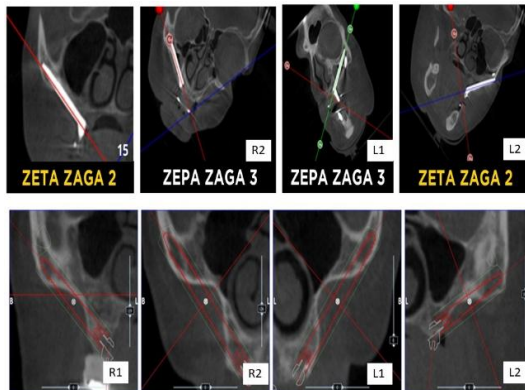
**Figure 12**

*Clinical case 3: Rehabilitation with four zygomatics Panoramic Rx and 3D reconstruction in software*



**Figure 13**

*Clinical case 3: comparison between virtual planned and executed in real surgery by freehand*



#### 4 DISCUSSION

The Extra-Sinus Technique has been recognized and adopted by leading surgeons around the world for its ease, predictability, excellent surgical field, great visibility and ability to position the implant platform over the alveolar ridge, taking into account its centripetal resorption [16]. Other concepts serve as adjuncts or complement to the original techniques, such as Stella's in 2000, which involved Schneider's membrane detachment, which involved Schneider's membrane detachment, with only an orientation channel for implant installation, but still being intrasinus's approach and Aparicio's in 2011, which proposed the ZAGA

classification with ZAGA (0) follows a path within the sinus without preserving Schneider's membrane, adhering to Brånemark's initial proposal [6, 11, 17]. The ZAGA (1) also follows an intra-sinus path, but preserves the membrane, and the ZAGA (2) follows a path that is more extra-sinus than intra-sinus and finally the ZAGA (3) follows a completely extra-sinus path, in an alveolar-zygomatic suspension bridge configuration [11]. Our classification defined as ZEPA (ZES Classification) because it partially rests on the wall of the middle III of the face. finally, ZAGA 4 is extramaxillary due to the absence of crestal residue defined as ZEPA [16].

For this reason, the Externalized Technique initially described by Miglioranza was chosen, which has consistently shown excellent results, mainly because it avoids sinus complications [18]. This technique is simple, replicable, and predictable, both in a fully extrasinusal pathway for moderately and severely concave walls, and in a juxta-sinus pathway for slightly concave or flat, convex maxillary anatomy and independent of the anatomy of the lateral wall of the maxillary sinus [16]. To obtain better predictability, the posterior zygomatic implant is placed close to the insertion of the masseter, remaining parallel to the anterolateral wall of the sinus, converging to the apex of the anterior implant with this increases the Roy polygon, while the anterior zygomatic implant is placed at least 5 mm more cranially, towards the area of highest bone density, close to the jugal point of the malar bone [19]. This externalized methodology involves stabilizing the implant body at the anterior wall of the mandible and the ridge through the preparation of a shallower channel for convex jaw geometries, as opposed to a deeper preparation of the bed for concave profiles [20].

The QUAD Zygoma technique, described by Bothur in 2003, was also used, and in cases where there was no bone in the premaxillary region, with resorption up to the base of the nose, the author called everything 4 Zygomas [5]. The general health status of the patients, the position of the infraorbital and zygomatic nerves, the pneumatization of the maxillary sinuses, the Schneider membrane and the emergence of the parotid ducts, which are noble anatomical parts that require attention, were also observed, thus ensuring the safety and success of the treatment but still a dangerous technique because it was intra sinus, with great difficulty on the part of the surgeons, as it was a surgery only by touch, without visibility [21]. A recent literature review suggests five scenarios with the ZAGA classification, which differ according to the position of the residual alveolar ridge or bone

resorption, and in relation to the concavity or convexity of the anterolateral maxillary wall and maxillary sinus pneumatization [22].

Maxillae with advanced and/or severe atrophy would deserve special attention, as the intraoral starting point of the zygomatic implant should preferably be chosen in planning based on a small bone remnant, creating a small groove to stabilize the cervical neck of fixation, thus eliminating flexion and avoiding gingival retraction over time preferring however, smaller implant diameters in cases of lack of crestal bone and keratinized gingiva [9]. A flap incision plus palatine and a pedicled palatal gingival graft are also suggested in cases of absence of keratinized buccal gingiva in the implant neck [23]. In cases of severe atrophy, angled Bestance osteotomy has been performed in the posterior region of the maxilla for prosthetic purposes, following the Spee curve, since tubercle extrusion occurs in this region due to the prolonged use of total dentures or in cases with Kelly syndrome [24]. Another technique addressed in osteotomy has been the correction of accentuated bone concavities with a "carbide drill", transforming it into a less accentuated concavity, allowing the implant after osteotomy to be in close contact with the lateral wall of the sinus, ensuring greater stability and less flexion stress.

The implants followed the orientation of the author's proposal, ZEPA and ZETA (Fig. 2), based on the anatomy of the middle III of the face, making an orientation groove with the Balan drill and depending on the inclination of the lateral sinus wall, an osteotomy was performed so that the implants were parallel and in close contact with the lateral sinus wall [1]. The residual crestal bone of the maxilla was exploited to the maximum with the support of the implant head, thus reducing the flexion force [24]. The main objective is to reside the bone as much as possible in the floor of the canal, protecting the Schneiderian membrane and also dissipating forces in this region [25]. During the placement of zygomatic implants, the apices should be convergent, at the insertion of the masseter, where there is greater quantity and better bone quality, thus increasing the Roy polygon, and increasing the space for placement of another anterior implant, promoting greater stability and dissipation of forces, thus reducing the often neglected lateral cantilever, since other areas have thinner trabeculae [26].

With the externalized technique, the author proposes not to transfix the zygomatic button with the apex of the implant, because with the externalized technique there is greater anchorage and better force distribution, when the implant is in close contact with the bone wall of the sinus, avoiding deformations by flexion compared to the initial methodology [24].

Comentado [JG1]: Quem disse isto? Preciso da referencia...

In addition, transfixation with protrusion of the tip or apex of the implant can cause infection and cutaneous fistulas [25]. In fact, if this externalized technique is performed correctly, 45° for prosthetic abutments is usually sufficient in most cases, especially for the posterior zygomatic implant and for the anterior zygomatic, and 55° or even 60° for cases where there is no residual bone in the socket, especially for the anterosuperior zygomatic [27]. Cases of external Hexagon where the 45 straight abutments already exist are in most cases performed by the author's.

In addition, the digital world has dynamic surgical navigation planning software, which allows the deviation of vital anatomical structures with extreme precision and predictability, which is why clinical cases of All-On-4 Hybrid and Zygoma have been carried out with 3D anatomical models, surgical model and navigated surgery [28]. The incidence of fully or partially supported trajectory in the bone wall of the anterior sinus, with an average of 15.5% for the ZEPA trajectory and an 84% increase in the percentage of ZETA. However, this merits further investigation with a larger sample and proper statistical analysis. (Table. 2).

The evolution of zygomatic implants as a solution for the oral rehabilitation of patients with severe maxillary atrophy is marked by a series of studies and technological advances [1, 6]. Several researchers have dedicated themselves to exploring the potential of the zygomatic bone as a basis for dental implants, and others have come up with complex acronyms that confuse users [9, 11]. Another important point of the technique is the predictability and the guarantee that there are no perforations that can lead to chronic sinusitis, bucco-sinus communication and transfixation with the apex of the implant, which can cause cutaneous fistulas, making the treatment much more painful and preventing the patient from having a good social-relational quality of life [29, 30].

## 5 CONCLUSION

The new ZES classification of the simplified externalized zygomatic implant protocol includes only two possibilities: ZETA Fully Supported and ZEPA Partially Supported. This new classification involves only two variants of the anatomical technique, ZETA and ZEPA, which proved to be simple and intuitive to use, where all implants installed had completely extrasinusal trajectories. The revolutionary concept is that unfavorable anatomy no longer determines the contraindicated trajectories of the implant (intrasinus or combined intra-extra), but rather the surgical skill in delineating a completely extra-sinus ZEPA or iuxta-

sinus ZETA trajectory as a mandatory second option in the case of unfavorable convex profiles of the jaw wall.

By performing the externalized zygomatic implant technique developed by Prof. Miglioranza, it is proposed to adopt the new ZES (Zigomatic Externalisation Simplified) classification, which can evolve into ZETA or ZEPA (Fig. 1.a, 1.b). If ZETA is performed (in rectilinear anatomy), 14 days of antibiotic therapy will be required if any abnormality occurs in the sinus membrane. Finally, if the ZEPA trajectory is performed (in concave anatomy) with a Partially Supported pathway, the zygomatic implant is comparable to a conventional implant and 1 g of Amoxicillin every 12 hours for seven days after the procedure, for example, is sufficient. Because some patients have facial asymmetries, we may have a fully supported implant (ZETA) on one side and a partially supported implant (ZEPA) on the other.

## REFERENCES

- Miglioranza, R., et al. (2006). Sinus exteriorization of the zygoma fixtures: A new surgical protocol. *ImplantNews*, 3(5), 30–35.
- Molinero-Mourelle, P., et al. (2016). Surgical complications in zygomatic implants: A systematic review. *Medicina Oral, Patología Oral y Cirugía Bucal*, 21(6), e751–e757.
- Malo, P., et al. (2015). Extramaxillary surgical technique: Clinical outcome of 352 patients rehabilitated with 747 zygomatic implants with a follow-up between 6 months and 7 years. *Clinical Implant Dentistry and Related Research*, 17(Suppl. 1), e153–e162.
- Kuabara, M. R., et al. (2010). Rehabilitation with zygomatic implants: A treatment option for the atrophic edentulous maxilla—9-year follow-up. *Quintessence International*, 41(1), 9–12.
- Bothur, S., Jonsson, G., & Sandahl, L. (2003). Modified technique using multiple zygomatic implants in reconstruction of the atrophic maxilla: A technical note. *The International Journal of Oral & Maxillofacial Implants*, 18(6), 902–904.
- Stella, J. P., & Warner, M. R. (2000). Sinus slot technique for simplification and improved orientation of zygomaticus dental implants: A technical note. *The International Journal of Oral & Maxillofacial Implants*, 15(6), 889–893.
- Miglioranza, R. M., et al. (2011). Restoration of the edentulous maxilla using extrasinus zygomatic implants combined with anterior conventional implants: A retrospective study. *The International Journal of Oral & Maxillofacial Implants*, 26(3), 665–672.
- Chrcanovic, B. R., Albrektsson, T., & Wennerberg, A. (2016). Survival and complications of zygomatic implants: An updated systematic review. *Journal of Oral and Maxillofacial Surgery*, 74(10), 1949–1964.

- Migliorança, R. M., et al. (2012). Immediate occlusal loading of extrasinus zygomatic implants: A prospective cohort study with a follow-up period of 8 years. *International Journal of Oral and Maxillofacial Surgery*, 41(9), 1072–1076.
- Migliorança, R. M., et al. (2008). Comparative study on the stress dissipation of zygomatic fixtures installed internal or external to the maxillary sinus: A 3D finite element method analysis. *ImplantNews*, 6(4), 395–402.
- Aparicio, C. (2011). A proposed classification for zygomatic implant patient based on the zygoma anatomy guided approach (ZAGA): A cross-sectional survey. *European Journal of Oral Implantology*, 4(3), 269–275.
- De Rossi, M., et al. (2014). All-on-four® fixed implant support rehabilitation: A masticatory function study. *Clinical Implant Dentistry and Related Research*, 16(4), 594–600.
- De Rossi, M., et al. (2017). Masticatory muscle activity evaluation by electromyography in subjects with zygomatic implants. *Medicina Oral, Patología Oral y Cirugía Bucal*, 22(3), e392–e397.
- Vrielinck, L., Blok, J., & Politis, C. (2022). Survival of conventional dental implants in the edentulous atrophic maxilla in combination with zygomatic implants: A 20-year retrospective study. *International Journal of Implant Dentistry*, 8(1), 27.
- Barausse, C., et al. (2024). Anatomical measurements of the malar bone for safe zygomatic implant placement: A study on donated bodies. *Journal of Clinical Medicine*, 13(22).
- Chrcanovic, B. R., Pedrosa, A. R., & Neto Custodio, A. L. (2013). Zygomatic implants: A critical review of the surgical techniques. *Oral and Maxillofacial Surgery*, 17(1), 1–9.
- Bedrossian, E., et al. (2002). The zygomatic implant: Preliminary data on treatment of severely resorbed maxillae. *The International Journal of Oral & Maxillofacial Implants*, 17(6), 861–865.
- de Araujo Nobre, M., Malo, P., & Goncalves, I. (2015). Evaluation of clinical soft tissue parameters for extramaxillary zygomatic implants and conventional implants in all-on-4 hybrid rehabilitations. *Implant Dentistry*, 24(3), 267–274.
- Davo, R., & David, L. (2019). Quad zygoma: Technique and realities. *Oral and Maxillofacial Surgery Clinics of North America*, 31(2), 285–297.
- Hansson, S., & Halldin, A. (2012). Alveolar ridge resorption after tooth extraction: A consequence of a fundamental principle of bone physiology. *Journal of Dental Biomechanics*, 3, 1758736012456543.
- Zoabi, A., et al. (2022). 3D printing and virtual surgical planning in oral and maxillofacial surgery. *Journal of Clinical Medicine*, 11(9).

- Aparicio, C., & Antonio, S. (2020). Zygoma anatomy-guided approach “Scarf graft” for prevention of soft tissue dehiscence around zygomatic implants: Technical note. *The International Journal of Oral & Maxillofacial Implants*, 35(2), e21–e26.
- Grecchi, F., et al. (2017). A new surgical and technical approach in zygomatic implantology. *Oral Implantology*, 10(2), 197–208.
- Bedrossian, E., et al. (2023). Zygoma implant under function: Biomechanical principles clarified. *International Journal of Implant Dentistry*, 9(1), 15.
- Bedrossian, E., & Bedrossian, E. A. (2018). Prevention and the management of complications using the zygoma implant: A review and clinical experiences. *The International Journal of Oral & Maxillofacial Implants*, 33(5), e135–e145.
- Bedrossian, E., & Bedrossian, E. A. (2019). Systematic treatment planning protocol of the edentulous maxilla for an implant-supported fixed prosthesis. *Compendium of Continuing Education in Dentistry*, 40(1), 20–25.
- Cidade, C. P., et al. (2014). Photoelastic analysis of all-on-four concept using different implant angulations for maxilla. *Brazilian Oral Research*, 28.
- Grossi, J. R. A., et al. (2023). Digital planning and printed guides for zygomatic implants. In F. Andretti (Ed.), *Brazilian Digital Dentistry Society Book*.
- Reychler, H., & Olszewski, R. (2010). Intracerebral penetration of a zygomatic dental implant and consequent therapeutic dilemmas: Case report. *The International Journal of Oral & Maxillofacial Implants*, 25(2), 416–418.
- Van Camp, P., et al. (2018). Intraorbital hemorrhage following a secondary intervention at integrated zygomatic implants: A case report. *International Journal of Surgery Case Reports*, 43, 21–24.