



COVID-19: PULMONARY INVOLVEMENT FROM CHEST CT SCANS IN INFECTED PATIENTS IN A MUNICIPALITY IN THE SOUTH OF SANTA CATARINA

Catarine Wiggers de Campos¹, Maurice Prätzel Ellwanger², Manuela Pozza Ellwanger³, Fabiley by Wite Diogo⁴, Liz Andréa Babireski Braz de Oliveira⁵, Carolina Marques de Avellar Dal-Bo⁶, Debora Reinert⁷, Camilla Melotti Berkembrock⁸, Águida Vita de Souza Diogo⁹, Antônio Carlos Mattar Munhoz¹⁰ and Chaiana Esmeraldino Mendes Marcon¹¹

ABSTRACT

The study evaluated lung involvement in 332 patients diagnosed with COVID-19 through chest CT scans, analyzing its association with clinical manifestations between March 2020 and June 2021. The results showed that most patients were male, with symptoms such as cough and myalgia predominant, and 3.9% of cases resulted in death, especially among the elderly.

Keywords: COVID-19, Computed tomography.

¹ University of Southern Santa Catarina – Santa Catarina

² University of Contestado – UNC - Santa Catarina

³ University of Contestado – UNC - Santa Catarina

⁴ University of Contestado – Santa Catarina

⁵ University of Contestado – Santa Catarina

⁶ University of Southern Santa Catarina – Santa Catarina

⁷ University of Contestado – Santa Catarina

⁸ University of Southern Santa Catarina – Santa Catarina

⁹ University of Contestado – Santa Catarina

¹⁰ Dr.

University of Contestado – Santa Catarina

¹¹ Dr.

University of Southern Santa Catarina – Santa Catarina

INTRODUCTION

The Coronavirus that causes Severe Acute Respiratory Syndrome 2 (SARS-CoV-2) is a virus first identified in Wuhan, China, at the end of 2019. The disease caused by this etiological agent was named COVID-19 and, in March 2020, declared a pandemic by the World Health Organization (WHO)¹. The most common sites of infection are the airways and evidence indicates that the damage caused is mainly linked to some types of pneumocytes that have Angiotensin-Converting Enzyme II in their membranes, serving as a receptor for binding to the spike glycoprotein of the virus².

Thus, the severity of the pulmonary impairment caused is closely linked to the severity of the infection, leading to more important dyspnea, pulmonary injuries associated with pneumonia, and Severe Acute Respiratory Syndrome (SARS) with diffuse alveolar damage (DAD), diffuse alveolar microvascular occlusion, and airway inflammation through inflammatory mediators, which can be fatal or lead to sequelae due to permanent damage to the airways^{3,4,5}element.

In this sense, computed tomography (CT) exams are important in the detection of lung lesions related to pneumonia, which is indicated in COVID-19, helping in the management and treatment when the diagnosis is confirmed and the pattern of respiratory symptoms worsens. CT is an important test to show the evolution and progression of the disease^{6,7}. Although it has already been pointed out as important to establish a diagnosis in cases with negative RT-PCR⁸. CT is currently not recommended for diagnosis or screening of COVID-19, according to the American and Brazilian Colleges of Radiology^{7,9}.

Therefore, the present study aimed to evaluate the degree of pulmonary involvement based on chest tomography of patients diagnosed with COVID-19 in a municipality in the south of Santa Catarina and its association with the clinical manifestations of the patients;

METHODS

An observational cross-sectional study was conducted. The study population consisted of 332 patients diagnosed with COVID-19 by RT-PCR, rapid test with antibody detection, antigen test by nasal swab, serological test with antibody detection, or clinical-epidemiological criteria who underwent chest tomography exams on an outpatient basis from March 2020 to June 2021, the results of which were found in the records of a municipality in the south of Santa Catarina.

Patients over 18 years of age who were notified and confirmed with COVID-19 by the municipality and who underwent chest tomography exams at the outpatient level available in the municipality's records were included. Patients who did not have their CT scans

reported or incompletely reported and whose absence of variables compromised the outcome of the study were excluded from the study.

Information on the profile such as gender, age and comorbidities and symptomatological characterization of the individuals at the time of notification were collected. Data regarding symptoms and comorbidities were self-reported by the patients.

Table 3. Association of gender, age group, and outcome with pulmonary involvement in patients with COVID-19 who underwent chest CT scans between March 2020 and June 2021 in a city in the south of Santa Catarina.

	No involvement	1-25%	26-50%	51-75%	> 76%	P-value
By age group, in years (n= 308)						0,04
20-29	14,60%	5,00%	5,40%	4,80%	0,00%	
30-39	6,30%	11,30%	15,40%	7,10%	0,00%	
40-49	41,70%	37,50%	23,10%	33,30%	12,50%	
50-59	25,00%	23,80%	26,20%	19,00%	25,00%	
60-69	8,30%	12,50%	15,40%	21,40%	62,50%	
70-79	4,20%	8,80%	12,30%	11,90%	0,00%	
> 80	0,00%	1,30%	2,30%	2,40%	0,00%	
By sex (n=308)						0,02
Male	31,30%	57,50%	56,20%	57,10%	37,50%	
Female	68,80%	42,50%	43,80%	42,90%	62,50%	
Outcome (n=306)						0,04
Cured	100,00%	98,80%	96,90%	90,50%	87,50%	
Death	0,00%	1,30%	3,10%	9,50%	12,50%	

All CT scans were performed using the xxxx tomography machine, The methods of obtaining the images were single-series, volumetric acquisition, helical and multislice acquisition, without contrast, and the pulmonary involvement was analyzed virtually by 5 physicians with the title of specialist in Radiology and Diagnostic Imaging.

The study followed the precepts of Resolution No. 466 of 2012 of the National Health Council, with the authorization of the institutions involved and having been approved by the Research Ethics Committee (CEP) of UNISUL, under opinion 4.826.202, on 07/05/2021.

The data were collected, organized and compiled in a database in an Excel® spreadsheet.

The biostatistical process and analysis were performed using the Statistical Package for the Social Sciences (SPSS)® version 20.0 for Windows. Quantitative variables were described as measures of central tendency and data dispersion. Qualitative variables were described in absolute numbers and proportions. To verify the association between the variables of interest, the Chi-square test was applied to compare the proportions. The level of significance was set at 5% ($p \leq 0.05$).

RESULTS

The present study analyzed chest CT scans and profiles of 332 patients confirmed with COVID-19 from March 2020 to June 2021. Of these, 50.9% were male and 49.1% were female, with a mean age of 52.02 years, $SD \pm 13.94$, ranging from 21 to 87 years. At the time of notification of these patients, the symptoms most frequently reported by them were, respectively: cough (51.5%), myalgia (47%), headache (40.2%), and 13.2% of the patients were asymptomatic at the time of notification. In addition, it was evidenced that 58 (19.2%) patients required hospitalization in the ward and 20 (6.6%) in the ICU, representing a total of 25.8% of hospitalized patients out of a total of 302 patients. Regarding the outcome, deaths represented 3.9% of the population studied, and 61.5% of these were 60 years of age or older, as shown in Table 1.

Table 1. Profile of patients who underwent chest tomography confirmed with COVID-19 between March 2020 and June 2021 in a city in the south of Santa Catarina.

Variables	N (%)
Gender (n=332)	
Female	163 (49,1%)
Male	169 (50,9%)
Reported symptoms	
Cough (n=295)	152 (51,5%)
Myalgia (n=296)	139 (47%)
Headache (n=296)	119 (40,2%)
Fever (n=311)	77 (24,8%)
Fatigue (n=296)	62 (20,9%)
Sore throat (n=294)	48 (16,3%)
Diarrhoea (n=296)	37 (12,5%)
Rinorreia (n=294)	36 (12,2%)
Ageusia (n=292)	34 (11,6%)
Nausea (n=296)	32 (10,8%)
Dyspnea (n=312)	32 (10,3%)
Anosmia (n=294)	28 (9,5%)
Chest pain (n=294)	15 (4,5%)
Tearing (n=295)	15 (5,1%)
Difficulty swallowing (n=289)	11 (3,8%)
Expectoration (n=296)	4 (1,4%)
Reported comorbidities (n=167)	
Cardiovascular diseases	44 (26,3%)
Diabetes Mellitus	13 (7,8%)
Obesity	3 (1,8%)
Lung diseases	6 (3,6%)
Immunosuppressive diseases	13 (7,8%)
Other diseases	11 (6,6%)
Hospitalization (n=302)	
No hospitalization	224 (74,2%)
Infirmery	58 (19,2%)
ICU	20 (6,6%)
Outcome (n=330)	
Cured	317 (96,1%)
Death	13 (3,9%)

Patients with comorbidities accounted for 40.1%, however, comorbidities were underreported items, with almost 50% of these data absent from the notification forms. The most reported comorbidities were cardiovascular diseases (26.3%) and DM (7.8%), as shown in Table 1.

With regard to CT scans, the mean time between symptom onset and CT was 13.24 days, and there was an association between the interval of days between symptom onset and CT scan and the severity of the disease ($p=0.01$). Of the total number ($n=332$), 85.5% had abnormalities in their chest CT scans, whereas 14.5% (48) had normal-looking CT scans. The main characteristic alterations were bilateral pulmonary involvement (82.5%), presence of ground-glass opacities (78.9%), intra- and interlobular septal thickening (75%), and fibroatelectasis (62%), followed by consolidations (4.8%), as shown in Table 2. There was an association between pulmonary involvement and patients with ground-glass opacities ($p<0.001$), consolidation ($p=0.32$), intra- and interlobular septal thickening ($p<0.001$), mediastinal lymphodons ($P=0.039$), and fibroatelectasis ($p<0.001$).

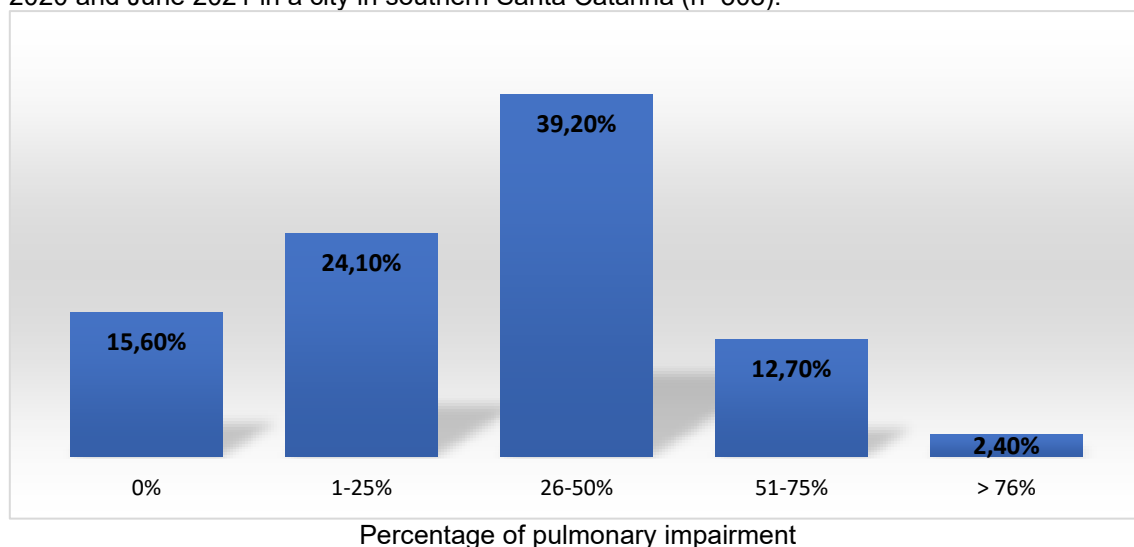
Table 2. Changes in chest CT scans in patients confirmed with COVID-19 between March 2020 and June 2021 in a city in southern Santa Catarina ($n=332$).

Sample characteristics	N (%)
Affected lung	
Right	2 (0,6%)
Left	8 (2,4%)
Both	274 (82,5%)
None affected	48 (14,5%)
Presence of inflammatory infiltrate	
Yes	2 (0,6%)
No	330 (99,4%)
Presence of nod opacity	
Yes, apical location	2 (0,6%)
Yes, later located	4 (1,2%)
No	326 (98,2%)
Presence of ground-glass opacity	
Yes, predominant location on the outskirts	262 (78,9%)
No	70 (21,1%)
Consolidation presence	
Yes, concomitant with ground-glass opacities	16 (4,8%)
No	316 (95,2%)
Presence of thickening	
Yes, intra- and interlobular	249 (75%)
Yes, subpleural	3 (0,9%)
No	90 (24,1%)
Presence of air bronchograms	
Yes	1 (0,3%)
No	331 (99,7%)
Presence of lymphodomegaly	
Yes, mediastinal	8 (2,4%)
No	324 (97,6%)
Presence of fibroatelectasis	
Yes, on a later basis	206 (62%)
Yes, apical	2 (0,6%)

No	124 (37,4)
Presence of pleural effusion	
Yes	5 (1,5%)
No	327 (98,5%)
Presence of other findings such as nodules, cysts, granulomas	
Yes	14 (4,2%)
No	318 (95,8%)
Presence of bronchiectasis	
Yes	3 (0,9%)
No	329 (99,1%)
Presence of lung bulla	
Yes	3 (0,9%)
No	329 (99,1%)
Presence of pulmonary emphysema	
Yes	6 (1,8%)
No	326 (98,2%)

The analysis of pulmonary involvement was performed virtually and was available in the reports of 308 patients. There was an average of 31.20% of pulmonary involvement caused by the disease, with 39.2% of the patients having 26 to 50% of lung involvement, as described in Figure 1.

Figure 1. Percentage of lung involvement in patients with COVID-19 who underwent chest CT scans between March 2020 and June 2021 in a city in southern Santa Catarina (n=308).

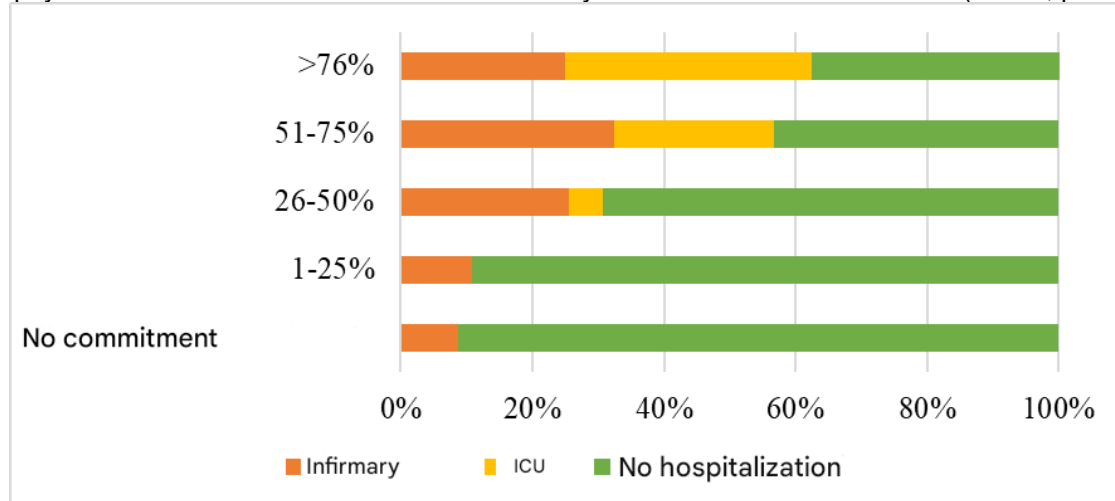


Regarding diseases, the only one that was associated with pulmonary involvement was Diabetes Mellitus 2 ($p=0.004$). There was no association with other comorbidities: obesity ($p=0.496$), cardiovascular diseases ($p=0.384$), pulmonary diseases ($p=0.228$), and immunosuppressive diseases ($p=0.250$).

When associated with the variable hospitalization, the greater the pulmonary involvement, the greater the number of people who required hospitalization. Of the patients with no involvement, 91.3% did not require hospitalization, while above >76%, only 37.7%

were not hospitalized, evidencing an association ($p<0.001$), as well as, among those hospitalized in the ICU, 66.7% of the patients had involvement greater than 51% ($p<0.001$), as shown in Figure 2.

Figure 2. Hospitalizations due to pulmonary involvement of patients with COVID-19 who underwent chest tomography between March 2020 and June 2021 in a city in the south of Santa Catarina ($n=282$; $p<0.001$).



An association was also observed in relation to the outcome ($p=0.041$). The highest mortality among the groups was in patients with more than >76% of pulmonary involvement, with 12.5% of the individuals dying. In addition, statistical significance was obtained when analyzing lung involvement with age and gender, as well as an association between age group and the presence of pleural effusion ($p=0.026$), bronchiectasis ($p=0.016$), emphysema ($p=0.005$). The full description of the associations is in Table 4.

DISCUSSION

A total of 332 CT scans of patients confirmed with COVID-19 were analyzed, obtaining a profile relatively similar to that of the analyses by Xu and collaborators and Li and collaborators, in which there is no clear predominance between the sexes. The mean age in these studies was 44.6 and 50 years, which was slightly higher in the present study^{10,11}. A study conducted by Wan et al. showed a predominance of fever and cough symptoms, while in the present study, the most common symptoms were cough, followed by myalgia, and it was also observed that fever was the 4th most reported symptom¹². This can be explained by the fact that, at the beginning of the disease, the patient may present with more atypical symptoms, and the symptoms were collected at the time of notification/initial stage of the disease.

The number of patients with comorbidities is 40% lower when compared to another study, in which 50% of the patients had comorbidities. In addition, there was an association

between involvement and diabetes, as in a previous study¹³. No statistical significance was observed between pulmonary involvement and diseases such as obesity, which was demonstrated in the study by Luo et al. as an important aggravating factor for the lesions.¹⁴ However, the pathogenesis of Diabetes Mellitus 2 is closely linked to obesity and, frequently, patients with DM have both concomitantly. It is even known that obesity is underestimated based on self-reporting, when direct measurements of weight and height are not performed¹⁵. Therefore, this can be explained by the fact that the diseases were underreported, as well as reported by the patient himself, which is a limitation of the present study.

As in the present study, others have demonstrated an association between the time of symptom onset and the extent of pulmonary involvement. As a result, some periods of evolution of COVID-19 are currently recognized: the initial stage, between 1-3 days after the onset of clinical manifestations; the progressive stage, from 3-9 days after, in which there are, between the 6th and 9th day, more obvious changes in the tomography; peak stage, with peak pulmonary manifestations between the 9th and 13th day; absorption stage, after 2 to 3 weeks, in which the onset of resolution of the condition or chronification is expected^{16,17}. In addition, the mean 31.2% of pulmonary involvement was similar to that of the study by Sapienza et al.¹⁸, and a higher rate of pulmonary involvement of 26-50% was obtained in the population when compared to the study by Mogami et al., and lower in cases of involvement greater than 50%, and it is possible to characterize the sample as having a significant involvement, although moderate.¹⁹

Among the patients hospitalized in the ICU in the present study, 66.7% of the patients had involvement greater than 51% ($p < 0.001$), a figure similar to the study by Ruch et al., which showed that 70% of the ICU patients had pulmonary involvement greater than 50%, and that, as the pulmonary involvement was lower, there was a reduction in hospitalizations²⁰. It is also noteworthy that the lethality of the disease in the present study was above the general national average in the period analyzed, of 2.78%, and also the average of the state of Santa Catarina, which is 1.56%²¹. It is also recognized that the severity of pulmonary involvement predicts clinical outcomes, as in the present study, in which pulmonary involvement was associated with the outcome^{22,23}.

The age group with the highest percentage of pulmonary involvement was those aged 40 to 49 years, except when the involvement was greater than 76%, which affected the 60 to 69 age group more, concentrating 62.5% of the affected patients ($p = 0.043$). In addition, in the present study, we observed an association between pulmonary impairment and gender. Most of the patients without pulmonary involvement were women, whereas

men remained the majority in the 1-25%, 26-51%, and 51-75% groups, with only one inversion in the group > 76%, in which 62.5% were women ($p=0.024$).

Regarding the information provided, studies carried out with animal models have shown that estrogen has a protective effect on SARS-CoV, as well as SARS-CoV-224. Thus, one of the hypotheses to justify this fact is that in the graduations of no involvement up to 75% there is a predominance of the age of 40-49 years, in which women are possibly not yet, or are in perimenopause, with the action of this hormone frequently present. When there is a change in the predominant age of those affected above 76% to 60-69 years, the population would be postmenopausal, with a very reduced action of hormone²⁵.

The main characteristics of the CT scan in the present study were a pattern of bilateral and peripheral involvement, similar to the study by Wan et al.,¹² This pattern reflects the commonly found in SARS and MERS viral infections.²⁶ In addition, 78.9% of the patients had ground-glass opacities and 75% intra- and interlobular septal thickening, which characterizes the mosaic paving pattern and one of the main characteristics of COVID-19 during the peak of the sickness.²⁷ Ground-glass opacity is described as the earliest sign of COVID-19 on CT scans, and initially, it is seen in smaller quantities, and, as the disease progresses, opacities become more diffuse and tend to appear in the mosaic paving pattern.^{11,27,28}

These lesions may evolve or coexist with consolidations between the 1st and 3rd weeks of infection, which has been shown to be a finding of 2-64% in previous studies, varying in incidence depending on the time of CT scan at the onset of symptoms, as well as whether it was analyzed together with opacities. Consolidations were present in 4.8% of the patients in the present study. This may mean that, in the present study, the patients had less chronicity of the disease. Fibroatelectasis was found in 62%, also described as one of the signs of late phase of the disease in these patients and represented a higher rate when compared to other studies^{13,27,28}. These data corroborate the fact that the mean number of days between CT scans and the onset of symptoms was 13 to 27 days, a transition between the peak of the CT manifestation and the beginning of the resolution of the condition. Other findings were rarer, such as in the metalysis of Wan et al.¹²

In addition, these arguments may also be related to the association between pulmonary involvement and patients with ground-glass opacities ($p<0.001$), consolidation ($p=0.32$), intra- and interlobular septal thickening ($p<0.001$), mediastinal lymphodons ($p=0.039$), and fibroatelectasis ($p<0.001$). Although ground-glass opacity is described as an early sign of COVID-19, it can also be found later, in the most advanced stage of the disease. Intra- and interlobular septal spstemus has been reported to be associated with

disease severity and progression, as well as consolidation, as they may lead to severe infiltration of the pulmonary interstitium and small blood vessels^{27,29}. Patients with greater aggravation also showed higher incidences of mediastinal lymph node enlargement, which may explain the finding of the present study.¹¹

Some of the limitations of the present study were that the symptoms were only reported on the day of notification and not on the day of the CT scan, making other analyses impossible, and the underreporting of the diseases. In addition, it was not possible to follow up the lesions and there is no information on other hospital parameters of severity, since these CT scans were performed on an outpatient basis.

In conclusion, the study showed that 50.9% of the patients were male, with a mean age of 52.2 years, 40.1% had comorbidities. The mean number of days of CT scan and symptom onset was 13.24, with a mean of 31.20% of insight, and there was an association between the interval of days between symptom onset and CT and the severity of the involvement ($p=0.01$). 85.5% had abnormalities in their chest CT scans, with bilateral pulmonary involvement (82.5%) and the presence of peripherally ground-glass opacities (78.9%). There was an association between pulmonary involvement and patients with ground-glass opacities ($p<0.001$), consolidation ($p=0.32$), intra- and interlobular septal thickening ($p<0.001$), mediastinal lymphodons ($p=0.039$), and fibroatelectasis ($p<0.001$), DM2 ($p=0.004$), hospitalization ($p<0.001$), outcome ($p=0.041$), age ($p=0.04$), and gender ($p=0.02$).

REFERENCES

1. American College of Radiology. (2021). *ACR recommendations for the use of chest radiography and computed tomography (CT) for suspected COVID-19 infection*. <https://www.acr.org>
2. Brazil. Ministry of Health. (2008). *Manual of care for women in climacteric/menopause*. Health Care Secretariat, Department of Strategic Programmatic Actions.
3. Brazil. Ministry of Health. (2021). *Coronavirus Brazil panel*. <https://covid.saude.gov.br/>
4. Brazilian College of Radiology and Diagnostic Imaging. (2021). *Recommendations for the use of imaging methods for patients suspected of COVID-19 infection*. <https://www.cbr.org.br>
5. Breithaupt-Faloppa, A. C., Correia, C. J., Prado, C. M., Stilhano, R. S., Oliveira, C. R., & da Palma, R. K. (2020). 17 β -Estradiol, a potential ally to alleviate SARS-CoV-2 infection. *Clinics, 75*, e1980. <https://doi.org/10.6061/clinics/2020/e1980>
6. Calabrese, F., Pezzuto, F., Fortarezza, F., Boscolo, A., Lunardi, F., Giraudo, C., & Rea, F. (2020). Pulmonary pathology and COVID-19: Lessons from autopsy. The experience of European pulmonary pathologists. *Virchows Archiv, 477*(3), 359–372. <https://doi.org/10.1007/s00428-020-02886-6>
7. Claessens, Y.-E., Debray, M.-P., Tubach, F., Brun, A.-L., Rammaert, B., Hausfater, P., & Chagnon, K. (2015). Early chest computed tomography scan to assist diagnosis and guide treatment decision for suspected community-acquired pneumonia. *American Journal of Respiratory and Critical Care Medicine, 192*(8), 974–982. <https://doi.org/10.1164/rccm.201501-0017OC>
8. Farias, L. P. G. de, Fonseca, E. K. U. N., Strabelli, D. G., Sawamura, M. V. Y., Farias, L. A. B. G. de, & Chate, R. C. (2020). Thoracic tomographic manifestations in symptomatic respiratory patients with COVID-19. *Radiologia Brasileira, 53*(4), 255–261. <https://doi.org/10.1590/0100-3984.2020.0026>
9. Kanne, J. P., Bai, H., Bernheim, A., Chung, M., Haramati, L. B., Kallmes, D. F., & Little, B. P. (2021). COVID-19 imaging: What we know now and what remains unknown. *Radiology, 299*(3), E262–E279. <https://doi.org/10.1148/radiol.2021204522>
10. Li, K., Wu, J., Wu, F., Guo, D., Chen, L., Fang, Z., & Li, C. (2020). The clinical and chest CT features associated with severe and critical COVID-19 pneumonia. *Investigative Radiology, 55*(6), 327–331. <https://doi.org/10.1097/RLI.0000000000000672>
11. Li, K., Fang, Y., Li, W., Pan, C., Qin, P., Zhong, Y., & Liu, X. (2020). Predictors of fatality including radiographic findings in adults with COVID-19. *Respiratory Research, 21*(1), 146. <https://doi.org/10.1186/s12931-020-01411-2>
12. Liu, M., Zeng, W., Wen, Y., Zheng, Y., Lv, F., & Xiao, K. (2020). COVID-19 pneumonia: CT findings of 122 patients and differentiation from influenza pneumonia. *European Radiology, 30*(10), 5463–5469. <https://doi.org/10.1007/s00330-020-06928-0>

13. Luo, X., Zhou, L., Wang, L., Gou, T., Tian, Y., & Yang, Y. (2021). Obese COVID-19 patients show more severe pneumonia lesions on CT chest imaging. **Diabetes, Obesity and Metabolism*, 23*(1), 290–293. <https://doi.org/10.1111/dom.14194>
14. Maukonen, M., Männistö, S., & Tolonen, H. (2018). A comparison of measured versus self-reported anthropometrics for assessing obesity in adults: A literature review. **Scandinavian Journal of Public Health*, 46*(5), 565–579. <https://doi.org/10.1177/1403494818761971>
15. Mogami, R., Lopes, A. J., Araújo Filho, J. A. de, Almeida, V. M. de, Lima, T. R. de, & Meirelles, G. S. P. (2021). Chest computed tomography in COVID-19 pneumonia: A retrospective study of 155 patients at a university hospital in Rio de Janeiro, Brazil. **Radiologia Brasileira*, 54*(1), 1–8. <https://doi.org/10.1590/0100-3984.2020.0071>
16. Ooi, G. C., Khong, P. L., Müller, N. L., Yiu, W. C., Zhou, L. J., Ho, J. C. M., & Tsang, K. W. T. (2004). Severe acute respiratory syndrome: Temporal lung changes at thin-section CT in 30 patients. **Radiology*, 230*(3), 836–844. <https://doi.org/10.1148/radiol.2303030853>
17. Pan, F., Ye, T., Sun, P., Gui, S., Liang, B., Li, L., & Zheng, C. (2020). Time course of lung changes at chest CT during recovery from Coronavirus Disease 2019 (COVID-19). **Radiology*, 295*(3), 715–721. <https://doi.org/10.1148/radiol.2020200370>
18. Rosa, M. E., Matos, M. J. R., Furtado, V. R. de O., Lima, Y. O., & Oliveira, R. V. C. de. (2020). COVID-19 findings identified on chest CT scan: Pictorial essay. **Einstein (São Paulo)*, 18*, eRW5741. <https://doi.org/10.1590/S1679-45082020RW5741>
19. Ruch, Y., Kaeuffer, C., Ohana, M., Ergon, M. C., Lefebvre, N., Hansmann, Y., & Danion, F. (2020). CT lung lesions as predictors of early death or ICU admission in COVID-19 patients. **Clinical Microbiology and Infection*, 26*(10), 1417.e5–1417.e8. <https://doi.org/10.1016/j.cmi.2020.07.030>
20. Sapienza, L. G., Nasra, K., Calsavara, V. F., Ranzatti, R. P., Goulart, A. C., & Vieira, G. G. (2021). Risk of in-hospital death associated with Covid-19 lung consolidations on chest computed tomography - A novel translational approach using a radiation oncology contour software. **European Journal of Radiology Open*, 8*, 100322. <https://doi.org/10.1016/j.ejro.2021.100322>
21. Tian, S., Hu, W., Niu, L., Liu, H., Xu, H., & Xiao, S.-Y. (2020). Pathological study of the 2019 novel coronavirus disease (COVID-19) through post-mortem core biopsies. **Modern Pathology*, 33*(6), 1007–1014. <https://doi.org/10.1038/s41379-020-0536-x>
22. Wan, S., Li, M., Ye, Z., Yang, C., Cai, Q., Duan, S., & Song, B. (2020). CT manifestations and clinical characteristics of 1115 patients with Coronavirus Disease 2019 (COVID-19): A systematic review and meta-analysis. **Academic Radiology*, 27*(7), 910–921. <https://doi.org/10.1016/j.acra.2020.04.033>
23. Wiersinga, W. J., Rhodes, A., Cheng, A. C., Peacock, S. J., & Prescott, H. C. (2020). Pathophysiology, transmission, diagnosis, and treatment of Coronavirus Disease 2019 (COVID-19). **JAMA*, 324*(8), 782–793. <https://doi.org/10.1001/jama.2020.12839>



24. World Health Organization. (2020). *Timeline of WHO's response to COVID-19*. <https://www.who.int/news-room/detail/29-06-2020-covidtimeline>
25. Xie, X., Zhong, Z., Zhao, W., Zheng, C., Wang, F., & Liu, J. (2020). Chest CT for typical Coronavirus Disease 2019 (COVID-19) pneumonia: Relationship to negative RT-PCR testing. *Radiology, 296*(2), E41–E45. <https://doi.org/10.1148/radiol.2020200343>
26. Xu, X., Yu, C., Qu, J., Zhang, L., Jiang, S., Huang, D., & Chen, B. (2020). Imaging and clinical features of patients with 2019 novel coronavirus SARS-CoV-2. *European Journal of Nuclear Medicine and Molecular Imaging, 47*(5), 1275–1280. <https://doi.org/10.1007/s00259-020-04735-9>
27. Xu, Z., Shi, L., Wang, Y., Zhang, J., Huang, L., Zhang, C., & Tai, Y. (2020). Pathological findings of COVID-19 associated with acute respiratory distress syndrome. *The Lancet Respiratory Medicine, 8*(4), 420–422. [https://doi.org/10.1016/S2213-2600\(20\)30076-X](https://doi.org/10.1016/S2213-2600(20)30076-X)
28. Zhang, J., Meng, G., Li, W., Shi, B., Dong, H., Su, Z., & Huang, Y. (2020). Relationship of chest CT score with clinical characteristics of 108 patients hospitalized with COVID-19 in Wuhan, China. *Respiratory Research, 21*(1), 180. <https://doi.org/10.1186/s12931-020-01440-x>
29. Zhou, S., Wang, Y., Zhu, T., & Xia, L. (2020). CT features of Coronavirus Disease 2019 (COVID-19) pneumonia in 62 patients in Wuhan, China. *AJR American Journal of Roentgenology, 214*(6), 1287–1294. <https://doi.org/10.2214/AJR.20.22975>