LUMEN ET VIRTUS

Primary endodontic lesion summarizing an endo-perio lesion

https://doi.org/10.56238/levv15n38-022

Rosana Maria Coelho Travassos[1]
Andressa Cartaxo de Almeida[2]
Diana Santana de Albuquerque [3]
Maria Alice Lopes Pereira[4]
Larissa Sousa Rangel[5]
Marcely Cristiny Figueredo Cassimiro da Silva[6]
Daniela Siqueira Lopes[7]
Priscila Prosini[8]

ABSTRACT

This study aims to present a clinical case of retreatment with the regression of an endodontic lesion, which simulated an endospinal lesion, with monthly changes of calcium hydroxide paste (UltraCal®) and preservation of the lesion repair. A 47-year-old female patient was referred for dental treatment due to the need for retreatment in elements 45 and 46. On clinical examination, the presence of a periodontal pocket fistula of more than 10 millimeters on the mesia and distal surface, respectively, was observed. Cone-beam computed tomography demonstrated the presence of filling material, as well as periapical and lateral bone radiotransparency. The retreatment was performed with rotary instrumentation (Reciproc Blue®), and the preparation of the canal with Reciproc Blue. 2.5% Sodium Hypochlorite was used as an irrigating solution, and the intracanal medication used was calcium hydroxide paste (UltraCal®) and crown sealing was done with glass ionomer cement. After 3 months, a regression of the lesion was observed, at 6 months, treatment success was observed only with endodontic therapy, without the need for periodontal treatment, confirming the diagnosis of

[1] ORCID: https://orcid.org/0000-0003-4148-1288
Profa. Dr. of the University of Pernambuco, Brazil
E-mail: rosana.travassos@upe.br
[2] ORCID: https://orcid.org/0000-0001-9896-6273
Profa. Dr. of the University of Pernambuco, Brazil
E-mail:andressa.cartaxo@upe.br
[3] ORCID: https://orcid.org/0000-0002-7897-2489
Profa. Dr. of the University of Pernambuco, Brazil
E-mail:diana.albuquerque@upe.br
[4] ORCID: https://orcid.org/0000-0001-9790-4636
University of Pernambuco, Brazil
E-mail:mariaalice.lopes13@gmail.com
[5] University of Pernambuco, Brazil
ORCID: https://orcid.org/0000-0003-0607-488X
E-mailLarissa.srangel@upe.br
[6] ORCID: https://orcid.org/0000-0003-0537-9761
Profa. Dr. of the University of Pernambuco, Brazil
E-mail:marcely.cassimiro@upe.br
[7] ORCID: https://orcid.org /0000-0002-5600-783X
Profa. Dr. of the University of Pernambuco, Brazil
E-mail: daniela.siqueira@upe.br
[8] Profa. Dr. of the University of Pernambuco, Brazil
ORCID: https://orcid.org/0000-0002-7199-0414
E-mail: priscila.prosini@upe.br

primary endodontic lesion with secondary periodontal involvement. It is concluded that endodontic retreatment associated with intracanal medication determined clinical and radiographic success, ruling out the need for periodontal therapy.

Keywords: Endoperiodontal lesions. Endodontic-periodontal lesions. Endoperium lesions. Endodontic disease.

INTRODUCTION

The diagnosis of endo-periodontal lesions often becomes a challenge, as they are usually approached as distinct alterations and each primary lesion can sometimes mimic the clinical characteristics of the other. It is essential that these injuries are addressed with thorough diagnosis, planning, and treatment, which plays a fundamental role in the success of the treatment, requiring the correct selection of materials, appropriate techniques, and meticulous monitoring (PRASHAANTHI N, et al., 2021). The treatment of endoperiodontal alterations usually begins with the disinfection of the root canal systems, followed by the time interval for the observation of the case, and later, the periodontal treatment. The clinical and radiographic aspects that characterize an endoperiodontal lesion involve: deep periodontal pockets that reach the apex, negative or altered response to pulp sensitivity tests, resorption in the apical or furcation region, spontaneous pain or pain on palpation and percussion, presence of purulent exudate, tooth mobility, sinusitis, and changes in crown and gum color.

The intact periodontium is of paramount importance in the execution of dental treatments. In case of poor periodontal health, it can evolve and lead to bone loss and loss of insertion. The interrelationship between pulp and periodontium has been extensively discussed in the literature. Above all, emphasizing the ways for the dissemination of bacteria between the pulp and periodontal tissues, there is controversy regarding the diagnosis and classification of endoperiodontal lesions (PLE), which are repeatedly raised (DOUKI; SAAD; KHARAAT, 2022).

Pulp infection can drain through the space of the periodontal ligament and give an appearance of periodontal destruction, called retrograde periodontitis (BORGES; MAZIERO, 2021). Likewise, pulp and periodontal infections can coexist in the same tooth, called combined lesions, whose treatment depends on the degree of tissue involvement. Both endodontic and periodontal diseases are caused by a mixed anaerobic infection. Therefore, it is of fundamental importance for the dental surgeon to have scientific knowledge about this etiology so that he can distinguish it, that is, of pulp and/or periodontal origin, as well as the probable communication routes between the pulp and the periodontium, in addition to the bacterial similarities. Therefore, the professional will determine the diagnosis and the choice for the appropriate treatment in cases of PLE and in the achievement of success (GAMBIN; FERRANTI; TRENTIN, 2020). To solve endodontic failures, detailed planning

of each case is necessary. The professional should use complementary methods to diagnose and obtain better predictability of the procedure to be performed, considering that they help in pulp diagnosis, recognition of internal anatomies, planning and preservation (Macedo et al., 2018).

The use of materials and equipment that qualify endodontic retreatment is a current reality, scientifically supported. These resources make it possible to achieve satisfactory clinical results in endodontic retreatments, due to the great success in cleaning and disinfecting root canals. Tooth rehabilitation with a fiber pin retainer was chosen due to its mechanical, aesthetic and functional properties, as well as to enable adequate intracanal shielding. Therefore, such allied procedures allowed the maintenance of the natural and healthy tooth in the oral cavity. (Ribeiro et al. 2022).

In view of the above, the objective of this study was to describe two clinical cases that demonstrated an endodontic lesion with secondary repercussions to the periodontium that was successful only with endodontic therapy, thus demonstrating that an accurate diagnosis must be effective in order not to compromise the result of the treatment.

Therefore, the objective of this study was to describe a clinical case simulating an endoperium lesion in which only endodontic treatment determined the clinical and radiographic success of the periapical and cortical bone lesion, without the need for periodontal treatment.

CASE REPORT

Patient A. S. R. sought a private office for dental treatment, complaining of pain in the lower region, especially when chewing. During the anamnesis, he reported no systemic disease, but he reported pain, During the intraoral clinical examination, the presence of fistula, periodontal pocket of more than 10 millimeters was observed on the mesial surface of tooth 45 and distal face of tooth 46. The patient signed the Informed Consent Form (ICF) agreeing with the proposed procedures and being aware of the risks of the treatment. It was also clarified that, after the conclusion of the case, it would be necessary to return to your dentist to perform the preparation of the prosthetic crown, as well as the follow-up of the treatment carried out to assess the cure.

After performing radiographic examination, the presence of extensive periapical bone rarefaction was observed in teeth 45 and 46 and, as previously reported, the presence of a periodontal pocket of more than 10 millimeters, it was decided to request a cone beam computed tomography. (Figure 1).

Figure 1 - CT scan showing periapical lesion and presence of alveolar bone crest



Initially, anesthesia of the inferior alveolar nerve was performed with 2% lidocaine with epinephrine 1:100,000 and infiltrative anesthesia in the root of tooth 44 with 4% articaine with epinephrine 1:100,000, after anesthesia absolute isolation was performed with rubber dam, folding Ostby's arch and gingival barrier, the staple selected was W2A. Coronary opening was performed with an FG 1014HL drill (KG Sorense). Clearsonic ultrasonic insert (Helse Ultrasonic, Santa Rosa de Viterbo, Brazil) coupled to an ultrasound device (WOODPECKER U600), followed by the use of a Reciproc® R25 mechanized instrument. The Root Canal Patency Length (CP) was achieved with the #20K manual file (Dentsply Sirona) coupled to a RomiapexTM A-15 foraminal locator (Romidan, Qiryat Ono, Israel). After determining the initial apical diameter with a manual file #20K (Dentsply Sirona), the Reciproc® Blue R40 (VDW) instrument was selected for instrumentation in 3 movements of advance and retreat at each deepening, without forcing, until reaching the pre-established measurement. Subsequently, the Reciproc® Blue R50 instrument was used for the final formatting of the canal of tooth 45 and enlarging it to the stipulated filling length of 1 mm below the apical foramen, the R40 instrument was used in the mesial canals of tooth 46. Between the passages of each instrument, there was a renewal of the irrigating solution and the use of the patency instrument. Passive ultrasonic irrigation (PUI) was used as an auxiliary method in chemical preparation with the TRI 31 insert (Dental Trinks) coupled to the ultrasound set at the lowest power. The insert was freely inserted in the measure of 3 millimeters short of the working length. During the procedure, a 2.5% NaOCl and 17% EDTA solution were used.

Filling was performed using the single cone technique associated with AH PLUS cement (Dentsply Sirona) along with the main cone F5 (50/.05; Dentsply Sirona) in tooth 45 and F4 (40/.05) in the mesial and distal canals of tooth 46. After cutting the excess gutta-percha, the obturator was compressed vertically with an Odus de Deus presser foot (Golgran). (Figure 2).

Figure 2- Filling of the radicluates canal system



The patient was referred for the preparation of a permanent prosthetic crown and advised of the need to undergo radiographic follow-up every 3 months to evaluate the clinical and radiographic repair. After this period, a reduction in the lesion of tooth 44 and complete resolution of the medullary bone of tooth 45 were observed, with the reestablishment of the alveolar bone crest and, clinically, absence of signs and symptoms, such as fistula and periodontal pocket. (Figure 3)

Figure 3- 3-month control X-ray

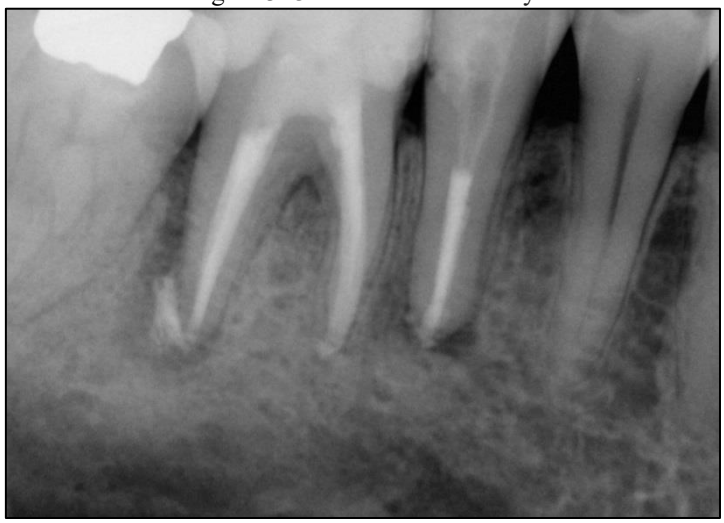

After the 6-month period, treatment success was observed only with endodontic therapy, without the need for periodontal treatment, confirming the absence of endoperiodontal interrelationship. Often, these lesions contain challenges that can hinder the clinician in terms of diagnosis and prognosis, as each primary lesion can sometimes mimic the clinical features of the other alteration. These follow-ups in short periods of time, confirm the diagnosis of primary endodontic lesion with secondary periodontal involvement, which determined after endodontic retreatment, complete resolution of the apical and lateral radiotansparental bone structure, that is, peripical and lateral bone neoformation and formation of the alveolar bone crest in the

aforementioned teeth, did not require periodontal therapy that could destroy healthy periodontal fibers. (Figure 3)

Figure 4- 6-month control radiograph

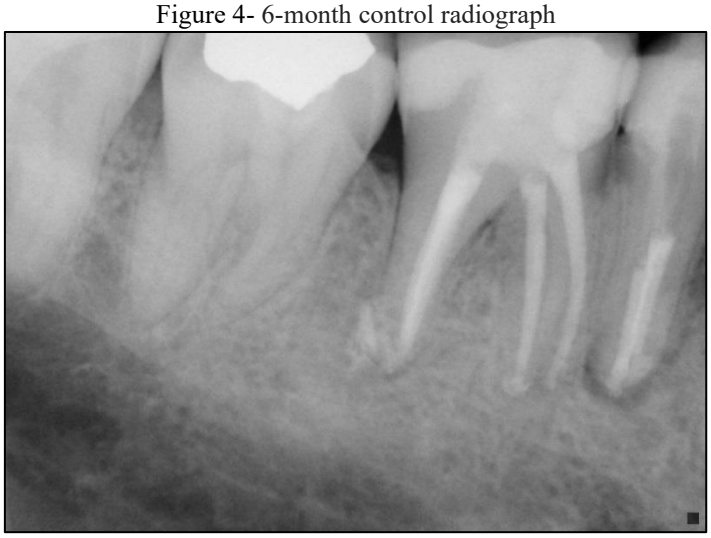

DISCUSSION

The use of ultrasonic inserts associated with reciprocating files and other tools are promising in root canal unfilling and infection control. Therefore, the retreatment of the teeth began with the Reciproc Blue R-25. The use of ultrasound in the various phases of endodontic treatment has been widespread among specialists, emerging as an approach aimed at simplifying and providing greater predictability to the process. On the market, several endodontic ultrasonic inserts are available, each aimed at optimizing and enhancing a specific step or need in the endodontic context. Among the many techniques for root canal unfilling associated with endodontic treatment failure, the use of Clearsonic (Helse Ultrasonic, Santa Rosa de Viterbo, Brazil) proved to be the best option for further removal of contaminated material, because its arrow-shaped convex tip allows the removal of both the filling material and the dentin that is infected. In view of this, the association with reciprocating files Reciproc R25 and R40 (VDW, Munich, GERMANY) has become the gold standard in the root canal filling protocol (De-Deus et al, 2020). According to a study conducted by AlRahabi and Att9a (2019), the Reciproc Blue® file has demonstrated remarkable effectiveness in removing filling materials from the root canal during endodontic retreatment, resulting in effective cleaning and proper preparation of the canal. These findings are consistent with the results presented by **Prado** *et al*. (2019), who also observed a high efficiency of Reciproc Blue® in removing old fillings in root canals during endodontic retreatment. In this case, it is in line with the authors, since from our clinical observation, the Reicproc Blue file stood out in its usefulness and efficiency. Corroborating the result of the present study, endodontic retreatment using the Reciproc Blue® system proved to be highly effective, reflecting the innovation and efficiency of this method in the context of dental practice. The Reciproc Blue® system provided a safe and efficient approach to the removal of filling

material and root canal infection, highlighting its potential to improve clinical outcomes and patient experience.

In addition, the use of intracanal medication is a fundamental part of an endodontic infection. Calcium Hydroxide is the most studied and used medication to help control endodontic infection. Acting by ionic dissociation of Ca+2 and OH creating a highly alkaline pH >pH=11 when associated with viscous vehicles. When used in paste form with a slow release of ions, it enables disinfection of the canal and aids in the repair of the injury. The vehicle of choice, propylene glycol, has low surface tension in relation to other viscous vehicles and lower solubility in relation to glycerin, concomitantly promoting the hydration of the structures that are in contact with the paste (Pereira et al., 2018).

After the completion of endodontic retreatment, there is a need for an adequate coronary seal to avoid recontamination of the root canal system and to reestablish the masticatory functions of the dental element. The need for its use will be based on parameters that include the position of the tooth in the arch, the patient's occlusion, the function of the tooth, the configuration of the canal and the amount of coronary walls lost. In this case, we opted for the manufacture of a fiber pin, since this form of reconstruction has the advantage of being placed immediately after the conclusion of the treatment, reducing the number of clinical sessions because it does not involve laboratory procedures, which thus hinders the chance of recontamination of the endodontic treatment.

In cases of endodontic reinterventions, it is considered necessary for the operator to have scientific knowledge and manual skill to perform the necessary operative steps, which has a greater learning curve. Factors such as a good prognosis, longevity of the treatment and above all the health and function of the tooth in question must be achieved. In this same context, all therapy should be evaluated in its preservation for final confirmation of success in endodontic treatment. Therefore, it is important to note that endodontic treatment does not end with its filling, but after the minimum period of preservation ranging from 6 to 12 months (Travassos et al. 2023)

REFERENCES

Aljasser, R., et al. (2021). Regenerative therapy modality for treatment of true combined endodontic-periodontal lesions: A randomized controlled clinical trial. International Journal of Environmental Research and Public Health, 18(12), 6220. https://doi.org/10.3390/ijerph18126220

Borges, E. C. C., & Maziero, L. F. M. (2021). Endoperiodontal lesions: Classification and diagnosis. PECIBES, 7(2), 57-63. ISSN-2594-9888

Chapola, R. S. (2021). Avaliação do efeito da terapia endodôntica e periodontal frente ao conteúdo infeccioso em dentes com polpas necrosadas, comprometidos pela doença periodontal crônica (Doctoral thesis, Universidade Estadual de Campinas).

Douki, N., Saad, A., & Kharaat, I. (2022). Endodontic periodontal lesions: Better understanding for better management. Medicon Dental Sciences, 1(1), 07-11.

Gambin, D. J., & Cecchin, D. (2018). Aspectos clínicos e radiográficos das lesões endoperiodontais: Uma revisão de literatura. Brazilian Journal of Periodontology, 18(3), 53-58.

Gambin, D. J., et al. (2020). Etiologia das lesões endoperiodontais - Uma visão para o diagnóstico clínico: Uma revisão de literatura. Brazilian Journal of Periodontology, 30(3), 01-10.

Macedo, I. L. de, & Neto, I. M. (2018). Retratamento endodôntico: Opção terapêutica do insucesso endodôntico. Brazilian Journal of Health Review, 1(2), 421–431.

Nogueira, G. S., et al. (2022). A importância do criterioso exame clínico e radiográfico no diagnóstico diferencial das lesões endoperiodontais e lesões endodônticas: Relato de caso. Brazilian Journal of Surgery and Clinical Research, 41(1), 54-58.

Prashaanthi, N., et al. (2021). Prevalência de lesão endo perio - Um estudo institucional. Revista Internacional de Odontologia e Ciência Oral, 8(6), 2858–2862.

Queiroz, G. I., et al. (2022). Tratamento de lesão endo-perio. Ibero-Americana de Humanidades, Ciência e Educação, 8(4), 1778-1786.

Ribeiro, L. N., et al. (2022). Retratamento endodôntico associado à instalação de retentor de fibra de vidro: Relato de caso. Brazilian Journal of Development, 8(11), 73983-74001.

Ruetters, M., et al. (2021). Effect of endodontic treatment on periodontal healing of grade 3 endo-periodontal lesions without root damage in periodontally compromised patients: A retrospective pilot study. Clinical Oral Investigations, 25(4), 2373–2380. https://doi.org/10.1007/s00784-020-03522-8

Travassos, R. M. C., et al. (2022). Tomada de decisão frente às lesões de acometimento endodôntico-periodontal. Research, Society and Development, 11(13), e152111335384. https://doi.org/10.33448/rsd-v11i13.335384

Travassos, R. M. C., et al. (2023). Retratamento endodôntico com Prodesign Logic RT: Retratamento endodôntico. Brazilian Journal of Implantology and Health Sciences, 5(4), 2393-2408.

Xavier, D. N. S., et al. (2023). A inter-relação entre doença periodontal e endodôntica: Revisão de literatura. Revista Multidisciplinar do Nordeste Mineiro, 4. https://doi.org/10.5935/2178-6925