LUMEN ET VIRTUS

Literature review of: The role of magnetic resonance imaging in the imaging diagnosis of spondylodiscitis

https://doi.org/10.56238/levv15n38-081

Paulo Eduardo Hernandes Antunes[1]
Roberta Machado Mirandola Antunes[2]

ABSTRACT

Infection that affects the intervertebral disc and contiguous vertebrae is called spondylodiscitis or spondylitis. Some authors report that the terms discitis, spondyloarthritis, inflammation\ infection of the intervertebral disc space, benign vertebral osteomyelitis, nonspecific spondylitis, and pyogenic vertebral osteomyelitis refer to the same infection. Spondylodiscitis accounts for 2%-4% of all cases of skeletal infections. Its rapid diagnosis and appropriate treatment can avoid complications such as spinal cord compression, vertebral collapses, avoiding surgery. Its diagnosis is based on characteristic clinical and radiological findings, and is confirmed by biopsy of the disc or vertebra and blood cultures. Regarding the etiology, spondylodiscitis can be pyogenic, caused by several types of bacteria, or granulomatous, caused by mycobacteria, Brucella, spirochetes or fungi. The most prevalent spondylodiscitis are pyogenic and those associated with tuberculosis infection. In pyogenic spondylodiscitis, the lumbar spine is the most involved segment, followed by the dorsal and, less commonly, the cervical and sacral columns. The spine is the most common site of tuberculosis infection in the musculoskeletal system (about 50% of cases), with the low dorsal spine and the lumbar spine the most affected. The main signs suggestive of pyogenic spondylodiscitis are: segmental involvement; abscesses with poorly defined boundaries; early involvement of the intervertebral disc; homogeneous involvement of the vertebral bodies and intervertebral discs, while those of tuberculous spondylodiscitis are: abscess of thin and well-defined walls; multisegmental subligament involvement; heterogeneous involvement of the vertebral bodies; intervertebral discs relatively spared. The objective of this literature review is to present the main aspects of spondylodiscitis on magnetic resonance imaging.

INTRODUCTION

Infection that affects the intervertebral disc and contiguous vertebrae is called spondylodiscitis or spodylitis. This pathological entity is rare and affects all age groups, with a higher incidence peak in males, 2:1, and predominance in the 5th and 6th decades of life. In children, it is a difficult identity to diagnose due to nonspecific clinical and late radiological signs1. The persistence of vascularization of the vertebral plateaus, fibrous ring, and hyaline cartilage justify the appearance of this clinical entity in childhood. Children and adolescents are predisposed to infections from minor traumas that cause a small hematoma, vascular obstruction and, finally, an area of

[1] Bachelor's Degree in Medicine - Faculdades Integradas Padre Albino (FIPA) - FAMECA
[2] Graduation in Medicine from Faculdades Integradas Padre Albino (FIPA) - FAMECA

avascular necrosis. This area becomes infected by already existing bacteremia. Infectious agents target the intervertebral bodies and/or contiguous vertebral bodies through arterial segments that nourish two vertebral bodies, and by the persistence of disc vascularization. In younger children, the most common agents of pyogenic infections are: *Staphylococcus aureus, Streptococcus pyogenes, Haemophilus influenzae, Salmonellas, and E. colli* and affect more lumbar vertebrae followed by thoracic vertebrae[1,2,3]. In older individuals, this comorbidity may be predisposed by: chronic renal failure, especially under hemodialysis, diabetes mellitus, obesity (body mass index > 30 kg\m2), chronic alcoholism, liver failure, neoplasia, systemic corticosteroid therapy, or other types of immunosuppression. The incidence has increased in recent years due to the increase in other risk factors, namely the aging of the population, intravenous toxicophilia and the routine use of epidural and vascular catheters for therapy. The most frequent etiologic agents of this entity in the pyogenic form and in older individuals are: *Staphylococcus aureus (50%-84%),* however other microorganisms frequently isolated are *Escherichia coli and Proteus spp* in the presence of urinary tract infections, *Pseudomonas aeruginosa, Klebsiella ssp* and other gram-negative bacteria in intravenous toxicophilia.

In the case of etiology by non-pyogenic germs, the most common agents in younger children are: mycobacteria, brucellosis, syphilis and various fungi. *Brucella* infection is related to contact with infected cattle and their products. In older children (more than 3 years of age) and adults, the main etiological factors of non-pyogenic spondylodiscitis are: *Mycobacterium tuberculosis (*vast majority), *Cryptococcus ssp, Aspergilus ssp, Coccidiodes ssp.* The most common location of extrapulmonary tuberculosis is bone, with spinal involvement in 50% of cases.

Clinical manifestations vary and can be abrupt or subacute, depending on the body's reaction, the capacity of the immune response, and the age of the host[1,3]. Pain related to the affected segments and painful hypersensitivity are the most common symptoms at all ages[1-3,6]. In small children, it is common to have a refusal to walk or a tripod posture (to support oneself on three limbs)[1.] The inability to flex the lumbar spine and the loss of lumbar lordosis are common signs[2]. Neurological manifestations include paraparesis, paraplegia, and meningitis. The prevalence of this type of manifestation can reach up to 60% of cases, especially when the etiology is tuberculosis or *Staphylococcus2.* The time interval between the onset of symptoms and diagnosis is three weeks to three months.

More than 50% of patients do not have fever or leukocytosis, and there is only an increase in sedimentation rate (ESR), which normalizes with effective therapy[1,3,6].

The spine represents 50% of all osteoarticular locations of tuberculous infection, as reported above. Its incidence is inversely proportional to the socioeconomic level of the country[6]. Hematogenous dissemination occurs secondarily, from a primary lung infection[1], with subsequent

local reactivation. Radiographic evidence of pulmonary tuberculosis at the time of diagnosis is present in less than 50% of cases[1]. A negative Mantoux reaction does not exclude bone tuberculosis[1].

Given the variability of pathogenic agents, blood cultures and bacteriological examination of the sample collected by local biopsy are essential for specific and targeted treatment[2]. Bacteriological examination of sputum and urine culture should also be performed, especially in the case of suspected *Mycobacterium tuberculosis*[2] *spondylodiscitis*. Blood cultures are a minimally invasive bacteriological test that is easy to obtain, but their positivity is about 35% of cases. When positive, antibiotic therapy can be according to the antibiogram of the isolated agent, without the need for more invasive techniques. On biopsy, positive results are obtained in a slightly higher percentage (53%)[2].

DISCUSSION - DIAGNOSTIC IMAGING METHODS

RX-SINGLES

Plain x-rays - in the early\early stage (1-3 weeks) the x-ray may be normal. The first radiological signs include subchondral hypotransparency followed by blurring of the plateaus and reduction in the height of the disc space, and consequently by bone marrow destruction of the adjacent vertebra. Findings of bone destruction secondary to osteomyelitis are not seen until 35% to 40% of the involved region is destroyed[3]. Finally, bone sclerosis occurs. Kyphosis, scoliosis, or both are a consequence of 4 to 6 months of chronic infection[3]. In tuberculous spondylodiscitis, in addition to these radiographic findings, areas of fusiform enlargement of the paraspinal soft tissues are frequently observed, denoting the formation of abscesses (in more than 70% of cases in association with epidural extension)[3]. Lateral radiographs may demonstrate erosion of the anterior margin of the vertebral body as a consequence of subligamentous extension[3]. The abscesses may present foci of calcification, pathognomonic of tuberculosis[3].

CT SCAN

CT scan- Effacement of paravertebral fat and hypodensity of the intervertebral disc may be visible early in the infection. Throughout the progression of the disease, erosion of the platforms and bone destruction of the vertebral bodies can be identified. After contrast injection, paravertebral abscesses such as psoas abscesses can be easily identified, in addition to peripheral enhancement of the epidural abscess, which causes posterior displacement of the dural sac, invasion of the spinal canal, and spinal cord compression[3]. In tuberculous spondylodiscitis, the cloaca can be seen, resulting from the drainage of intraosseous abscesses. Tuberculous spinal abscesses may drain to other planes with development of mediastinal abscesses, pleural effusions, flank abscesses, and psoas, depending on the level and direction of spread. In the chronic phase of tuberculous

spondylodiscitis, there is extensive bone destruction, formation of bone sequestration, and marked formation of heterotopic bone [3]. CT-guided biopsies are useful for identifying the etiologic agent.

Figure 1A and 1B - 61-year-old male with low back pain, fever and paresis, showing in contrast-enhanced CT scans: hypodensity of the intervertebral disc, with plateau irregularities and sclerosis of the L4-L5 plateaus. Blood culture positive for Staphylococcus aureus



NTILOGRAPHY

Bone scintigraphy - Increased radiopharmaceutical uptake reflects inflammatory activity and increased bone turnover, and is visible 1 to 3 weeks before there is manifestation on radiographs and CT. The main radioisotopes used are gallium and technetium 99m, with gallium being indicated for follow-up and technetium for initial diagnosis. During the curing phase, gallium may become negative, but technetium remains positive after a long time[4].

MAGNETIC RESONANCE IMAGING

Magnetic Resonance Imaging - is currently the imaging test of choice in the diagnosis of spondylodiscitis, especially in the very early stages of the disease when the rest of the tests are still negative. Contrast-enhanced MRI allows the differentiation of fibrous tissue abscesses, evaluates intraspinal extension, spinal cord compression, focal myelopathy, meningeal disease, and spinal extension[4,5]. It typically shows hyposignal on T1-weighted images with loss of definition of vertebral

plateaus and adjacent vertebral bodies [27], loss of disc height and soft tissue mass for spinal[3]. On T2-weighted sequences, there is hypersignal of the disc, vertebral bodies, and soft tissues involved. In pyogenic and hematogenous spondylodiscitis, there is a homogeneous increase in disc signal on sagittal T2-weighted images with loss of normal nuclear cleft[3]. Using intravenous contrast (gadolinium) it is possible to evaluate the enhancement of the structures involved in the process. Disc enhancement patterns can range from no disc enhancement, homogeneous enhancement of the majority of the disc, irregular non-confluent areas of enhancement, to thin or thick areas of peripheral enhancement.

In tuberculous spondylodiscitis, MRI increases the detection of vertebral intraosseous abscesses, skipped lesions, subligamentous and epidural extension of the infection [3]. Mycobacteria tend to spare the intervertebral disc in early stages. This type of infection is characterized by large paravertebral lesions disproportionate to bone destruction. After intravenous contrast, there is peripheral and thick enhancement of intraosseous and spinal abscesses[3,5,6].

Other conditions make a differential diagnosis with spondylodiscitis, among which we can mention spinal neoplastic diseases, compression fractures, discogenic vertebral alterations in the inflammatory phase (Modic type I), destructive spondyloarthropathy seen in chronic kidney patients undergoing hemodialysis for long periods, seronegative spondyloartopathy and spinal neuroarthropathies[3].

Inflammatory spondylodiscitis, such as ankylosing spondylitis, psoriatic and reactive spondylitis, may present alterations similar to those of degenerative spondylitis. However, vertebral involvement is typically accompanied and sometimes preceded by bilateral sacroiliitis, which can be symmetrical or asymmetrical, depending on each etiological origin[3,4.]

Metastatic lytic neoplastic lesions to the axial skeleton are usually not accompanied by reactive sclerosis or periosteal reaction, in addition to the typical involvement starting in the vertebral pedicles[3,4].

Degenerative spondylodiscitis can, like infectious cases, course with enhancement of the intervertebral disc in the post-gadolinium sequences. However, the vertebral plateaus affected tend to present hyposignal on T2-weighted sequences and do not suffer enhancement after intravenous gadolinium injection[4,5,6.]

Sagittal images of MRI 2A, 2B and 2C correspond to contrast-enhanced T1-weighted, T2-weighted and contrast-enhanced T1-weighted images of a 65-year-old woman with low back pain and reduced sensitivity of the lower limbs, showing: involvement of the T8-T10 segment, with lesion with hyposignal on T8-T9 and T9-T10, hypersignal on T2-weighted sequences of the intervertebral disc of T8-T9, and with enhancement and irregularities of the vertebral plateaus affixed to T8-T9. Sputum positive for AFB.

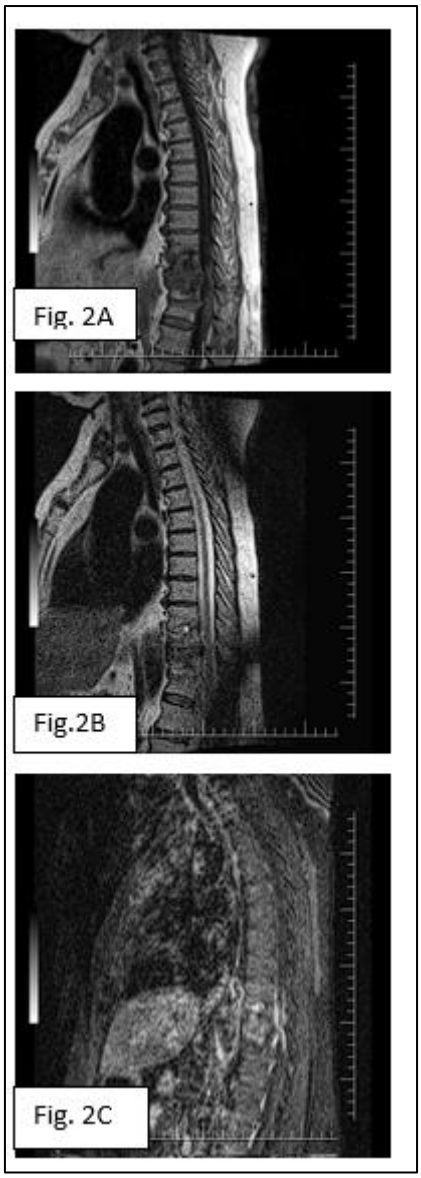

CONCLUSION

In the various articles reviewed, all authors choose magnetic resonance imaging as the imaging method of choice for the diagnosis of spondylodiscitis, because it can control the evolution of the disease, demonstrate the involvement of the intervertebral discs, the extent of the pathology, as well as suggest the etiological agents. After MRI, bone scintigraphy, tomography and, finally, conventional radiography, which requires further evolution of the disease to suggest this diagnosis, are used as the method of choice.

REFERENCES

Espada, F. V., Costa, P. M., Leite da Cunha, A., Sarmento, A., Mesquita Montes, J., & Cruz, M. E. (2003). Espondilodiscite. Acta Medica Portuguesa, 16, 279–284.

Faria, R., Borges, C., Carrondo, H., & Banza, M. J. (2011). Espondilodiscite: Que etiologia? Acta Médica Portuguesa, 24, 1059–1064.

Duarte Lessa, L. A., Aihara, A. Y., Natour, J., & Fernandes, A. R. da R. C. (2004). Diagnóstico por imagem nas espondilodiscites infecciosas. Revista Brasileira de Reumatologia, 44(3), 165–175. https://doi.org/10.1590/S0482-50042004000300003

Souza, C. G. de, Gasparetto, E. L., Marchiori, E., & Valle Bahia, P. R. (2013). Espondilodiscites piogênica e tuberculosa: Aspectos na ressonância magnética para o diagnóstico diferencial. Radiologia Brasileira, 46(3), 179–186. https://doi.org/10.1590/S0100-39842013000300003

Genta, P. R., Cigna, A. C., Meirelles, L. P., & al. (2000). Bacterial spondylodiscitis. MedGemMed, 2(1), 1–8.

Mann, S., Schutze, M., Sola, S., & al. (2004). Nonspecific pyogenic spondylodiscitis: Clinical manifestations, surgical treatment, and outcome in 24 patients. Neurosurgical Focus, 17(6), E3. https://doi.org/10.3171/foc.2004.17.6.3