LUMEN ET VIRTUS

Amyloidosis related to monoclonal B-lymphocyte dyscrasia: A systematic and epidemiological view

https://doi.org/10.56238/levv15n38-057

Silvio Stafi Filho[1]
Isabelli Combi[2]
Marianna Azevedo da Silva Queiroz[3]
Kezia Ribeiro Venâncio Chueng[4]
Warley da Silva Chueng[5]
Ketlin Jabs Schütz[6]
Mateus Oliveira Araujo[7]
Artur da Rocha Oliveira[8]
Kevyn Murillo Silva Bitencourt[9]
Whelinton Alves Rolim de Souza[10]

ABSTRACT

Amyloidosis caused by monoclonal dyscrasia of B lymphocytes is a complex and severe disease, characterized by the progressive accumulation of amyloid material resulting from the incorrect folding of immunoglobulin light chains κ or λ, which are deposited in tissues. It is a pathology that can manifest itself systemically or locally, depending on the level and location of the accumulation, being more serious and prevalent in vital organs, such as the heart and kidneys. Clinically, patients present with a variety of generic signs, including edema, renal and cardiac dysfunction, and as the level of accumulation progresses, the characteristic signs of the disease, such as macroglossia, periorbital purpura, and changes in skin texture, become evident and aid in the presumptive diagnosis. However, the effective diagnosis of AL amyloidosis is complex, based on clinical observation and confirmed by auxiliary diagnostic methods, the most effective being local biopsy, together with Congo red staining, which is particularly sensitive to this type of accumulation, with the ability to birefringence under polarized light, showing amyloid accumulations of greenish-brown

[1] Medical student, Central University of Paraguay.
ORCID: 0000-0002-7355-3904
[2] Medical Student, Central University of Paraguay.
ORCID: 0000-0002-2693-8668
[3] Medical Student, Central University of Paraguay.
ORCID: 0009-0004-06029135
[4] Medical Student, Central University of Paraguay.
ORCID: 0009-0004-5778-8422
[5] Medical Student, Central University of Paraguay.
ORCID: 0009-0003-0266-2809
[6] Medical Student, Central University of Paraguay.
ORCID: 0009-0007-3107-3463
[7] Medical Student, Central University of Paraguay.
ORCID: 0009-0001-1399-4505
[8] Medical Student, Central University of Paraguay.
ORCID: 0000-0003-0086-1444
[9] Medical Student, Central University of Paraguay.
ORCID: 0000-0002-9433-2051
[10] Medical Student, Central University of Paraguay.
ORCID: 0009-0002-5507-9855

amyloid. The research used the bibliographic methodology, searching the literature of the last five years in databases such as PUBMED and Google Scholar. The data collected show the heterogeneity of the disease and its high prevalence and incidence in countries with developed health systems, which contrasts with the difficulty of diagnosis and treatment in less developed regions. The study highlights the urgent need to develop more effective treatments and new therapeutic approaches to combat the progression of the disease, which continues to have a high mortality rate and a significant impact on patients' quality of life.

Keywords: Protein misfolding, Diagnosis of amyloidosis, Systemic complications, Macroglossia, κ and λ chains.

INTRODUCTION

Amyloidosis is a pathological condition characterized by the abnormal deposition of insoluble amyloid fibrils in tissues[1,2]. These fibrils are composed of hyaline protein material, resulting from inadequate protein folding, and a non-fibrillar component, serum amyloid P-pentraxin3. It is heterogeneously distributed throughout the body, manifesting itself in specific amyloid subtypes, depending on the nature of the precursor protein of the unfolding4.

This disease can be triggered by a gammopathy resulting from a monoclonal dyscrasia of B lymphocytes[4]. In it, massive replication of an affected progenitor cell occurs, producing other cloned cells with the same mild immunoglobulin cell duplication defect, leading to excessive production of the affected cell[4,5].

This characterizes AL amyloidosis, a rare and progressive disease that occurs due to the extracellular deposition of amyloid fibrils in the body[6]. This accumulation of proteins is specifically composed of immunoglobulin κ or λ 4 light chains. These amyloid deposits compromise the normal physiology of tissues and tend to accumulate mainly in vital organs with terminal circulation, such as the kidneys and heart, leading to severe dysfunctions[7,8,9].

This pathology manifests itself in two different ways: as a systemic disease or as a localized disease. The systemic form, initially called "primary", is the most common and also the most severe of this type of amyloidosis[4]. The disease varies greatly from patient to patient and can affect almost all organs except the brain, often leading to serious complications[3,4,10]. Localized AL amyloidosis, on the other hand, manifests at specific sites, taking on a nodular or confluent appearance. Although this disease can cause severe hemorrhages, these deposits are classified as benign and constitute the mildest form of the disease[3,4].

Clinically, patients diagnosed with AL amyloid present with a variety of general symptoms, such as edema, renal or cardiac dysfunction, and neuropathies, which vary according to the organ involved[3, 11]. Therefore, a detailed clinical examination is essential to detect AL amyloidosis, looking for characteristic evidence of the disease, such as macroglossia, periorbital purpura, and changes in skin texture[3]. However, the diagnosis based only on the search for and observation of symptoms and

signs may not be conclusive, since these indicators may be similar to those of several other pathologies and vary according to the extent of amyloid deposits[1,4].

Although clinical signs are important, they should be evaluated in conjunction with auxiliary diagnostic methods, such as local biopsy, which is the most recommended and conclusive way to confirm amyloidosis, as it is able to microscopically identify fibrillar deposits of amyloid in the tissue, which tend to be deposited initially in the subendothelial region of the vessels and, As amyloid material accumulates, it expands into the stroma, adopting the specific configuration of the affected organ[2,6,10].

Congo red dye is used to effectively identify amyloid deposits by taking advantage of the orderly ecostructure of the amyloid material to accumulate in a regular pattern in damaged tissue[5]. It is particularly sensitive to the accumulation of protein-hyaline substance, due to its birefringence to polarized light, showing amyloid deposits with a brownish-green hue[4,9,15].

The complexity of the disease makes it particularly dangerous for certain population groups, especially those with a history of monoclonal gammopathy, as they are more likely to incorrectly fold mild dogs[12]. The elderly population presents a progressive decrease in proteostasis with age and, with advancing age, there is a greater accumulation of hyaline material in the body, which intensifies the risk and severity of the disease[3,12].

As it is a rare disease, it is estimated that currently only 15,000 people worldwide are affected by amyloidosis, with a higher incidence in more developed countries, such as the United States and Japan[6,13,14]. In a retrospective analysis, these countries, together with Russia, accumulated 73,567 cases over a period of 20 years, which demonstrates the severity of the disease, with a decrease in the number of living patients with this pathology[13,14].

This epidemiological distribution suggests that the prevalence in developed countries may reflect not only a higher incidence of the disease, but also a greater capacity to diagnose and record it, in contrast to countries with less developed health systems, which have difficulties in diagnosing and treating the disease[10,13,14].

This fact can have an impact on the survival rate of patients, since, when diagnosed and treated early, they have a survival rate of 79% when diagnosed in the first year, but this rate drops dramatically to 10% at the end of twenty years[13]. This steep decline can be attributed to disease progression and a lack of effective long-term therapies, which highlights the need to improve treatment and diagnosis[14].

The prognosis for patients with AL amyloidosis is not positive and usually involves an ongoing struggle with debilitating symptoms and a high mortality rate. The objective of this article is to investigate in detail all the symptoms of AL amyloidosis, highlighting the need to develop new therapeutic approaches for this severe disease, in addition to highlighting the challenges in diagnosis

and treatment[6,14]. Therefore, it is critical that efforts continue to be made not only to improve existing treatment protocols, but also to develop new therapeutic approaches that can directly target the underlying causes of increased protein formation[3,14].

MATERIALS AND METHODS

The bibliographic method was used to compile data from sources such as PUBMED, Scielo and Google Scholar in the last five years, through the search of keywords such as (Diagnosis of amyloidosis), (Incorrect protein folding), (Systemic complications), (Macroglossia) and (κ and λ chains). The study includes a table detailing the clinical manifestations in each organ studied, showing the affected organ, symptoms and symptoms, functional impact, diagnosis, and prevalence in patients. To support this information, reference works on the subject were consulted, such as Porth C.M. Pathophysiology. 9th ed. Rio de Janeiro: Guanabara Koogan; 2014, "Pathological Basis of Disease" by Robbins & Cotran Pathology (9th edition; Rio de Janeiro: Elsevier; 2016) 7, and Rubin E, Strayer DS, et al. Rubin Pathology: Clinicopathologic Foundations of Medicine. Philadelphia: Lippincott Williams & Wilkins; 2015, as well as relevant articles available on the websites of global amyloidosis support organizations, such as the Amyloidosis Foundation.

THEORETICAL FRAMEWORK

AL amyloidosis is induced by the same pathophysiological principle as the other subtypes of amyloid, with incorrect protein folding being the cause of the disease. What differentiates it from the other subtypes is the nature of misfolded proteins, which are derived from immunoglobulin κ or λ light chains, which accumulate in excess due to monoclonal dyscrasia, in which an affected parent B lymphocyte misfolds and transmits its protein folding defect to its clones[1,4,5].

AL amyloidosis can manifest as a systemic or localized disease, with its severity depending on the area and dissemination of concentrated amyloid material[8, 9, 10]. In the systemic form, it appears mainly in the heart and kidneys, indicating the severity and concern with this disease [3]. The localized form, on the other hand, is milder and involves accumulations in specific sites that, although they can trigger hemorrhages, do not pose a risk to human life in the long term[4].

Due to the numerous conditions of the disease, its diagnosis is very complex and complicated, as it initially presents with generic symptoms and signs, which can be easily confused with other pathologies[4,6,11]. Errors and delays in diagnosis occur mainly in regions of the world with less capacity to detect and treat the disease, due to an inadequate health structure[13,14].

Local biopsy is recommended for the accurate diagnosis of AL amyloidosis, but it is a very expensive and invasive diagnostic auxiliary method that is not very accessible in regions of the world that lack health structures[12,13,14]. For this reason, alternative screening techniques are used, which are

characterized by a high level of efficiency in confirming the diagnosis, without the associated high cost and invasiveness, such as tongue and lip biopsy and subcutaneous fat collection[3].

When a local biopsy is performed, the diagnosis is certain, as part of the affected tissue will be analyzed microscopically, and it will be possible to identify amyloid deposits in the tissue, as described in the article by Rubin & Strayer in 2015. To obtain even greater diagnostic certainty, Congo red staining is used, which has the capacity of birefringence under polarized light, showing the greenish-brown color typical of amyloid accumulations[4].

In 2021, the Faculty of Medicine of Coimbra developed a scientific study entitled "Monoclonal Gammas: Differential Diagnosis and Diagnosis of AL Amyloidosis", which addresses each clinical manifestation and the pathophysiological mechanisms existing in the disease, emphasizing the direct injury of the aforementioned organs, being of great value for medical scientific progress[3].

In addition, case reports illustrate the various presentations of the disease in specific organs, such as the study published in 2022 in the Spanish journal specializing in hematology, "hematology, transfusion and cell treatment", which dealt with the case of a 71-year-old male patient,[10] Male patient, 71 years old, former alcoholic, former smoker, who presented to the hospital with weakness, dyspnea, lower limb edema, and macroglossia, which led to the diagnostic hypothesis of amyloidosis and, by biopsy, the cardiac form of the disease was confirmed.

Another case study, published by ScienceDirect in 2022, presents a 57-year-old male patient, obese, smoker, who presented with lower limb edema, proteinuria, and macroglossia, symptoms compatible with amyloid kidney disease. Given the diagnostic hypothesis, a biopsy of lingual tissue was requested, the result of which was positive for amyloid.[17] This was followed by confirmation by urinary immunofixation, which revealed the presence of monoclonal lambda protein, and renal biopsy was consistent with mild cardia deposits.

In terms of challenges, the complexity of the disease and the variability of symptoms make treatment and diagnosis difficult, becoming even more evident in places that do not have good health services and research, making it possible to establish a relationship with its epidemiology, The prevalence is low in Latin America, not due to the lower number of incidences in poorer countries, but only because they do not have the infrastructure to diagnose and treat the disease[12,13,14].

The underfunding of health care by the governments of the least developed countries is a serious problem. Greater investment in research is essential to improve the accuracy and speed of diagnosis, enabling more effective treatment and preventing the progression of diseases for which there is no known cure.

RESULTS AND DISCUSSION

Meticulous research on AL amyloidosis and its various clinical presentations has revealed significant findings that are consistent with the literature and epidemiology, providing an in-depth understanding of the complex pathological manifestation of amyloidosis caused by monoclonal B-lymphocyte dyscrasia[4,8,14]. The results were systematically organized in a table, exploring the following topics: affected organ, associated signs and symptoms, functional impact of each presentation of AL amyloidosis, the diagnostic method used, and the frequency with which each complication occurs in relation to each organ[6]. The goal is to briefly clarify the details of this rare disease.

Table 1 - AL amyloid profile: symptoms, diagnoses, and prevalence by organ [3,4].

Bodies	Signs and symptoms	Functional impact	Diagnosis	Prevalence in patients with AAL
Heart	Dyspnoea, fatigue, oedema, arrhythmias	Restrictive cardiomyopathy	Echocardiogram, endomyocardial biopsy	70%
Kidneys	Proteinuria, oedema, renal insufficiency	Glomerular dysfunction, renal insufficiency	Kidney biopsy, urinalysis	60%
Liver	Hepatomegaly, hepatic impairment	Impaired liver function	Biopsy, abdominal ultrasound	20%
Peripheral nervous system	Pain, paresthesia, burning sensation	Neuropatia periférica	Clinical examination, nerve conduction studies, nerve biopsy	15%
Gastrointestinal treatment	Diarrhoea, constipation, weight loss, obstruction	Motor dysfunction and impaired absorption	Endoscopy, biopsy, and gastrointestinal treatment	15%

Source: Cardoso NL. Monoclonal Gamopathies: Differential Diagnosis and Diagnosis of AL Amyloidosis. Faculty of Medicine of Coimbra [Internet]. 2021 Apr [cited 20 April 2024].

Cardiac involvement is characterized by restrictive cardiomyopathy, which can affect any chamber of the heart and the heart pump delivery system[3,7,9]. Amyloid material is deposited in these compartments, triggering toxic effects on the tissue and direct mechanical effects on the heart muscle, causing tissue necrosis and interstitial fibrosis[3,4,7].

Renal disease is characterized by the deposition of amyloid in the mesangial cells and in the basement membrane of the renal glomerulus, which can also be deposited in the renal parenchyma, causing progressive organ failure as the protein-hyaline material accumulates in the tissue[3,8,14]. This may be due to insufficient glomerular filtration or the pressure exerted by the amyloid body on local cells, causing direct mechanical damage[3,8].

Hepatic accumulation is characterized by the distribution of amyloid in the perisinusoidal space of Disse, a region located in the hepatic sinusoid, between a cord composed of hepatocytes and another cord[3]. It can affect the parenchyma and its functional components, such as the portal vessels

and the central vein. This deposit causes an increase in the size of the liver itself, but the hepatocytes are seriously compromised, as the accumulation compresses the cell type, causing atrophy[3,4].

In the peripheral nervous system, immunoglobulin light chains are deposited in the innermost layer of the nerve fiber, the endoneurium[3]. It mainly affects the smaller nerve fibers, resulting in a symmetrical loss of pain and thermal sensitivity.[4] Eventually, in more advanced cases, autonomic nerve dysfunction occurs[3,4].

When amyloid material is deposited in the gastrointestinal tract, it is mainly found in the mucosa and, depending on the concentration levels, can affect the mucosal muscle or the external muscle[3]. It mainly affects the structural components of the following organs: duodenum, stomach, and colon[3, 4]. This concentration of low levels of immunoglobulin in the tissue causes considerable problems, such as malnutrition due to loss of nutrient absorption and, in advanced cases, can affect the enteric autonomic system, affecting the Auerbach's myenteric and Meissner's submucosal nerve plexuses, disabling functional motility[3,4]. As already mentioned, AL amyloidosis has distinct and varied clinical manifestations, behaving heterogeneously in terms of its condition[3,4,6]. Thus, its clinical signs will also be very broad, initially presenting with generic symptoms that can be easily confused with other pathologies, such as the manifestation of edema, fatigue, renal or cardiac dysfunction[4,11].

As amyloid material progressively accumulates in the tissues, the presumptive diagnosis becomes more effective, with the appearance of striking characteristics of the pathology, such as macroglossia, periorbital purpura, and changes in skin texture[9,10,11]. However, the diagnosis is only presumptive, so it is necessary to resort to auxiliary diagnostic methods, the most recommended being tissue biopsy[3,4].

Local tissue biopsy involves collecting a sample of the organ suspected of having amyloid accumulation and is the most assertive way to make the diagnosis[5,15]. However, it is generally not considered necessary in cases where the objective of biopsy is to eliminate hypotheses, as it is an invasive method that can lead to post-biopsy hemorrhages, in addition to being a very expensive method[3]. Instead, less invasive methods are used for analysis, such as bone marrow, lip or minor salivary gland biopsy, or even subcutaneous fat aspiration[3].

After sifting, the sample is prepared on slides for microscopic analysis, which includes a particularly sensitive stain for the identification of amyloid, Congo red, which has the characteristic of turning brownish-green under polarized light, which makes it essential for diagnosis[4,11].

Image 1 - Accumulation of amyloid material in the tissue: A) image containing amyloid accumulation stained with Congo red under polarized light. 15B) image containing amyloid accumulation with Congo red staining.

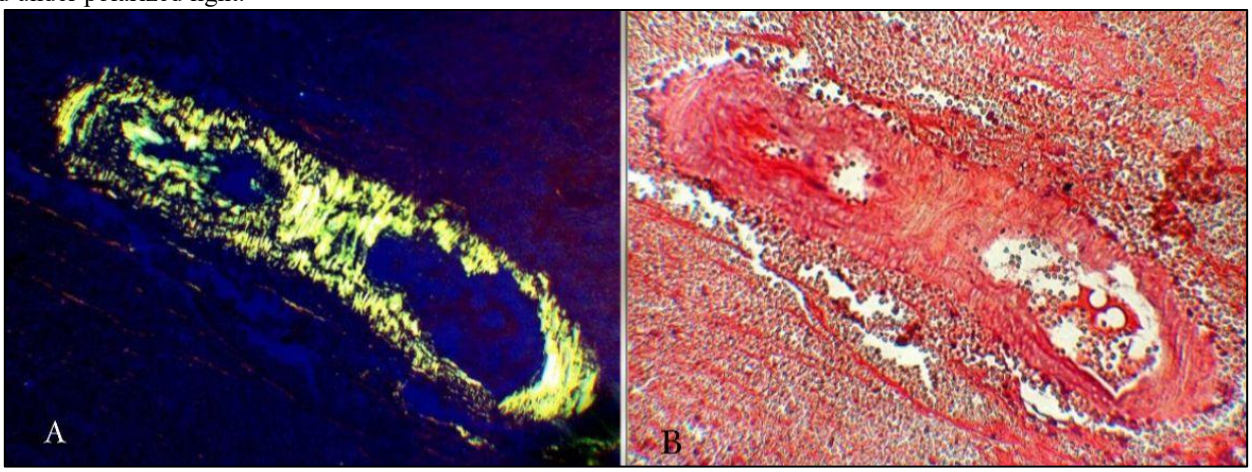

Source: Department of Pathological Anatomy, Faculty of Medical Sciences, UNICAMP. Angioamyloid [Internet]. Campinas: UNICAMP; c2024 [cited 21 Apr 2024].

A microscopic examination of a biopsy slide from a patient with suspected AL amyloidosis shows a typical picture of amyloid deposits. These deposits are characteristically spherical, with a homogeneous and glassy appearance, facilitating the visualization and distinction of laminin components[4,10,15]. However, amyloid fibrils can be configured in other shapes and angles, such as transverse, oblique, radial and longitudinal, adapting to the morphological configuration of the affected organ[4,7,15].

The high degree of complexity of AL amyloidosis makes it particularly dangerous, especially in individuals predisposed to inadequate folding of immunoglobulin light chains, as is the case of patients diagnosed with monoclonal gammopathy, a disease in which there is abnormal production of antibodies by plasma cells[12]. In addition to representing a great risk for the elderly, who usually have imbalances in the levels of protein in the body, and due to advancing age, it allows a greater accumulation of amyloid material in the tissues, making the disease more aggressive[3,12].

Based on its epidemiology, amyloidosis associated with B-lymphocyte dyscrasia has a limited evidence base, as studies on this disease have been conducted predominantly in countries with more developed health systems[13,14]. In these regions, patients are more likely to survive, which facilitates research[14]. On the other hand, countries with less robust health systems have difficulty conducting studies on AL amyloidosis due to the lack of diagnostic technology and lower patient survival rates, which compromises the accumulation of epidemiological data in these contexts[13].

Due to several factors, including the difficulty of diagnosis and the dangerous progression of the disease, AL amyloidosis does not have a positive prognosis and often involves great suffering for the patient, as there is difficulty in early diagnosis and an internal battle against the numerous related symptoms[6,14].

This limiting and aggressive pathology debilitates countless people around the world, who are often unaware of their condition, either because it is difficult to diagnose or because it is rare. For

this reason, it is necessary to invest more in studies and research to solve the initial problem, trying to find solutions to the characteristic unfolding of the disease.

CONCLUSION

This study highlights the complexity and heterogeneity of Al amyloidosis, a rare and serious pathology characterized by the abnormal deposition of amyloid material resulting from a monoclonal dyscrasia of B lymphocytes, which causes the breakdown of immunoglobulin light chains. The results demonstrate the severity of the disease, which manifests itself in its most aggressive systemic form, affecting vital organs such as the heart and kidneys, leading to significant dysfunctions.

The detection and diagnosis of the disease represent considerable challenges for health systems, due to its variable clinical presentation and initially generic symptoms that are easily confused with other pathologies. This fact forces the use of conclusive methods, such as biopsy of damaged tissue, accompanied by Congo red staining, although its application is limited by its invasiveness and high associated cost.

Its prevalence suggests a higher incidence in countries with more developed health systems, possibly reflecting not only the higher number of cases, but also their greater capacity for diagnosis and treatment. On the other hand, the lack of adequate resources in less developed health systems favors late diagnosis and inadequate treatment, which has a negative impact on the survival and quality of life of patients with AL amyloidosis.

Given the pernicious progression of the disease and the high mortality rate associated with it, it is evident that continuous efforts must be made to improve treatment protocols and develop new therapeutic approaches. Recognizing that this study presents retrospective data from the literature, we need to focus on improving early diagnosis techniques and exploring treatments that can effectively intervene in increasing protein formation and reducing the negative effects of this devastating disease.

The authors would like to express their sincere thanks to the Universidad Central del Paraguay for organizing the Integrated Academic Activities - Preclinical Cycle, which provided a favorable environment for this study.

We would also like to thank each of the team members, whose commitment and dedication were essential for the development of this scientific article. Their individual contributions greatly enriched the work.

Special thanks to Dr. Makarena Velázquez for her knowledge and valuable contribution, which were essential for the quality and depth of this study.

THANKS

The authors would like to express their sincere thanks to the Universidad Central del Paraguay for organizing the Integrated Academic Activities - Preclinical Cycle, which provided a favorable environment for this study.

We would also like to thank each of the team members, whose commitment and dedication were essential for the development of this scientific article. Their individual contributions greatly enriched the work.

Special thanks to Dr. Makarena Velázquez for her knowledge and valuable contribution, which were essential for the quality and depth of this study.

REFERENCES

Baker, K. R. (2022). Amiloidose cardíaca leve: Epidemiologia, estadiamento e prognóstico. DeBakey Methodist Cardiovascular Journal, 18(2), 27-35. Available at: https://www.ncbi.nlm.nih.gov/pmc/articles/PMC8932379/. Accessed on April 20, 2024.

Barbeta, T. Y., Bittencourt, R. I., Paz, A. A., Silva, L. L. A., Ferrelli, R. S., Lamaison, D. B., Hofmann, A. A., Calvache, E. T., Ribeiro, A. S., & Portich, J. P. (2021). AL amyloid, uma apresentação rara e um desafio diagnóstico. Hematology, Transfusion and Cellular Therapy. Available at: https://www.sciencedirect.com/science/article/pii/S2531137921004673?via%3Dihub. Accessed on April 20, 2024.

Cardoso, N. L. (2021, April). Gamopatias monoclonais: Diagnóstico diferencial e diagnóstico da amiloidose AL. Faculdade de Medicina de Coimbra. Available at: https://estudogeral.uc.pt/bitstream/10316/98399/1/Trabalho%20Final%20MIM%20-%20Diagn%C3%B3stico%20diferencial%20e%20digan%C3%B3stico%20da%20Amiloidose%20AL%2C%20Nelson%20Lopes%20Cardoso.pdf. Accessed on April 20, 2024.

Fernandes, F., Alencar Neto, A. C., Bueno, B. V. K., et al. (2022). Perfil clínico, laboratorial e de imagem em pacientes com amiloidose sistêmica em um centro de referência em cardiologia no Brasil. Arquivos Brasileiros de Cardiologia, 118(2), 422-432. doi:10.36660/abc.20201003. Available at: https://www.ncbi.nlm.nih.gov/pmc/articles/PMC8856672/. Accessed on April 20, 2024.

Fundação Amiloidose. (2024). Fatos sobre a amiloidose AL. Available at: https://amyloidosis.org/facts/al/. Accessed on April 20, 2024.

Gurung, R., & Li, T. (2022, January 23). Renal amyloidosis: Presentation, diagnosis, and management. American Journal of Medicine. Available at: https://www.amjmed.com/article/S0002-9343(22)00024-9/fulltext. Accessed on April 20, 2024.

Gustine, J. N., Staron, A., Mendelson, L., Joshi, T., Gopal, D. M., Siddiqi, O. K., Ruberg, F. L., & Sanchorawala, V. (2023). Predictors of treatment response and survival outcomes in patients with advanced AL cardiac amyloidosis. Blood Advances, 7(20), 6080-6091. Available at: https://ashpublications.org/bloodadvances/article/7/20/6080/497448/Predictors-of-treatment-response-and-survival. Accessed on April 20, 2024.

Krahl, E. M., Filho, J. C. M., Soares, V. E. M., Franciosi, M. L. M., & Carmo, T. I. T. D. (2020, November). Amiloidose AL: Relato de caso. Hematology, Transfusion and Cellular Therapy, 42(S2), 247-248. Available at: https://www.htct.com.br/en-al-amiloidose-relato-de-caso-articulo-S253113792030701X. Accessed on April 20, 2024.

Michel, F. P. S., Silveira, N. P. V., Júnior, J. W. L., Gomes, P. M. S., Fenili, A. C., Capra, M. E. Z., Trindade, L. C. G., Vidor, S., Soares, T. B., & Moreno, F. L. (2022, October). Amiloidose AL: Relato de caso. Hematology, Transfusion and Cellular Therapy, 44(Suppl 2), S248-S249. Available at: https://www.htct.com.br/pt-amiloidose-al-relato-de-caso-articulo-resumen-S253113792200534. Accessed on April 20, 2024.

Porth, C. M. (2014). Fisiopatologia (9th ed.). Rio de Janeiro: Guanabara Koogan.

Robbins, S. L., Cotran, R. S., & Kumar, V. (2010). Patologia Estrutural e Funcional (9th ed.). Rio de Janeiro: Elsevier.

Riva, E. (2022, June). Diagnóstico da amiloidose sistêmica. Bases hematológicas úteis para o cardiologista clínico. Revista Uruguaia de Cardiologia, 37(1), e304. Available at: http://www.scielo.edu.uy/scielo.php?script=sci_arttext&pid=S1688-04202022000101304&lng=es. Accessed on April 20, 2024.

Rubin, E., & Strayer, D. S. (2015). Rubin's Pathology: Clinicopathological Fundamentals of Medicine (7th ed.). Philadelphia: Lippincott Williams & Wilkins.

Simões, M. V., Fernandes, F., Marcondes-Braga, F. G., Scheinberg, P., Correia, E. B., Rohde, L. E. P., Bacal, F., et al. (2021). Posicionamento sobre diagnóstico e tratamento da amiloidose cardíaca. Arquivos Brasileiros de Cardiologia, 117(3), 561-598. Available at: https://pubmed.ncbi.nlm.nih.gov/34512345/. Accessed on April 20, 2024.

Alvim, G. F., Mayrink, G. T. C., & Ferreira, A. A. (2022, October). Amiloidose e macroglossia: Uma associação que não pode ser ignorada - relato de caso. Hematology, Transfusion and Cellular Therapy, 44(Suppl 2), S243-S244. Available at: https://www.sciencedirect.com/science/article/pii/S2531137922005272. Accessed on April 20, 2024.

Departamento de Anatomia Patológica, Faculdade de Ciências Médicas, UNICAMP. (2024). Angioamilóide. Campinas: UNICAMP. Available at: https://anatpat.unicamp.br/nptangioamiloide2b.html. Accessed on April 21, 2024.

Gurung, R., & Li, T. (2022, January 23). Renal amyloidosis: Presentation, diagnosis, and management. American Journal of Medicine. Available at: https://www.amjmed.com/article/S0002-9343(22)00024-9/fulltext. Accessed on April 20, 2024.

Kumar, N., Zhang, N., Cherepanov, D., Romanus, D., Hughes, M., & Faller, D. V. (2022, July 19). Epidemiologia global da amiloidose da cadeia leve amiloide. Journal of Clinical Medicine, 17(1). Available at: https://pubmed.ncbi.nlm.nih.gov/35854312/. Accessed on April 20, 2024.