LUMEN ET VIRTUS

REFRACTORY HYPERTENSION IN A YOUNG PATIENT: A CASE REPORT

https://doi.org/10.56238/levv15n40-063

Rafael Moura Castro[1], Beatriz Bandeira Nasorri [2], Isabela Ewbank Barbosa [3] and Luiza Travalini de Abreu Louzada[4]

ABSTRACT

Introduction: Pheochromocytoma, a rare tumor originating from the chromaffin tissue of the adrenal medulla, has a prevalence of about 0.1-0.6% in patients with hypertension. Usually benign, its surgical removal can be curative. However, delays in diagnosis and inadequate treatment can lead to high mortality and morbidity rates. Case Report: A 23-year-old man with a history of resistant hypertension since December 2022 presented with symptoms of headache, palpitation, sweating, and anxiety. Tests revealed elevated levels of metanephrines and catecholamines, leading to the suspicion of pheochromocytoma. An MRI of the abdomen identified an expansive lesion in the right adrenal gland. Treatment included clinical management with alpha- and beta-blockers, followed by successful adrenalectomy, resulting in improvement of symptoms and hypertension. Discussion: The case illustrates the complexity inherent in the diagnosis of pheochromocytoma, a condition that often manifests surreptitiously in hypertensive patients. Resistance to conventional antihypertensive therapy, combined with symptoms such as headache, palpitations, and sweating, should raise suspicions of secondary hypertension and, consequently, pheochromocytoma. This case underlines the importance of a meticulous diagnostic evaluation in patients with refractory hypertension. Conclusion: Pheochromocytoma, despite being a rare cause of hypertension, represents a crucial differential diagnosis in secondary hypertension. Early diagnosis and appropriate surgical intervention are essential to prevent associated morbidity and mortality. This case reinforces the need for clinical surveillance for suggestive symptoms and the importance of appropriate diagnostic investigations in patients with resistant hypertension, particularly in young people.

Keywords: Pheochromocytoma. Secondary Hypertension. Diagnosis.

[1] Graduated in Medicine
Institute of Medical Assistance to State Public Servants (IAMSPE)
E-mail: rafamouracastro@gmail.com
[2] Graduated in Medicine
Institute of Medical Assistance to State Public Servants (IAMSPE)
E-mail: beatrizbandeiranasorri@hotmail.com
[3] Graduated in Medicine
Institute of Medical Assistance to State Public Servants (IAMSPE)
E-mail: iewbankbarbosa@gmail.com
[4] Graduated in Medicine
Institute of Medical Assistance to State Public Servants (IAMSPE)
E-mail: luizatravalini@hotmail.com

INTRODUCTION

Secondary arterial hypertension, distinct from essential hypertension because it is due to a specific medical condition, represents a crucial aspect in the differential diagnosis of hypertensive patients. While essential hypertension is idiopathic and represents the vast majority of cases, secondary hypertension, which includes pheochromocytoma as one of its causes, is responsible for a small but significant portion of hypertension cases. In addition to pheochromocytoma, other common differential diagnoses include kidney diseases, endocrine disorders such as primary hyperaldosteronism, and renal artery stenosis1.

Globally and in Brazil, secondary arterial hypertension is less prevalent than essential hypertension, but its identification is vital due to the specific therapeutic implications. Suspicion of secondary arterial hypertension should arise in particular clinical situations, such as the sudden onset of hypertension in young people, severe hypertension or hypertension resistant to conventional treatment, and the presence of symptoms or clinical signs that point to a specific secondary cause1.

Pheochromocytoma itself is a tumor originating from the chromaffin cells of the adrenomedullar sympathetic axis, characterized by autonomy in the production of catecholamines, such as adrenaline and noradrenaline. Its most common location is in the adrenal medulla, corresponding to 90% of cases, although they can also appear as extraadrenal paragangliomas2.

These tumors have an incidence of about 0.1% in hypertensive patients and are more frequent between the third and fifth decades of life, with a slightly higher incidence in women than in men. More than 90% of pheochromocytomas are benign and single, and tumor resection usually leads to cure. However, when malignant, they can present frequent metastases in bones, lymph nodes, liver, lungs, brain, and spinal cord. About 32% of pheochromocytomas are multiple or bilateral tumors, with a higher incidence in children and familial cases, especially associated with multiple endocrine neoplasia (MEN) types 2a and 2b2.

The most common clinical manifestation of pheochromocytoma is arterial hypertension, affecting more than 90% of patients. The classic triad of pheochromocytoma includes headache, profuse sweating, and palpitations, but patients may also present with symptoms such as anxiety, facial flushing, skin pallor, nausea, vomiting, dyspnea, and chest pain. Cardiovascular complications include angina, acute myocardial infarction, myocarditis, and dilated congestive cardiomyopathy. Acute pulmonary edema, cardiac arrhythmias, strokes, and orthostatic hypotension are other possible manifestations[8].

METHODOLOGY

The present work consists of a descriptive study, in the form of a case report. Information was obtained from electronic medical records and information available at the care institution itself. Data analysis was performed anonymously and the present discussion does not include identification of the patient in question, and the use of an Informed Consent Form is not necessary.

CASE REPORT

The case presented involves a 23-year-old male patient with a clinical history of refractory arterial hypertension under outpatient cardiological follow-up since December 2022. This condition was accompanied by intermittent episodes of refractory headache, sweating, palpitations, and symptoms of obstructive sleep apnea-hypopnea syndrome (OSAHS), later attributed to a deviated septum. In addition, the patient also reported episodes of anxiety crisis.

Medications for continuous use included losartan (50 mg 2x/day), hydrochlorothiazide (25 mg/day), amlodipine (5 mg/day), and spironolactone (25 mg/day). Despite this therapeutic regimen, the patient's hypertension and symptomatology persisted, indicating the need for further investigation to identify underlying causes and optimize treatment.

In the context of the case study, the patient's hospitalization was requested and a series of complementary tests were performed for a more detailed evaluation. Among the tests performed, the following stand out, with the main findings: Transthoracic echocardiogram revealed a left ventricular ejection fraction (LVEF) of 56%, accompanied by abnormal movement of the interventricular septum. A Holter confirmed a sinus heart rhythm without significant arrhythmic changes. In addition, a Doppler ultrasound of the renal arteries showed kidneys with normal dimensions and echotextures, with no abnormalities in Doppler flowmetry.

Regarding the most relevant laboratory tests during hospitalization, the following stand out: glycated hemoglobin of 6.1%, creatinine of 0.71, urea of 38, potassium of 4.0, sodium of 139, LDL of 100, FT4 of 1.18, TSH of 2.84 and microalbuminuria of 5.10 mg/dL. In addition, catecholamines and metanephrines showed significantly elevated values, with serum catecholamine of 9569 (normal up to 420), urinary catecholamine of 769.7 (normal 80-500), and urinary metanephrine >5000 (normal up to 718).

Due to the classic symptomatology associated with increased levels of catecholamines and metanephrines, an MRI of the abdomen and pelvis was requested

revealing significant findings. The analysis identified an expansive solid-cystic lesion circumscribed in the right adrenal glands, with heterogeneous contrast enhancement, measuring approximately 6.9 x 4.9 cm. This radiological finding, given its nature and characteristics, associated with the other findings described, sealed the diagnosis of pheochromocytoma.

Figure 1: Coronal abdominal magnetic resonance imaging showing a tumor in the right adrenal gland.



Source: authors' collection.

Figure 2: Coronal abdominal magnetic resonance imaging showing a tumor in the right adrenal glands.

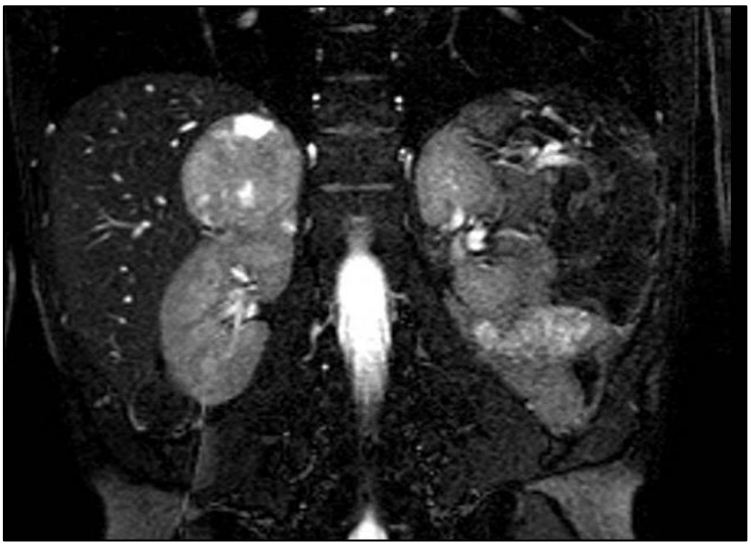

Source: authors' collection.

Figure 3: Cross-sectional abdominal magnetic resonance imaging.

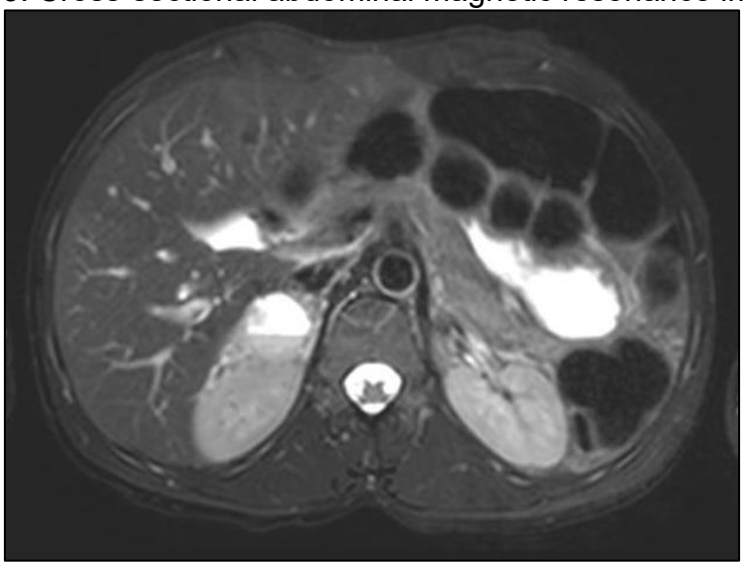

Source: authors' collection.

In view of the diagnosis of pheochromocytoma, clinical management and preoperative preparation were carried out. In this context, as the patient was already using the antihypertensive medications mentioned above, doxasozine 4 mg/day was first added to perform alpha blockade and, later, carvedilol 3.125 mg every 12/12 hours was added to beta blockade. Thus, after two weeks of blood pressure control followed by heart rate, the surgical procedure was performed with adrenalectomy of the right adrenal gland via laparoscopy without intercurrences.

After the procedure, the patient remained hospitalized for another five days for clinical follow-up and complete weaning from all antihypertensive drugs and beta-blockers. He was discharged after and is currently being monitored by the cardiology and endocrinology team on an outpatient basis, where the benign pheochromocytoma was confirmed by the anatomopathological examination and he remains asymptomatic.

DISCUSSION

Pheochromocytoma is a rare, mostly benign neoplasm that originates from the chromaffin cells of the adrenomedullar sympathetic system. These tumors are notable for the autonomic production of catecholamines, especially adrenaline and noradrenaline1. Although most of them are located in the adrenal medulla (90% of cases), they can also appear in other regions such as paraganglia, thorax, bladder, or brain, which are then classified as extraadrenal pheochromocytomas or paragangliomas[2].

Prevalence is highest in young and middle-aged adults, ranging between 30 and 60 years. The incidence among hypertensive patients is approximately 0.1%, being more frequent in women5. Pheochromocytomas are mostly single tumors, with surgical resection

usually resulting in cure. However, malignant cases are more challenging, with the potential for metastasis in various locations such as bones, lymph nodes, liver, lungs, brain, and spinal cord[2].

The most common clinical condition is arterial hypertension, affecting more than 90% of patients. This hypertension is often resistant to conventional antihypertensive treatment, but may partially respond to alpha-adrenergic blockers, calcium channel blockers, and sodium nitroprusside1. Hypertension is sustained in half of the cases, while the rest have hypertensive paroxysms. In addition, the classic triad of symptoms associated with hypertension includes headache, profuse sweating, and palpitations, with other symptoms such as anxiety, facial flushing, pallor, nausea, vomiting, dyspnea, and chest pain also being common[5].

For diagnosis, 24-hour urine collection is essential for measurement of urinary metanephrines and catecholamines, in addition to serum dosage. The sensitivity and specificity of these tests vary, and the interference of certain foods and medications is an important factor to consider. Accurate diagnosis often requires a combination of both tests[3].

In 24-hour urine, the levels of catecholamines (epinephrine, norepinephrine) and metanephrines (metanephrine and normetanephrine) are measured, and this test has a sensitivity of 77-90%. On the other hand, the measurement of serum metanephrines and catecholamines has a high sensitivity (97-99%), but with relatively low specificity (85%), which may result in some false positives[3].

It is important to note that certain foods (such as caffeine, bananas, and chocolate) and medications (such as paracetamol) can interfere with test results, but patients with pheochromocytoma usually have a significant increase in catecholamine or metanephrine levels, often more than two to three times above the upper limit of normality8.

After biochemical confirmation, imaging tests are performed to locate the tumor. The modalities include computed tomography (CT) and magnetic resonance imaging (MRI) of the abdomen, pelvis and, in some cases, other suspicious areas6. CT and MRI have similar sensitivities (90-100%) and specificities (70-80%) for the detection of pheochromocytomas10.

In some cases, functional imaging studies, such as MIBG (meta-iodobenzylguanidine) or PET-CT (positron emission tomography) scintigraphy, are employed. These tests use radioisotopes to identify functional tumors, and are particularly useful when tumors are difficult to locate with CT or MRI6. In cases with suspected genetic or familial components, genetic testing may be indicated to identify associated syndromes and guide the clinical management of the patient and family members[5].

Before surgery, it is crucial to stabilize the patient's blood pressure and blood volume. Medications such as alpha-adrenergic blockers are often used to control hypertension8. The use of beta-adrenergic blockers may be considered after stabilization with alpha-blockers, to control tachycardia and arrhythmias. Pre-surgical preparation usually takes 10 to 14 days[9].

Laparoscopic adrenalectomy is the most common technique for removing pheochromocytomas. In cases of bilateral or multiple tumors, a more extensive surgical approach may be necessary. For malignant pheochromocytomas, surgery may not be curative due to the presence of metastases8. In these cases, treatment may include adjunctive therapies such as radiation therapy, chemotherapy, and radioactive iodine therapy (therapeutic MIBG). These options, however, have limited efficacy and are mainly palliative[9].

After surgery, regular monitoring of catecholamine and metanephrine blood levels is essential to detect recurrence. Patients with pheochromocytoma have an elevated risk of developing other endocrine tumors, particularly those with a genetic or familial basis, requiring continuous monitoring[3] .

In rare cases, where surgery presents excessive risks due to other health problems of the patient or in inoperable pheochromocytomas, treatment is conservative, focusing on symptom control with medications[9].

The success rate of surgery is high for benign pheochromocytomas, with most patients returning to a normal life after recovery. The recurrence rate after surgery is low, but it may be higher in cases with a genetic basis. For malignant pheochromocytomas, the prognosis is poorer, with survival rates varying significantly based on disease extent and response to treatment[8,9].

CONCLUSION

The study of pheochromocytoma, presented in this article, reinforces the importance of a careful differential diagnosis in cases of refractory arterial hypertension, especially in young populations. Thorough investigation, involving detailed clinical evaluations, laboratory and imaging tests, is essential for the correct identification of this pathology.

The treatment, primarily surgical, demonstrates high success rates in benign tumors, with adrenalectomy resulting in resolution of symptoms and normalization of blood pressure. In malignant cases, additional approaches such as adjunctive therapies are necessary. In summary, pheochromocytoma, although rare, is a significant clinical entity

that requires a multi-specialty, individualized approach to optimize treatment outcomes and patient prognosis.

REFERENCES

1. Sousa, A. C. Sobral, Issa, A. F. C., Filho, B. M., Nascimento, B. R., Filho, H. C., Vieira, M. L. C., & Barroso et al. (2021). Diretrizes Brasileiras de Hipertensão Arterial – 2020. *Arquivos Brasileiros de Cardiologia, 116*(3), 516-658. https://doi.org/10.36660/abc.20201238

2. Marques, A. P. et al. (2016). *Rev Port Endocrinol Diabetes Metab, 11*(2), 156–162. http://dx.doi.org/10.1016/j.rpedm.2016.05

3. Cano Megías, M., Rodriguez Puyol, D., Fernández Rodríguez, L., Sencion Martinez, G. L., & Martínez Miguel, P. (2016). Pheochromocytoma-paraganglioma: Biochemical and genetic diagnosis. *Nefrologia, 36*(5), 481-488. https://doi.org/10.1016/j.nefro.2016.03.010

4. Mosquera Gorostidi, A., Justo Ranera, A., Zakirian Denis, S. E., González Temprano, N., Sagaseta de Ilúrdoz Uranga, M., & Molina Garicano, J. (2015). Feocromocitoma y paraganglioma en la infancia: a propósito de 2 casos. *An Pediatr (Barc), 82*(1), e175-80. https://doi.org/10.1016/j.anpedi.2014.06.018

5. Iglesias, P. et al. (2021). Pheochromocytoma: A three-decade clinical experience in a multicenter study. *Rev Clin Esp (Barc), 221*(1), 18-25. https://doi.org/10.1016/j.rceng.2019.12.011

6. Corral de la Calle, M. A. et al. (2022). Adrenal pheochromocytoma: Keys to radiologic diagnosis. *Radiologia (Engl Ed), 64*(4), 348-367. https://doi.org/10.1016/j.rxeng.2022.07.002

7. Pereira, M. A., Souza, B. F., Freire, D. S., & Lucón, A. M. (2004). Feocromocitoma. *Arq Bras Endocrinol Metabol, 48*(5), 751-75. https://doi.org/10.1590/s0004-27302004000500022

8. Faiçal, S., & Shiota, D. (1997). Feocromocitoma: atualização diagnóstica e terapêutica. Disciplina de Endocrinologia, Departamento de Medicina, Universidade Federal de São Paulo, Escola Paulista de Medicina, São Paulo, SP. Disponível em: https://www.scielo.br/j/ramb/a/7JTGqXnjF9XrzSHqJNJSjzC/. Acesso em: 12 nov. 2023.

9. Bury, R. et al. (2021). Hipertensión maligna y feocromocitoma: reporte de un caso. *Hipertens Riesgo Vasc, 38*(4), 201-205. https://doi.org/10.1016/j.hipert.2021.05.003

10. Araujo-Castro, M. et al. (2022). Role of imaging test with radionuclides in the diagnosis and treatment of pheochromocytomas and paragangliomas. *Endocrinol Diabetes Nutr (Engl Ed), 69*(8), 614-628. https://doi.org/10.1016/j.endien.2022.11.011