LUMEN ET VIRTUS

A case report on omentum infarction with conservative treatment

https://doi.org/10.56238/levv15n40-044

Natalia Cervantes Uzeloto Guazi[1], Julia Maria Machado Luiz[2], Fernanda Mello Valverde[3], I'm sure Fernanda Kataoka[4], Dianah Dantas Pulvirenti[5], Nereida Christine de Camargo[6], Beatriz Holmo Freire[7] and Manuella Calônico Gonzalez Martins[8]

ABSTRACT

Introduction: OI is a rare condition that can occur at any age with a 2:1 male-to-female ratio, although most cases appear in people between 30 and 50 years of age. Patients with OI often present with acute or subacute nonspecific abdominal pain that usually involves the right abdominal quadrants. The diagnosis of OI cannot be based on clinical presentation alone, as symptoms often mimic other abdominal diseases. Treatment usually involves a conservative approach with antibiotics, analgesics, and rest, but surgical intervention may become necessary in certain situations, such as diagnostic uncertainty, failure of conservative treatment, or the presence of complications such as abscess formation or peritonitis. Discussion: IO has a very low incidence of approximately 0.3% of all patients presenting with acute abdomen and its underlying etiology remains poorly understood. Radiological imaging using computed tomography and magnetic resonance imaging increased the yield of the diagnosis of omental infarction. The management of IO is a topic for debate. There is a paradigm shift from the previous surgical approach of performing a laparotomy or laparoscopy to a more conservative management in OI. Conclusion: The etiology of OI is not yet well explained, but there are risk factors for the development of this pathology, such as obesity or blunt abdominal trauma. Computed tomography remains the best form of diagnosis to rule out other causes. Its treatment is still discussed, and may consist of surgical or conservative treatment.

Keywords: Omental infarction, Treatment, Clinical presentation.

[1] Medical Graduate
University of Western São Paulo – UNOESTE
[2] Medical Graduate
University of Marília – UNIMAR
[3] Medical Graduate
University of Marília – UNIMAR
[4] Medical Graduate
University of Marília – UNIMAR
[5] Medical Graduate
University of Marília – UNIMAR
[6] Medical Graduate
University of Marília – UNIMAR
[7] Medical Graduate
University of Marília – UNIMAR
[8] Medical Graduate
University of Marília – UNIMAR

INTRODUCTION

Acute abdominal pain is a prevalent complaint among patients presenting to emergency departments, accounting for approximately 10% of all emergency room visits. The differential diagnosis of acute abdominal pain is complex, as many conditions can present with similar symptoms. Although appendicitis is a well-known and frequently diagnosed cause of this pain, omental infarction (OIO) is a rare cause of acute abdominal pain characterized by occlusion of the omental blood supply leading to ischemia and necrosis, it can mimic the clinical presentation of appendicitis, underscoring the importance of awareness and consideration of this condition when evaluating patients with acute abdominal pain (ALYAMI et al. 2023) (MEDINA-GALLARDO et al. 2020).

OI is a rare condition, which can occur at any age with a 2:1 male-to-female ratio (ESPOSITO et al. 2020), although most cases appear in people between 30 and 50 years of age, with a predominance in male and obese patients (MEDINA-GALLARDO et al. 2020), and is seen more frequently in children (CASTRO et al. 2019). Predisposing factors include: malformations of the mesenteric pedicle, sudden increase in intra-abdominal pressure (including sudden changes in posture), coagulation disorders, hernias, tumors, and adhesions. More often, OI occurs on the right side of the omentum due to its greater length, mass, and greater mobility than the left-sided omentum, with obesity being the most important risk factor for the development of OI (KOZŁOWSKI et al. 2021).

In obese patients, the accumulation of perivascular fat in the omentum reduces the blood supply to the developing omentum, which leads to relative ischemia (KOZŁOWSKI et al. 2021). The causes of OI can be categorized as primary and secondary. Secondary OI occurs after omental torsion, commonly due to tumor, hernia, localized inflammation, trauma, postoperative adhesions, and other rare causes such as vasculitis, polycythemia, hypercoagulability, and thrombophilia. Compared to secondary omental infarction, the etiology of primary omental infarction or spontaneous omental infarction is not yet clearly understood (SUBASINGHE et al. 2022).

Patients with OI often present with acute or subacute nonspecific abdominal pain that usually involves the right abdominal quadrants. Onset can occur after a heavy meal or a sudden movement, increasing in severity over time, and on average, patients seek medical attention three days after the onset of symptoms. On examination, children with IO present with tender peritoneal irritation. Occasionally, the pain may change with movement, which may suggest the diagnosis. In 50% of cases, fever, anorexia, nausea, vomiting, diarrhea, and dysuria are associated. Usually, laboratory tests are unremarkable; OI is usually associated only with mild leukocytosis and mild elevation of C-reactive protein

(CRP) and erythrocyte sedimentation rate (ESR) levels. However, the clinical presentation of IO is highly variable, and the differential diagnosis with acute appendicitis or other pathologies is often challenging (ESPOSITO et al. 2020).

The diagnosis of OI cannot be based on clinical presentation alone, as symptoms often mimic other abdominal diseases, especially acute appendicitis. Prior to the use of ultrasonography (US) and computed tomography (CT), the diagnosis of OI was made during surgery. Unlike in the past, imaging now allows a preoperative diagnosis, avoiding unnecessary surgical interventions (ESPOSITO et al. 2020). Preoperative diagnosis of omental infarction from other causes of acute abdomen, such as appendicitis and acute cholecystitis, is challenging as it is clinically indistinguishable. As it is a benign and mostly self-limiting disease, it is important to consider it in the differential diagnosis of a patient presenting with an acute abdomen (SUBASINGHE et al. 2022).

Recent studies have considered CT scans to be the gold standard for diagnosis thanks to its higher sensitivity for diagnosing OI (HWANG et al. 2023); however, due to concomitant exposure to ionizing radiation, it is not the first choice in pediatric patients. Therefore, US has become the safest and most reliable method of diagnosing OI, with a sensitivity of 60–80%, being highly specific and also primary in the follow-up of patients during conservative treatment. On US, the OI usually becomes visible at the point of maximum sensitivity as a triangular/oval hyperechoic mass, usually located on the right side of the omentum, below the inferior hepatic border, just behind the anterior abdominal wall. In dynamic compression of ultrasound, the IO is inflexible, attached to the abdominal wall and immobile during respiratory excursions, corresponding to the so-called "trapped fat signal". Although this finding is rarely described in the current literature and only in a series of six patients, it is well known in surgery that an inflamed omentum is adherent to the parietal peritoneum (ESPOSITO et al. 2020). In most patients, OI has a benign course, does not require surgical intervention, and can be treated with analgesics (KOZŁOWSKI et al. 2021).

Treatment of omental infarction usually involves a conservative approach with antibiotics, analgesics, and rest, as it is a self-limiting benign condition (ESPOSITO et al. 2020). Conservative treatment aims to control pain, control fever, and prevent secondary infections. The duration of antibiotic therapy depends on the severity of the infarction and the presence of associated complications. In most cases, the symptoms of omental infarction resolve in a few days to weeks with conservative treatment alone. Surgical intervention may become necessary in certain situations, such as diagnostic uncertainty, failure of conservative treatment, or the presence of complications such as abscess

formation or peritonitis. The choice of surgical approach depends on the extent of the infarction and the presence of complications (ALYAMI et al. 2023).

Laparoscopic surgery should be considered in patients with a confirmed diagnosis who do not respond rapidly to conservative treatment, or in those with uncertain disease, intractable pain, and persistent peritoneal signs. The standard McBurney or Lanz incision, used for suspected appendicitis, is inadequate and may preclude proper evaluation for diagnosis and removal of OI. As this can be located in the upper quadrant, laparoscopic surgery is certainly the best approach to explore the entire peritoneal cavity and to treat the underlying disease (ESPOSITO et al. 2020).

CASE DESCRIPTION

Patient J.C.B., male, 66 years old, obese, with regular treatment for systemic arterial hypertension and diabetes mellitus. The patient sought emergency care complaining of punctual pain in the right iliac fossa and constipation for 3 days with progressive worsening, peritonitis, nausea or vomiting. On physical examination, the patient presented with a slightly distended abdomen and pain on palpation in the right iliac fossa, with a primary diagnostic hypothesis of acute abdomen. Ultrasonography was performed, where signs of an inflammatory process involving peritoneal adipose planes anterior to the hepatic angle of the colon were found, with the hypothesis of diverticulitis. After that, computed tomography of the total abdomen was performed to elucidate the diagnosis. Upon return of the CT results, densification of the mesenterial fat was evidenced in the upper floor of the abdomen on the right, adjacent to the colon, sometimes with the appearance of forming a pseudocapsule, even determining a medial displacement of the latter, with partially defined limits, measuring about 81x73 mm in its largest axes, thus diagnosing it as an omental infarction, its treatment being clinical/conservative.

Figure 1 - Total abdomen tomography

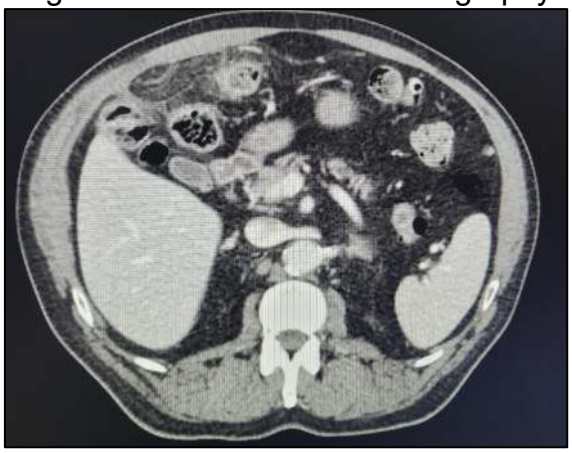

Images provided by Dr. Fernando Pereira de Almeida, Santa Casa de Misericórdia de Presidente Prudente.

Figure 2 - Tomography



Images provided by Dr. Fernando Pereira de Almeida, Santa Casa de Misericórdia de Presidente Prudente.

DISCUSSION

Omental infarction has a very low incidence of approximately 0.3% of all patients presenting with acute abdomen in emergency departments and is found in 0.1% of laparotomy for acute abdominal pain (PEMMADA et al., 2024). The condition usually presents clinically as an acute onset of right-sided lower abdominal pain, which is, and therefore mimicking acute appendicitis, and less likely acute cholecystitis, right-sided diverticulitis, and acute gynecological pathologies in the female population (SAAD et al., 2022). In the case reported, it is seen that the male patient arrived at the emergency room with characteristics of an acute abdomen, reporting punctual pain in the right iliac fossa, as described in the literature, and imaging tests were performed for the differential diagnosis. Acute bowel obstruction, abscess formation, and peritonitis with or without bowel perforation are rare complications that should be ruled out in all cases of OI (PEMMADA et al., 2024).

The underlying etiology of omental infarction remains poorly understood. However, a number of precipitating factors have been postulated in the reviewed literature, such as obesity, blunt abdominal trauma, and sudden changes in body position that have been

considered to increase intra-abdominal pressure (SAAD et al., 2022). As described in the case, where the patient was obese.

Radiological imaging using computed tomography (CT) and magnetic resonance imaging (MRI) increased the yield of the diagnosis of omental infarction. Computed tomography is considered the gold standard radiological investigation of choice for diagnosis. Not only does it help confirm the diagnosis, but it excludes other acute conditions masked by OI, such as acute cholecystitis, appendicitis, strangulated internal hernias, or cysts (PEMMADA et al., 2024). In the patient in this case, it is possible to observe the choice of computed tomography of the total abdomen for diagnostic elucidation, thus making it possible to visualize the OI.

The management of IO is a topic for debate. There is a paradigm shift from the previous surgical approach of performing a laparotomy or laparoscopy to a more conservative management in OI (PEMMADA et al., 2024). Therefore, there is still much discussion about which approach would be the best choice in the treatment of OI, since the patient described in this study was treated with conservative management, as shown in the literature that this practice is not incorrect.

METHODOLOGY

From a medical case that occurred at the Santa Casa da Misericórdia de Presidente Prudente, together with his medical record, information was collected to carry out this case report. In addition, a search for information was carried out in databases.

CONCLUSION

The etiology of omental infarction is not yet very well explained, but there are risk factors for the development of this pathology, such as obesity or blunt abdominal trauma. Computed tomography remains the best form of diagnosis in order to rule out other causes. Its treatment is still discussed, and may consist of surgical or conservative treatment.

CONFLICT OF INTEREST

The authors agree that there was no conflict of interest during this case report.

REFERENCES

1. ALYAMI, H. S. et al. Infarto omental simulando apendicite aguda: relato de caso. *Cureus*, v. 15, n. 10, p. e47232, 2023.

2. CASTRO, B. N. et al. Infarto omental esquerdo idiopático. *Autopsy & Case Reports*, v. 10, n. 1, 2019.

3. ESPOSITO, F. et al. Não apenas gordura: infarto omental e seus mimetizadores em crianças. Achados clínicos e ultrassonográficos: uma revisão pictórica. *Journal of Ultrasound*, v. 23, n. 4, p. 621–629, 2020.

4. HWANG, J. K. et al. Infarto omental diagnosticado por tomografia computadorizada, não detectado por ultrassonografia: relato de caso. *World Journal of Clinical Cases*, v. 11, n. 4, p. 972–978, 2023.

5. KOZŁOWSKI, M.; PIOTROWSKA, O.; GIŻEWSKA-KACPRZAK, K. Omental infarction in a child: conservative management as an effective and safe strategy in diagnosis and treatment. *International Journal of Environmental Research and Public Health*, v. 18, n. 15, p. 8057, 2021. https://www.ncbi.nlm.nih.gov/pmc/articles/PMC8345747/

6. MEDINA-GALLARDO, N. A. et al. Omental infarction: surgical or conservative treatment? A case reports and case series systematic review. *Annals of Medicine and Surgery (2012)*, v. 56, p. 186–193, 2020. https://pubmed.ncbi.nlm.nih.gov/32642061/

7. PEMMADA, V. et al. Primary omental infarction – a benign cause of acute abdomen. *Pleura and Peritoneum*, v. 9, n. 2, p. 63–68, 13 maio 2024. https://pubmed.ncbi.nlm.nih.gov/38948329/

8. SAAD, E. et al. Omental fat torsion: A rare mimicker of a common condition. *Journal of Investigative Medicine High Impact Case Reports*, v. 10, p. 232470962210762-232470962210762, 1 jan. 2022. https://www.ncbi.nlm.nih.gov/pmc/articles/PMC8883395/

9. SUBASINGHE, D. et al. Spontaneous omental infarction: A rare case of acute abdomen. *SAGE Open Medical Case Reports*, v. 10, p. 2050313X221135982, 2022. https://www.ncbi.nlm.nih.gov/pmc/articles/PMC9647286/