LUMEN ET VIRTUS

Nuck's canal cyst: A case report

https://doi.org/10.56238/levv15n40-041

Gizelly Ayumi Yamamoto[1], Magali da Silva Sanches Machado[2], Mariana Malheiro Negrão Bandeira[3], Claudio Kleber Juiz de Souza[4], Juliano Seger Falcão[5], Henrique Budib Dorsa Pontes[6], Augusto Boulegon Tsukamoto[7] and Kilder Carmo dos Santos[8]

ABSTRACT

Introduction: Nuck canal cyst is a rare condition that occurs due to the patency of the vaginal process in women, manifesting as indirect inguinal hernia. Clinically, it presents as a tumor in the inguinal region, which can extend to the labia majora. Case report: we present a report of a young female patient who was admitted to the emergency room with severe pain associated with tumoration in the left inguinal and umbilical region, with suspected incarcerated umbilical and/or femoral hernia, having undergone emergency surgery. Conclusion: Due to the rarity of the case, little is known about it, since there are few reports in the literature, and therefore it is often undiagnosed.

Keywords: Female Hydrocele, Hydocele, Nuck Canal, Nuck Cyst, Inguinal Canal, Inguinal Hernia.

[1] General Surgery Resident
Maria Aparecida Pedrossian University Hospital of the Federal University of Mato Grosso do Sul - (HUMAP/UFMS)
E-mail: gizellyyamamoto@gmail.com
[2] Professor of the General Surgery Residency at HUMAP/UFMS
Maria Aparecida Pedrossian University Hospital of the Federal University of Mato Grosso do Sul - (HUMAP/UFMS)
E-mail: magalisanches@gmail.com
[3] General Surgery Resident
Maria Aparecida Pedrossian University Hospital of the Federal University of Mato Grosso do Sul - (HUMAP/UFMS)
E-mail: mbn01@hotmail.com
[4] General Surgery Resident
Maria Aparecida Pedrossian University Hospital of the Federal University of Mato Grosso do Sul - (HUMAP/UFMS)
E-mail: claudio.ziuj@gmail.com
[5] General Surgery Resident
Maria Aparecida Pedrossian University Hospital of the Federal University of Mato Grosso do Sul - (HUMAP/UFMS)
E-mail: julianosfalcao@hotmail.com
[6] General Surgery Resident
Maria Aparecida Pedrossian University Hospital of the Federal University of Mato Grosso do Sul - (HUMAP/UFMS)
E-mail: henriquedorsa01@gmail.com
[7] General Surgery Resident
Maria Aparecida Pedrossian University Hospital of the Federal University of Mato Grosso do Sul - (HUMAP/UFMS)
E-mail: augustotsukamoto@hotmail.com
[8] General Surgeon graduated at HUMAP/UFMS
Maria Aparecida Pedrossian University Hospital of the Federal University of Mato Grosso do Sul - (HUMAP/UFMS)
E-mail: kilder.med@gmail.com

INTRODUCTION

Nuck's canal was described by anatomist Anton Nuck in 1691 (MANJUNATHA; BEEREGOWDA; BHASKARAN, 2012; TOPAL et al., 2018; CHAN et al., 2019). It is a rare condition, described in the literature with only about 400 cases since the first report in 1892 (CHAN et al., 2019; PRODROMIDOU et al., 2020).

Statistically, men are 9-12 times more likely to have inguinal hernia when compared to women, but women are about 4 times more likely to develop femoral hernia. This discrepancy is explained by anatomical differences: greater distance between the pubic tubercle and the inner inguinal ring, wider rectus abdominis muscle in women, and a wider inner inguinal ring in men.

During embryogenesis, migration of the gubernaculum does not occur. The upper portion of the gubernaculum in women forms the suspensory ligament of the ovary and the lower portion the round ligament of the uterus. Thus, the inguinal component of the gubernaculum remains in females as a round ligament, while it degenerates in males. The round ligament runs through the inner inguinal ring, through the inguinal canal, and ends in the fat of the labia majora or outside the outer inguinal ring without attachment or extension to the labrum. The internal inguinal ring is narrower in women, which explains the lower incidence of indirect inguinal hernia in women.

The ligamentous structure found within the inguinal hernia sac is often identified as the round ligament, however, histological examination identifies this structure as the suspensory ligament of the ovary, which helps to explain the occasional presence of the fallopian tube or ovary in the hernia sac in female patients. All cases of women that contain in their hernia contents any reproductive organs are considered cases of surgical emergency.

Clinically, Nuck's cyst presents as a palpable mass, usually non-reducible and painless, that protrudes from the inguinal region to the labia majora.

Due to the rarity of these types of cases, we present a 32-year-old female patient with this disorder who was admitted to our general surgery service, a residency program at the Maria Aparecida Pedrossian University Hospital.

CASE REPORT

E.C.S., a 32-year-old female, was admitted to the emergency room due to severe pain and nausea associated with a tumor in the inguinal region/left labrum majora with progressive growth that began approximately 6 hours after hospital admission. She also reported significant pain in the umbilical region associated with bulging, which she had

previously had and which worsened on exertion. He denies other associated symptoms. About 1 year and a half ago, she underwent bariatric surgery, with a significant weight loss of approximately 70kg (current weight: 77kg).

On physical examination, the patient was tearful, tachycardia, hypertensive, with important defense on physical examination, in which a tumor in the umbilical region was identified, which was manually reduced, and a tumor in the left inguinal region, which was not reducible.

He was chosen to undergo emergency surgery due to suspected strangulated inguinal/femoral hernia. The access was made through an oblique incision of approximately 30 centimeters at the level of the iliac crests in order to perform hygienic dermolipectomy and umbilical hernia repair in the same procedure. An indirect inguinal hernia was seen on the left (Nuck's canal) with protrusion of an encapsulated tumor with cystic content (Figures 1 and 2) adhered to two pedicles (Figure 3). The cyst was excised, sent to the anatomopathological examination and the left inguinal hernia was corrected with a polypropylene mesh. After the correction, umbilical hernia repair and dermolipectomy were performed. The patient evolved well after surgery and was discharged on the 3rd postoperative day.

Figure 1

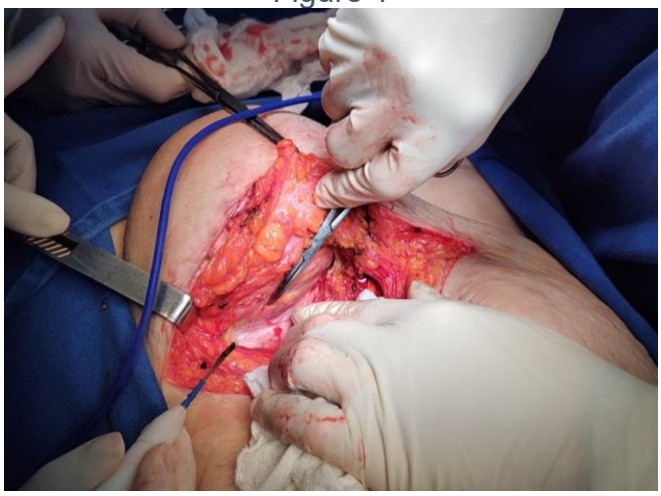

Figure 2



Figure 3



DISCUSSION

The diagnosis imposes difficulty both because of the rare incidence, affecting 1% of children and ranging from 5% to 12% in women with vulvar edema, and because of the clinical presentation that can mimic femoral hernia. In addition, the radiological evaluation is often inconclusive, with the anatomopathological evaluation being the gold standard.

CONCLUSION

Due to the rarity of finding a Nuck canal cyst, there is a lack of knowledge about this entity and a scarcity of relevant literature in surgical manuals. Therefore, establishing a definitive diagnosis only through history and clinical examination is quite challenging. Imaging studies can help in the preoperative diagnosis, but most cases are diagnosed in the surgical act or sometimes only in the pathologist's report.

REFERENCES

1. Nilsson, E., Kald, A., Anderberg, B., et al. (1997). Hernia surgery in a defined population: A prospective three year audit. *European Journal of Surgery, 163*, 823.

2. Rosen, A., Nathan, H., Luciansky, E., & Orda, R. (1989). The inguinal region: Anatomic differences in men and women with reference to hernia formation. *Acta Anatomica (Basel), 136*, 306.

3. Attah, A. A., & Hutson, J. M. (1991). The anatomy of the female gubernaculum is different from the male. *Australian and New Zealand Journal of Surgery, 61*, 380.

4. Ando, H., Kaneko, K., Ito, F., et al. (1997). Anatomy of the round ligament in female infants and children with an inguinal hernia. *British Journal of Surgery, 84*, 404.

5. Golash, V., & Cummins, R. S. (2005). Ovulating ovary in an inguinal hernia. *Surgeon, 3*, 48.

6. Gurer, A., Ozdogan, M., Ozlem, N., et al. (2006). Uncommon content in groin hernia sac. *Hernia, 10*, 152.

7. De Meulder, F., Wojciechowski, M., Hubens, G., & Ramet, J. (2006). Female hydrocele of the canal of Nuck: A case report. *European Journal of Pediatrics, 165*, 193.

8. Kark, A. E., & Kurzer, M. (2008). Groin hernias in women. *Hernia, 12*, 267.

9. Koch, A., Edwards, A., Haapaniemi, S., et al. (2005). Prospective evaluation of 6895 groin hernia repairs in women. *British Journal of Surgery, 92*, 1553.