LUMEN ET VIRTUS

EMERGENCY TREATMENT OF ACUTE PERIAPICAL ABSCESS IN EVOLUTION: REPORT OF A CLINICAL CASE

https://doi.org/10.56238/levv15n40-015

Rosana Maria Coelho Travassos[1], Glauco dos Santos Ferreira[2], Adriane Tenório Dourado Chaves[3], Marcela Agne Alves Valones[4], Andressa Cartaxo de Almeida[5], Maria Regina Almeida de Menezes[6], Pedro Guimarães Sampaio Trajano dos Santos[7], Ailton Coelho de Ataíde Filho[8], Eudoro de Queiroz Marques Filho[9].

ABSTRACT

During emergency care, when the patient has pain, it is one of the main duties of the dental surgeon to promote pain relief to the patient. Acute apical abscess (AGA) is one of the most common causes found in urgent care. They are odontogenic infections, consisting mainly of anaerobic microorganisms, which lead to pain and/or edema, and have the potential to diffuse through the cortical bone, with eventual lethal consequences. The present study aims to describe the case report of drainage of an evolved acute periapical abscess and its respective treatment at the Primary Care Clinic II (CAB II) of the Faculty of Dentistry of Pernambuco - University of Pernambuco (FOP/UPE). Where the patient complained of spontaneous, pulsatile, localized pain and edema. Endodontic intervention is essential for immediate symptom relief, and there is no consensus in the literature that establishes a care protocol in these cases. Even though there is no requirement for standardization of the protocol for emergency care, we conclude that it is of great importance to conduct a procedure that performs the drainage of the abscess to avoid systemic compromise.

[1] ORCID: https://orcid.org/0000-0003-4148-1288
University of Pernambuco, Brazil
Email: rosana.travassos@upe.br
[2] ORCID: (https://orcid.org/0000-0002-6539-5424)
FACSETE - Sete Lagoas College
Email: glauco_sf@hotmail.com
[3] ORCID: https://orcid.org/0000-0003-4659-0117
University of Pernambuco, Brazil
Email: adrianedourado@gmail.com
[4] ORCID: https://orcid.org/0000-0002-1090-8894
University of Pernambuco, Brazil
E-mail:marcela.valones@upe.br
[5] ORCID: https://orcid.org/0000-0001-9896-6273
University of Pernambuco, Brazil
E-mail:andressa.cartaxo@upe.br
[6] ORCID: http://orcid.org/0000-0003-3012-3979
University of Pernambuco-Brazil
E-mail: regina.menezes@upe.br
[7] ORCID: https://orcid.org/0009-0001-5720-603X
Institution: Faculty of Dentistry of Recife
Email: pedroguimaraessampaio@gmail.com
[8] ORCID: https://orcid.org/0000-0002-8105-4259
Recife School of Dentistry, Brazil
E-mail: ailtonataide@hotmail.com
[9] ORCID: https://orcid.org/0000-0001-9794-0311
Recife School of Dentistry, Brazil
Email: eudoromarques@hotmail.com

Keywords: Endodontics, Periapical Abscess, Urgency, Drainage.

INTRODUCTION

Dental emergencies are related to clinical conditions associated with discomfort and significant pain, requiring immediate treatment (DE PAULA et al, 2014). These conditions include infectious diseases such as apical or periodontal abscesses and periocoronitis. In most cases, treatments are carried out through local measures associated or not with the prescription of antimicrobial (DE PAULA et al, 2014).

In the care of a dental emergency, it is possible to observe that most cases are due to diseases of the pulp and periapex, with pain being the most relevant symptom (MUNERATO, 2005). Pulp and periradicular pain correspond to 90% of emergency cases in dental offices. (LOPES, 2013).

De Paula et al (2014) conducted a survey of the medical records of a university dental emergency service. The authors observed that endodontic pain corresponds to 72.6%, and the most frequent diagnosis was acute apical abscess (12.6%), followed by total inflitrative pulpitis (12.2%), pulp necrosis (10.5%), pulp hyperemia (9.7%) and acute apical periodontitis (6.7%).

Acute periapical abscess arises as a result of the extension of an inflammatory process from the pulp to periapical tissues, accompanied by a purulent exudate (DE DEUS, 1976). Clinically characterized by spontaneous, localized, pulsatile, high-intensity pain; where the accumulation of pus, in addition to pressing on the periapical structures, can seek a drainage route through the periodontal ligament, the root canal or can do it intraosseously, often externalizing through a fistula. The presence of intraoral or extraoral edema can be observed and can also cause tooth mobility (CAMPOS, 1985; SILVA, 1989; DUARTE, 1992; TORTAMANO, 2004; BERGUER, 2002).

The primary treatment in the case of urgency of this lesion is the drainage of the purulent collection, requiring local and systemic measures. Opening of the coronary chamber, immediate neutralization, odontometry, foraminal overflow and filling with intracanal antiseptic medication are steps that consist of local treatment. For a good prognosis of local treatment, the tooth should be sealed with temporary cement (VIER-PELISSER, 2008). But in some cases where the root canal is not allowed to dry, some authors propose leaving the tooth open (DE DEUS, 1976; BERGER, 2002).

Considering the importance of the subject addressed, this study aims to perform a literature review on the definition, classification and treatment of acute periapical abscess, and to describe the case report of the drainage of an evolved acute periapical abscess and its respective treatment at the Primary Care Clinic II (CAB II) of the Faculty of Dentistry of Pernambuco - University of Pernambuco (FOP/UPE).

OBJECTIVES

OBJECTIVE: To present a case report on the drainage of an evolved acute periapical abscess and its respective treatment at the Primary Care Clinic II (CAB II) of the Faculty of Dentistry of Pernambuco - University of Pernambuco (FOP/UPE).

METHODOLOGY

The present study consists of a clinical case report in a patient of CAB II (Primary Care Clinic II), all the necessary terms were clarified and authorized by the patient, as well as it was necessary to obtain consent through the signing of the term of authorization for diagnosis and/or execution of the treatment of the University of Pernambuco - Faculty of Dentistry of Pernambuco (Appendix 1). Because it is an individual report arising from a care observation and not from a planned situation, where there is a project or previous objectives, there is no way to obtain approval from the Research Ethics Committee prior to its realization. However, the author must verify the ethical adequacy of the issues related to obtaining consent and preserving the patient's privacy (GOLDIM 2010). The information will be confidential, respecting the participant's privacy during and after the conclusion of the report (Annex 2). Such information may be disclosed in events or scientific publications, but preserving the identity of the same (Annex 3).

CASE REPORT

Patient H.J.G.S., male, 25 years old, single, born in Camaragibe, sought dental care at the Faculty of Dentistry of Pernambuco - FOP/UPE with the main complaint of "toothache and swelling". The patient reported that he did not remember the last time he had gone to the dentist. Then the evaluation was carried out at the Primary Care Clinic II. The patient signed a term of commitment allowing the care and publication of the clinical case. The patient was informed that he would not be identified by disclosing his name or by photographs that showed his full face.

During the anamnesis, vital signs were measured, with blood pressure of 120x100 mm Hg, heart rate of 95 beats/minute, respiratory rate of 20 breaths/minute and axillary temperature of 38° C. In the intraoral evaluation, a volumetric change was observed in the region of the upper central incisor on the right side (tooth 11). The alveolar mucosa of tooth 11 region was swollen and palpation was painful, characterizing a fluctuating edema and was diagnosed with an evolved acute dental alveolar abscess.

The pulp sensitivity test was performed with a cotton pellet sprayed with Endo Ice, applied to teeth 21 and 11. In tooth 21 the response was positive and proving tooth vitality,

while in tooth 11 the patient presented a negative response and could be diagnosed as pulp necrosis. In the palpation test, an edema in the alveolar mucosa of the region of tooth 11 caused by the lesion is observed, which presents a painful symptomatology on palpation. In the percussion test, it presents a positive response, and can relate the inflammation that the injury causes to the periodontal ligaments. With these answers to the tests, a diagnostic hypothesis of a periapical abscess is led.

The treatment plan referred to an emergency case, as it required immediate treatment since the patient had pain, swelling and was unable to perform his normal activities. The treatment performed was a drainage of the acute intraoral periapical abscess and through the tooth, seeking relief from the patient's pain.

FIRST PHASE OF TREATMENT

The pre-surgical procedure performed was the use of medications, 01 (one) hour before surgery: 2 g of amoxicillin (Amoxil®) and 500 mg of sodium dipyrone (Anador®). This was followed by infiltrative anesthesia by anterior superior alveolar nerve block with 2% lidocaine and adrenaline 1:100,000 at the bottom of the vestibule of the right upper central incisor region 11.

Photograph 1: Infiltrative anesthesia due to superior alveolar nerve block

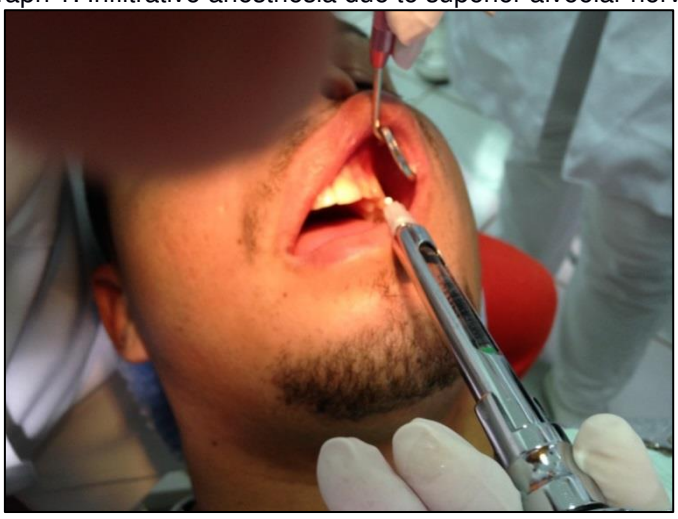

After anesthesia, absolute isolation and coronary opening were performed with a number 1015 spherical drill, and irrigation was performed with 2.5% sodium hypochlorite. The cervical and middle preparation was performed with Gates Glidden drills numbers: 6-5-4 and following, the apex crown preparation with K-File type files numbers: 80-70-60-55-50. The latter arrived at the apparent length of the tooth and odontometry was performed and the actual length of the tooth was determined: 24 mm and the actual working length: 23 mm. The foraminal instrument was used with the following files: 40-45. Once this stage was

completed, the root canal was filled with Ultrcal - ULTRADENT - (calcium hydroxide) and the coronary sealing was performed with Glass Ionomer.

SECOND PHASE: SURGICAL DRAINAGE

In the local treatment, we made an incision with a 15c scalpel blade at the most fluctuating point of the alveolar mucosa, with the buccal of tooth 11 (Figure 3). With curved hemostatic forceps of the Halstead type, mucosal divulsion was performed followed by drainage of the site for pus leakage.

Photo 02: Absolute isolation and coronary opening

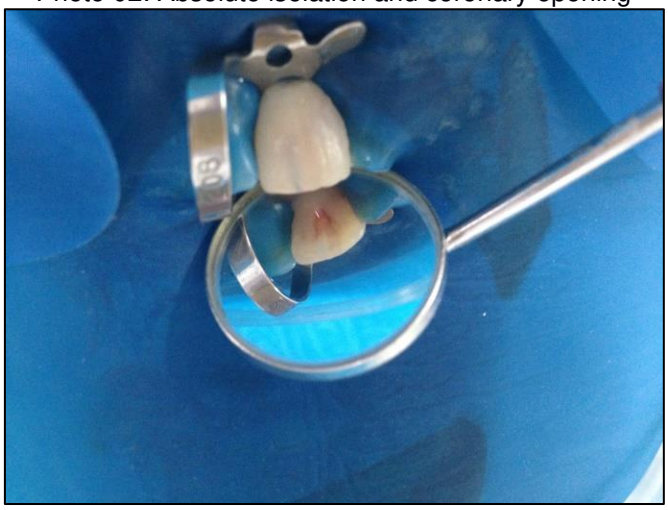

Photographs 3 and 4: Incision at the most floating point

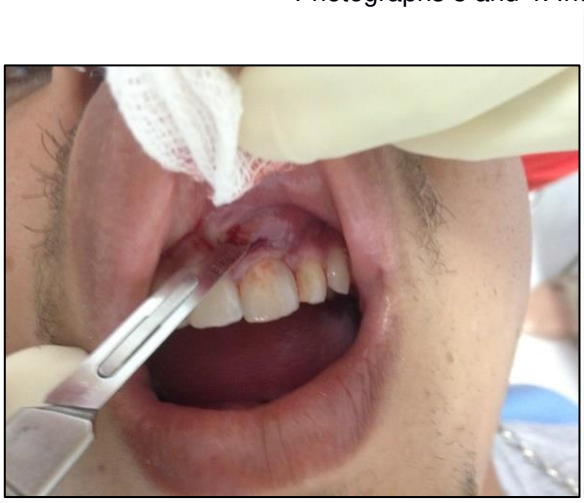



After the extravasation of all the pus, a flexible rubber drain was placed inside the soft tissues and fixed with suture in the alveolar mucosa by simple interrupted stitches with 3-0 silk thread.

Figure 5: Drain suture



The patient was recommended to continue the systemic medication in the postoperative period: 500 mg of Amoxicillin (Amoxil®) every 8 hours for 7 days, and 500 mg of sodium dipyrone (Anador®) every 4 hours for 2 days and gentle mouthwash 3 times a day with 0.12% chlorhexidine digluconate for 7 days.

The patient was referred to return one week after the emergency room to the Primary Care Clinic II, for suture removal and after 20 days for root canal filling and definitive restoration with composite resin.

DISCUSSION

Acute dental abscesses originate from chronic odontogenic infections such as caries, pulp necrosis, periodontal disease, periapical injury, postoperative surgery, trauma or after manipulation of the root canal (SILVÉRIO, 2002; SIQUEIRA, 2002; ROSSI, 2002; RICIERI, 2007). The origin and location of abscesses are criteria taken into account to classify them into periapical (endodontic) abscesses or periodontal abscesses; and by its evolution in acute or chronic (ROSSI, 2002). Acute periapical abscesses are the result of when an infection of the pulp extends to the periapical tissues, being characterized by spontaneous and pulsatile pain, edema, tooth mobility and the accumulation of pus pressing on the adjacent periapical structures. The abscess becomes chronic when drainage occurs via the canal, the periodontal ligament or the transosseous route, often externalizing through fistula (CAMPOS, 1985; SILVA et al, 1989; DUARTE et al, 1992; TORTAMANO et al, 2004). In relation to acute periodontal abscess, it is a purulent collection located within the gingival wall of a periodontal pocket, resulting from an acute destructive inflammatory process. As a clinical characteristic, it presents pulsatile pain, increased tooth mobility, reddish, smooth and shiny swelling. It is also considered a chronic when drainage occurs through a fistula or through the periodontal pocket itself (SILVÉRIO, 2002; ROSSI, 2002; DURO et al, 2000).

It should therefore be considered that the endodontic microbiota normally changes according to the time of infection and may also differ according to the type of periapical disease. Since chronic periapical lesions have a greater variety of bacterial species, symptomatic periapical lesions such as acute apical periodontitis and acute periapical abscess are associated with a smaller number of species (NAIR, 2004; RÔÇAS et al, 2001; SIQUEIRA et al, 2001). The microorganisms present in acute periapical abscesses are complex, with a predominance of approximately 90% of gram-negative anaerobic bacilli and gram-positive anaerobic cocci (Sousa, 2000, 2003; Montagner, 2010). The concomitant presence of facultative anaerobes will aggravate the clinical picture of acute to severe abscesses, due to facultatives using oxygen, preparing the ecosystem for the installation of strict anaerobic abscesses (Gomes, 1995; Sousa, 2000, 2003; Montagner, 2010; Sousa et al., 2003. Among the species found in acute periapical abscesses are the anaerobic species Prevotella spp., Porphyromomas spp., Parvimonas micra, Fusobacterium nucleatum, Fusobacterium necrophorum, Tannerella forsythia, Dialister pneumosintes, and facultatives belonging to the genus *Streptococcus* (Montagner, 2010; Gomes *et al*., in press). The species of Porphyromonas, Prevotella, Peptostreptococcus, Fusobacterium and Eeubacterium are associated with increased incidence of symptoms (BERGENHOLTZ, 2003). Another factor related to the worsening of the acute condition is host resistance (LOPES, 2013).

According to the degree of evolution of odontogenic infections, the treatment may be only a conventional endodontic treatment or when the patient delays seeking the dentist, they become more complex and require the administration of antibiotics and procedures such as incision and/or drainage, often extra-oral (CORRÁ et al., 2010). By identifying the cause and removing it as soon as possible, it is possible to obtain a considerable improvement in the signs and symptoms of the infection, suggesting that it should always be followed by drainage of the purulent collection (PETERSON, 2000). Surgical drainage is a form of intervention with the purpose of promoting the relief of abscess symptoms through the drainage of purulent exudate (DE DEUS, 1976). The incisions can be intraoral or extraoral, trying to choose areas where aesthetics are not so compromised, so it is of great value that the professional obtains anatomical knowledge of the area to be operated on and the minimum tensions of the face. Drainage should be performed at the point of greatest fluctuation and as esthetic as possible, always following the divulsion of vascular and nervous tissues, muscles and structure (PETERSON, 2000).

In the case reported as stowage swelling in the intraoral region, an incision is made in the mucosa. The incision was made after the intervention in the canal, because the pain

that bothers the patient will be reduced with the reduction of existing pressure, thus making the patient more comfortable to perform the coronary access and chemical-mechanical preparation procedures. The incision, according to the protocol, can only occur if the tissues are soft and floating, and the incision site is at the most central point.

Clinically characterized by spontaneous, localized, pulsatile and high-intensity pain; where the accumulation of pus, in addition to pressing on the periapical structures, can seek a drainage route through the periodontal ligament, the root canal or can do so intraosseously, often externalizing through fistula. The presence of intraoral or extraoral edema can be observed and can also cause tooth mobility (CAMPOS, 1985; SILVA, 1989; DUARTE, 1992; TORTAMANO, 2004; BERGUER, 2002). As the cause of periapical pain is of infectious origin, it is necessary to immediately remove the cause of the infection and eliminate the presence of bacteria from inside the root canal system. Thus, the coronary chamber was opened, immediate neutralization, odontometry, foraminal overflow, filling with antiseptic intracanal medication and sealing of the dental element were performed. For a good prognosis of local treatment, the tooth should be sealed with temporary cement. After the acute phase of periapical abscess is overcome, conventional endodontic treatment is performed.

CONCLUSIONS

The clinical case described here demonstrates that the proper management of periapical abscess can avoid systemic impairments.

REFERENCES

1. Bergenholtz, G., Horsted-Bindslev, P., & Reit, C. (2006). Endodontia. Rio de Janeiro: Guanabara Koogan.

2. Campos, G. M. (1985). Processos inflamatórios agudos da polpa e região periapical: minicurso. Odontologia Moderna, 12(4), 53-66.

3. Consolaro, A., & Ribeiro, F. C. (Eds.). (1998). Periapicopatias: etiopatogenia e inter-relações dos aspectos clínicos, radiográficos e microscópicos e suas implicações terapêuticas. In M. R. Leonardo & J. M. Leal (Eds.), Endodontia: Tratamento de Canais Radiculares (3rd ed.). São Paulo: Panamericana.

4. Corrá, L. M. C., Corra, A. F. C., Nicolau, R. A., & Frois, I. (2010). Drenagem abscesso periapical extra-oral. In XIV Encontro Latino Americano de Iniciação Científica, São José dos Campos. Univap Virtual. 1, 1-5.

5. De Deus, Q. D. (1992). Endodontia (5th ed.). Rio de Janeiro: Medsi.

6. De Deus, Q. D. (1976). Endodontia (2nd ed.). Rio de Janeiro: Guanabara Koogan.

7. De Paula, K., Silveira, L., Fagundes, G., Ferreira, M. B., & Montagner, F. (2014). Patient automedication and professional prescription pattern in an urgency service in Brazil. Braz. Oral Res., 28(1), 1-6.

8. Duarte, C. A., & Lico, D. A. (1992). Diagnóstico diferencial e tratamento dos abscessos periodontal e periapical agudo. ROBRAC, 2(1), 15-17.

9. Duro Júnior, A. M., Joly, J. C., Palioto, D. B., & Lima, A. F. M. (2000). Abscessos periodontais múltiplos: relato de caso clínico. J. Br. Endod., 1(2), 40-44.

10. Estrela, C. (2004). Ciência Endodôntica. São Paulo: Artes Médicas.

11. Fachin, E. V. F., Luisi, S. B., & Borba, M. G. (2001). Relação pulpo-periodontal: considerações histológicas e clínicas. Rev. Fac. Odontol. Porto Alegre, 42(1), 9-15.

12. Gomes, B. P. F. A., Montagner, F., & Martinho, F. C. Aspectos microbiológicos das infecções endodônticas: conceitos e aplicações. In S. T. Moysés, L. Kriger, & S. Moysés (Eds.), Microbiologia / Imunologia Geral e Odontológica. São Paulo: Artes Médicas, in press.

13. Guimarães Junior, J. (1989). O problema do diagnóstico diferencial das periapicopatias radiolucentes. Rev. Assoc. Paul. Cir. Dent., 43(5), 251-254.

14. Lewis, M. A., Macfarlane, T. W., & McGowan, D. A. (1990). A microbiological and clinical review of the acute dentoalveolar abscess. Br. J. Oral Maxillofac. Surg., 28, 359-366.

15. Lopes, H. P. (2013). Endodontia: biologia e técnica (3rd ed.). Rio de Janeiro: Guanabara Koogan.

16. Matthews, D. C., Sutherland, S., & Basrani, B. (2003). Emergency management of acute apical abscess in permanent dentition: a systematic review of the literature. J. Can. Assoc., 69(10), 660-660i.

17. Montagner, F. (2010). Comunidades microbianas em canais radiculares e abscessos periapicais agudos e suscetibilidade de algumas bactérias anaeróbias estritas isoladas. (Doctoral dissertation). Universidade Estadual de Campinas, Piracicaba.

18. Moreira, D. M. (2005). Conduta clínica e terapêutica de abscessos periapicais agudos. (Specialization monograph). Universidade Estadual de Campinas, Piracicaba.

19. Munerato, M. C., Fiaminghi, D. L., & Petry, P. C. (2005). Urgências em odontologia: um estudo retrospectivo. Rev. Fac. Odonto. Porto Alegre, 46(1), 90-95.

20. Nair, P. N. R. (2004). Pathogenesis of apical periodontitis and the causes of endodontic failure. Crit. Rev. Oral Biol. Med., 15(6), 348-381.

21. Neville, B. W., Damm, D. D., Allen, C. M., & Bouquot, J. E. (2008). Patologia oral & maxilofacial (2nd ed.). Rio de Janeiro: Guanabara Koogan.

22. Peterson, L. J. (2000). Cirurgia Oral e Maxilofacial Contemporânea. Rio de Janeiro: Guanabara Koogan.

23. Ricieri, C. B., Gulinelli, J. L., Silva, J. L., & Garcia, I. R. J. (2007). Infecções odontogênicas e suas complicações. Rev. Odontol. Araçatuba, 28(1), 44-48.

24. Rossi, G. H. (2002). Abscesos periodontais e apicais: seu diagnóstico diferencial. Ver. Asoc. Odontol. Argent., 90(1), 48-53.

25. Rôças, I. N., Siqueira, J. F., Santos, K. R., Coelho, A. M., & de Janeiro, R. (2001). “Red complex” (Bacteroides forsythus, Porphyromonas gingivalis, and Treponema denticola) in endodontic infections: a molecular approach. Oral Surg. Oral Med. Oral Pathol. Oral Radiol. Endod., 91(4), 468-471.

26. Silva, P. J., Costa, A. S., & Cavalcante, A. M. (1989). Abscesso dento-alveolar agudo: contribuição ao estudo do tratamento clínico e cirúrgico. Rev. Gauch. Odontol., 37(2), 97-102.

27. Silvério, K. G., Rego, R. O. C. C., & Toledo, B. E. C. (2002). Diagnóstico diferencial entre abscesso endodôntico e periodontal. J. Br. Endod., 3(10), 251-254.

28. Siqueira, J. F., Rôças, I. N., Souto, R., de Uzeda, M., & Colombo, A. P. (2001). Microbiological evaluation of acute periradicular abscesses by DNA-DNA hybridization. Oral Surg. Oral Med. Oral Pathol. Oral Radiol. Endod., 92(4), 451-457.

29. Siqueira, J. R., & Rôças, I. N. (2013). Microbiology and treatment of acute apical abscess. Clin. Microbiol. Rev., 26(2), 255-273.

30. Siqueira, S. R. D. T., & Siqueira, J. T. T. (2002). Infecções odontogênicas agudas: discussão de casos. BCI, 9(33), 16-20.

31. Sousa, E. L. R., Gomes, B. P. F. A., Jacinto, R. J., Zaia, A. A., & Ferraz, C. C. R. (in press). Microbiological profile and antimicrobial susceptibility pattern of infected root canals associated with periapical abscesses. Eur. J. Clin. Microbiol. Infect. Dis.

32. Sousa, E. L. R. (2003). Análise microbiológica de canais radiculares associados a abscessos periapicais e a suscetibilidade de bactérias anaeróbias prevalentes frente a diversos antibióticos. (Doctoral dissertation). Universidade Estadual de Campinas, Piracicaba.

33. Sousa, E. L. R. (2000). Estudo bacteriológico de canais radiculares associados a abscessos periapicais. (Master's thesis). Universidade Estadual de Campinas, Piracicaba.

34. Souza-Filho, F. J., Gomes, B. P. F. A., Ferraz, C. C. R., Teixeira, F. B., & Zaia, A. A. (2002). Drenagem de abscessos periapicais. In R. J. Alves & E. A. N. Gonçalves (Eds.), Endodontia e Trauma (1st ed., Vol. 2, pp. 113-131). São Paulo: Artes Médicas.

35. Takahashi, K. (1998). Microbiological, pathological, inflammatory, immunological and molecular biological aspects of periradicular disease. Int. Endod. J., 31(5), 311-325.

36. Torabinejad, M., & Walton, R. E. (1989). Endodontic emergencies. In R. E. Walton & M. Torabinejad (Eds.), Principles and Practice of Endodontics (pp. 283-294). Philadelphia: WB Saunders.

37. Tortamano, I. P., Costa, C. G., Moraes, L. J., Borsatti, M. A., Rocha, R. G., & Tortamano, N. (2004). As urgências odontológicas e o tratamento clínico e medicamentoso integrado. J. Br. Cir., 8(43), 78-85.

38. Trowbridge, H. O., & Stevens, B. H. (1992). Microbiologic and pathologic aspects of pulpal and periapical disease. Curr. Opin. Dent., 2, 85-92.

39. Vier-Pelisser, F. V., Garbin, R. P., Só, M. V. R., Marca, C., & Pelisser, A. (2008). Medicação intracanal e sistêmica e preconizada nas faculdades de Odontologia brasileira para o tratamento de urgência do abcesso apical agudo. Rev. Odonto. Ciência, 23(4), 278-282.

40. Weine, F. S. (1998). Tratamento Endodôntico (5th ed.). São Paulo: Santos.