LUMEN ET VIRTUS
ISSN: 2177-2789

ROSAI-DORFMAN'S DISEASE IN THE GREATER SALIVARY GLAND: A CASE REPORT

https://doi.org/10.56238/levv16n45-066

Submitted on: 28/01/2025 **Publication date:** 28/02/2025

Wires Samuel Barbosa Santos[1] and Thiago David Alves Pinto[2]

ABSTRACT

Rosai-Dorfman Disease (DRD), also known as sinus histiocytosis with massive lymphadenopathy, is a pathology of uncertain, rare, and challenging biological potential, characterized by the proliferation of S100-positive histiocytes and the phenomenon of emperipolesis, where intact cells, such as lymphocytes, are found in the cytoplasm of these histiocytes. Although classically described as a nodal disease, DKD can manifest in extranodal sites, and the involvement of the salivary glands, especially in isolation, is extremely uncommon. In many cases, the disease is self-limiting, resolving spontaneously without the need for specific treatment. This report describes a rare case of DKD with exclusive involvement of the left submandibular gland in a 41-year-old female patient who presented with a submandibular mass with no other symptoms. After a surgical excision procedure, the diagnosis was confirmed by histopathological and immunohistochemical examinations, which revealed histiocytosis with emperipolesis and positivity for S100, CD68 and HAM56. The details of this case contribute to the understanding of DKD in extranodal sites, expanding the clinical-pathological spectrum of this rare entity.

Keywords: Rosai-Dorfman disease. Emperipolesis. Submandibular Gland. Extranodal Disease. Differential Diagnoses.

[1] E-mail: wsamuelap@gmail.com
[2] Prof. and Dr.
Advisor

INTRODUCTION

Rosai-Dorfman disease (DRD), or sinus histiocytosis with massive lymphadenopathy (HSLM), was first described by Pierre-Paul Destombes in 1965.[1] In 1969, Juan Rosai and Ronald Dorfman reported four cases and coined the term "sinus histiocytosis with massive lymphadenopathy", consolidating the entity in 1972 with the analysis of 34 cases.[2] Subsequently, in 1990, with the assistance of Elliott Foucar, knowledge about the clinical and pathological spectrum of DKD, including its extranodal manifestations, was expanded.[1] Although the term HSLM was initially adopted, it does not adequately reflect the nature of DKD, which can affect extranodal sites. Thus, the designation "Rosai-Dorfman Disease" has become the most widely used due to its practicality and comprehensiveness. Alternative names, such as "Destombes-Rosai-Dorfman disease", are still occasionally used.[3] DKD is characterized by the accumulation of histiocytes/large macrophages, with expression of the S100 protein by immunohistochemical study, often associated with the phenomenon of emperipolesis. This phenomenon consists of the presence of viable cells, such as lymphocytes, plasma cells, or red blood cells, within the cytoplasm of histiocytes, within intracytoplasmic vacuoles that protect them from cytolytic enzymes.[1-4]

Clinically, nodal disease presents more frequently in the second and third decades of life3, but it can affect from neonates to the elderly. The classic picture involves bilateral, painless, and bulky cervical lymphadenopathy, accompanied or not by fever, weight loss, night sweats, and malaise. Other lymph node groups, such as axillary, mediastinal, and inguinal groups, may also be affected, whereas retroperitoneal involvement is rare.[5,6] In about 20% of patients, multiple systems are involved, which makes the number of extranodal sites affected a relevant prognostic factor.[5] Extranodal involvement occurs in approximately 43% of cases of Rosai-Dorfman disease, with about 75% of these located in the head and neck region, such as the orbit, nasal cavity and paranasal sinuses.[7] Although salivary glands may rarely be affected,3 there are no precise data on their frequency due to the scarcity of detailed studies and the difficulty in differentiating between true extranodal disease and intrassalivary lymph node involvement.[7] According to the authors Peng Chen et al (2023), only eight cases of DKD involvement have been described in this topography.[8]

The etiology of DRK remains unknown. Hypotheses suggest that its pathogenesis may be related to an infectious agent not yet identified or to an altered immune response.[7] Rare familial cases are associated with germline mutations in genes such as *SLC29A3* (H syndrome) and *FAS* (autoimmune lymphoproliferative syndrome). However, the relationship of these mutations with the sporadic form of the disease is not clear.[3] Recent advances in the molecular understanding of DKD point to mutations in the MAPK/ERK pathway, such as

in *KRAS* and *MAP2K1*, present in about one third of cases. These alterations, in addition to contributing to the pathogenesis of the disease, indicating its neoplastic character, have important therapeutic implications, suggesting that MEK inhibitors may represent a promising option for refractory cases or cases with multifocal involvement.[4]

Differential diagnoses may include reactive lymphadenopathy, infectious diseases, IgG4-related lymphadenopathy, Langerhans cell histiocytosis (LCH), Hodgkin lymphoma (HL), anaplastic large cell lymphoma (LAGC), Kikuchi-Fujimoto disease (KDF)[1,9,] and hemophagocytic lymphohistiocytosis (HLH)[10], whose main characteristics are summarized in Chart 1.

Chart 1 - Differential diagnoses - details in the text.

Sickness	Key features	Differential
LR	Benign lymph node enlargement.	Without emperipolesis; few histiocytes S100+.
Infectious diseases	Granulomas, caseous necrosis.	Positive tests for infectious agents.
IgG4-related lymphadenopathy	Storiform fibrosis, IgG4+ plasma cells.	High IgG4/IgG ratio; without emporipolesis.
HCL	Langerhans cells (CD1a+, langerin+).	DRD is CD1a- and without Birbeck granules.
LH	Reed-Sternberg cells (CD15+, CD30+).	DRD is CD15- and CD30-. Typical LH cells missing.
LAGC	Large cells, CD30+, some cases ALK+.	DKD is CD30-, ALK-, with histiocytic pattern without anaplasia
DKF	Coagulative necrosis, histiocytes in "increasing".	DRK without coagulative necrosis.
LHH	Erythrophagocytosis, persistent fever.	DRD is S100+ and LHH S100-/+.

Source: own (2025). **Legend:** LR: Reactive Lymphadenopathy; HCL: Langerhans cell histiocytosis; LH: Hodgkin's lymphoma; LAGC: Anaplastic Large Cell Lymphoma; DKF: Kikuchi-Fujimoto disease; HLH: Hemophagocytic lymphohistiocytosis; -/+: negative or weakly positive.

Reactive sinus histiocytosis does not present emperipolesis, a hallmark of DKD, and S100-positive cells are scarce.[1] In IgG4-related lymphadenopathy, IgG4-positive plasma cells may be abundant, but S100-positive histiocytes with emperipolesis are absent, and the predominant alteration is storiform fibrosis, which may exhibit phlebitis obliterans. In addition, DKD cases have a significantly lower number of IgG4-positive plasma cells and a reduced IgG4/IgG ratio compared to IgG4-related disease, with these values being similar to those seen in reactive lymph nodes. This difference is an important criterion in distinguishing between the two conditions.[11] Although LCH is S100-positive and has reported a case with the presence of eosinophil emperipolesis[1], it is distinguished by the presence of Birbeck granules, CD1a expression and langerin.[12-15] Considering that, in DKD, some histiocytes and immunoblasts may present an increase in size and a certain reactive atypia, it is essential to exclude Hodgkin's lymphomas and LAGC, in which markers such as

CD15, CD30 and ALK help in distinguishing[1], whereas DKF, which may also exhibit cervical lymphadenopathy, is differentiated by the presence of paracortical areas with coagulative necrosis associated with abundant cariorrhetic debris associated with histiocytes exclusively CD68-positive and plasmacytoid dendritic cell clusters, in addition to "crescent" histiocytes.[16,17] In HLH, prominent histiocytic infiltration with erythrophagocytosis and constitutional symptoms, such as persistent fever, are observed.[10,18] In addition, DKD presents evident immunostaining of the S-100 protein, on the other hand, in HLH, histiocytes are negative or weakly positive.[19]

Imaging findings of extranodal DKKD are nonspecific and often mimic malignancy. On magnetic resonance imaging, the lesions present hyperintense signal on T2-weighted sequences, with variable contrast enhancement, whereas ultrasonography can reveal complex masses without definitive diagnostic features.[20] Laboratory abnormalities are also common in patients with DKD, usually presenting with polyclonal hypergammaglobulinemia, increased erythrocyte sedimentation rate, and normochromic normocytic anemia. Other findings include hypoalbuminemia and leukocytosis in a portion of cases. In addition, approximately 10% of patients with DKD have associated immune disorders, such as asthma, systemic lupus erythematosus, and juvenile arthritis, which may precede or arise concomitantly with diagnosis.[1]

Although DKD is considered a self-limiting condition in many cases, the management of patients with multifocal or refractory forms remains a challenge. The therapeutic approach includes observation in asymptomatic cases, surgical resection for localized lesions, and use of corticosteroids to reduce symptoms in more widespread diseases.[5] In severe cases, immunomodulatory agents, chemotherapy agents, and targeted therapies, such as MAPK pathway inhibitors, have been used with variable results. Investigation of somatic mutations in genes such as *KRAS* and *MAP2K1* can guide treatment and allow for a personalized approach.[21,22] Approximately 50% of patients have complete resolution of the disease without the need for intervention.[22]

Chart 2 summarizes the main findings of the disease, based on the information available in the literature.

Chart 2 - Main findings of Rosai-Dorfman disease.

Aspect	Description
Definition	Sinus histiocytosis with massive lymphadenopathy - large, S100-positive histiocytes and emperipolesis.
Epidemiology	2nd and 3rd decades of life, cases described from neonates to the elderly.
Nodal shape	Lymphadenopathy, particularly cervical and usually slow-growing and painless.

Extranodal form	43% of cases, mainly head and neck. Salivary gland involvement is rare.
Prognostic factors	The extent of extranodal involvement represents a relevant prognostic factor.
Aetiology	Unknown. Familial cases may have mutations in *SLC29A3* and *FAS*.
Molecular changes	Mutations in the MAPK/ERK pathway (*KRAS, MAP2K1*) in 1/3 of the cases suggest neoplastic character.
Differential diagnosis	LR, infectious diseases, IgG4-related lymphadenopathy, HCL, LH, LAGC, DKF, and HLH.
Laboratory tests	Polyclonal hypergammaglobulinemia, elevated ESR, normocytic/normochromic anemia, hypoalbuminemia, and leukocytosis.
Imaging findings	Nonspecific. MRI: hyperintense lesions on T2-weighted sequences, with variable contrast enhancement. USG may show complex masses.
Treatment	From observation, surgical resection and/or corticosteroids to immunomodulators, chemotherapy or MAPK inhibitors depending on the extent and severity.
Prognosis	About 50% of cases have complete spontaneous resolution, while others persist or recur, and may require excision, radiotherapy, or chemotherapy.

Legend: LR: Reactive Lymphadenopathy; HCL: Langerhans cell histiocytosis; LH: Hodgkin's lymphoma; LAGC: Anaplastic Large Cell Lymphoma; DKF: Kikuchi-Fujimoto disease; HLH: Hemophagocytic lymphohistiocytosis; ESR: erythrocyte sedimentation rate; MRI: Magnetic Resonance Imaging; USG: Ultrasonography. Source: own (2025).

Because it is a rare disease with low prevalence, DKD often presents clinical and morphological manifestations that defy diagnosis, especially in extranodal locations. Describing an unusual presentation, such as in larger salivary glands, represents not only an opportunity to broaden the understanding of the clinical-pathological spectrum of the disease, but also to offer subsidies to improve the recognition of its diagnostic aspects.

CASE REPORT

A 41-year-old female patient, previously healthy, complained of a progressive growth mass in the left submandibular region, associated with mild local discomfort. There were no reports of systemic symptoms such as fever, weight loss, or hematological changes. The initial evaluation included clinical examination, which revealed a mass not adhered to deep planes, with a firm consistency, with no signs of regional lymph node enlargement or skin changes.

In view of the persistence of the lesion and its progressive growth, the patient underwent ultrasonography (Figure 1), which identified a hypoechoic and heterogeneous nodular image in the left submandibular gland, with an aspect that was not specific to the method. For better diagnostic elucidation, fine-needle aspiration puncture (FNA) was performed, whose cytopathological examination suggested salivary gland neoplasm of

uncertain malignant potential. Considering the diagnostic uncertainty, we opted for surgical excision of the submandibular gland, followed by intraoperative frozen section examination, with the objective of evaluating the aggressiveness of the lesion and determining the need to expand the surgical procedure in the first surgical procedure.

Figure 1: Image showing a 17 x 17 x 13 mm nodule in the left submandibular gland on ultrasound. Source: own (2024).

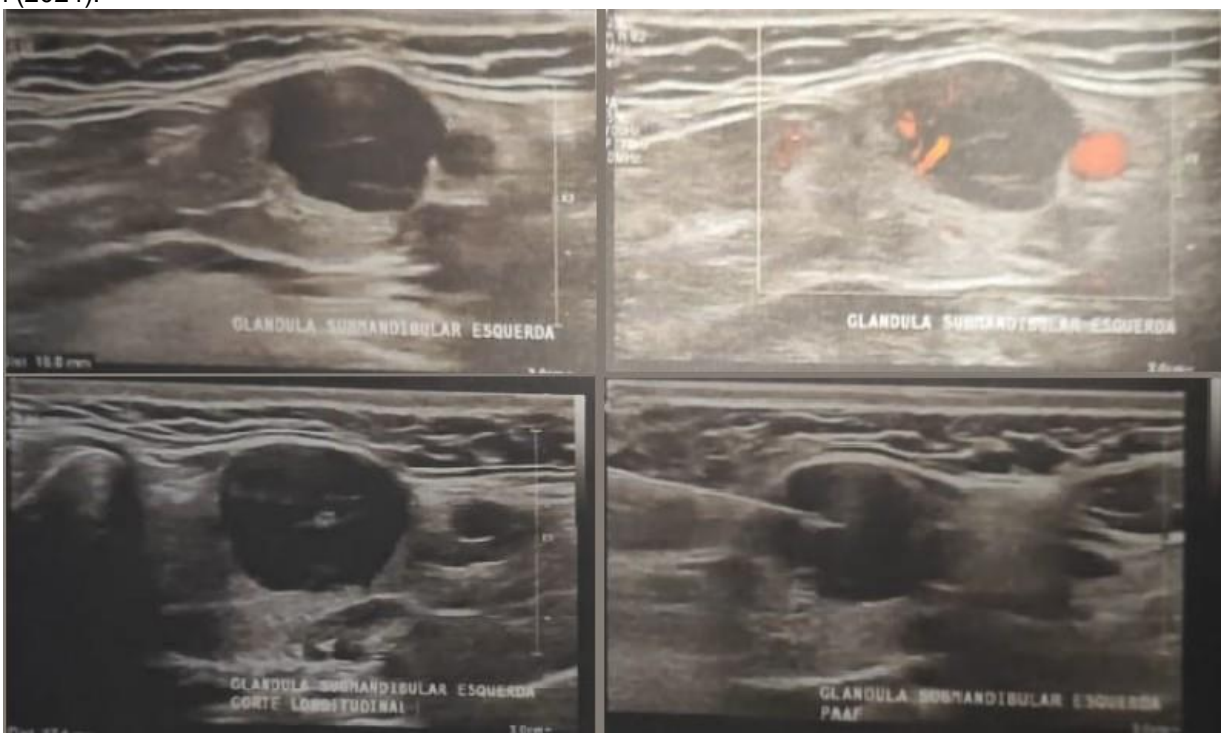

CYTOPATHOLOGICAL EXAMINATION AND FROZEN SECTION

The patient was initially submitted to fine-needle aspiration puncture (FNA), whose cytopathological examination revealed cellularity composed of epithelial cells organized in small blocks, some of which had slightly irregular hyperchromatic nuclei and a broad, sometimes clear eosinophilic cytoplasm. In the cell block, there is also a small group of columnar cells with a large cytoplasm, with a mucinous aspect, in addition to glandular acini without atypia. The background of the sample was hemorrhagic, containing numerous lymphocytes. Thus, these findings resulted in a report compatible with salivary gland neoplasm of uncertain malignant potential (Milan System - Category IVB).

In view of the need for a definitive diagnosis, the lesion in the left submandibular gland was completely excised. Oncotic cytology in the intraoperative act ("imprint") of the resected material did not reveal unequivocal signs of malignancy, but identified an inflammatory component permeating structures of the salivary parenchyma. The initial impression favored lymphadadenoma or a correlated inflammatory lesion.

MACROSCOPIC EXAMINATION

The material consisted of an irregular fragment of tissue measuring 3.5 x 3.0 x 2.0 cm, containing a nodule measuring 1.9 x 1.7 x 1.5 cm. The cutting surface was yellowish and lobed, with adjacent fibroelastic tissue.

HISTOPATHOLOGICAL EXAMINATION

Histological sections revealed a greater submandibular gland of the seromucinous type, containing a nodular structure (Figure 2a) composed of histiocytoid/oncocytoid cells with broad and eosinophilic cytoplasm (Figure 2b).

Figure 2: A : Histological section (40x) of the seromuminous submandibular gland with altered architecture in the upper right region. B: detail (100x) showing expansive proliferation of histiocytoid cells permeating the parenchyma of the salivary gland. Hematoxylin-eosin staining. Source: own (2025).

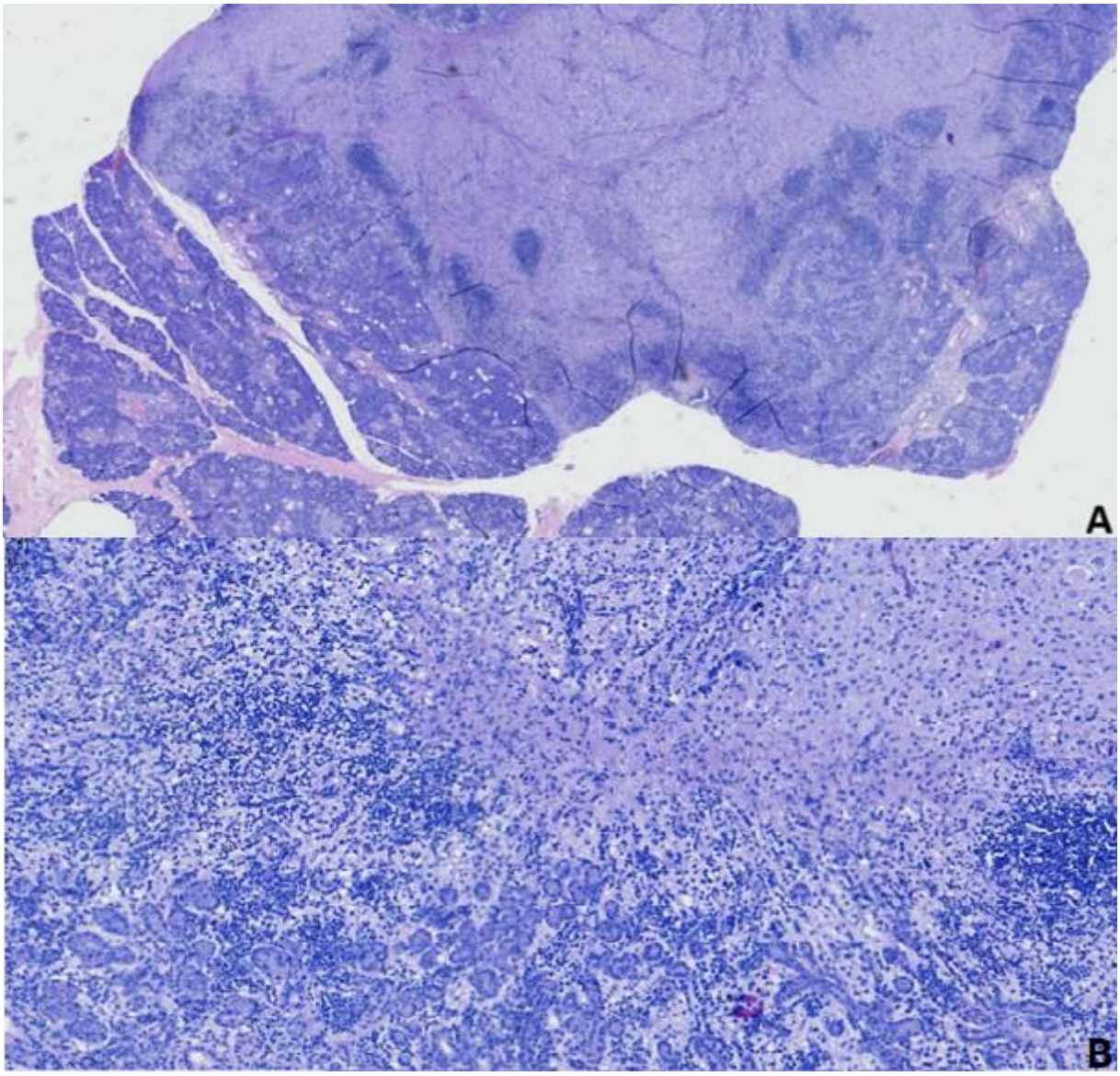

The nuclei were round to oval, with finely distributed chromatin and evident nucleoli. In foci, small intact lymphocytes are observed in the cytoplasm of the cells, which characterizes emperipolesis (Figure 2). The dense and extensive lymphoplasmacytic inflammatory infiltrate involved ducts and acini of the salivary gland in the periphery of the lesion. There was no necrosis, mitosis or malignant characteristics. There were no unequivocal signs of lymph node parenchyma that could characterize intraglandular lymph node involvement. The surgical margins were free.

Figure 3: Histological slice (400x magnification) showing lymphocyte emperipolesis (arrow). Hematoxylin-eosin staining. Source: own (2025).

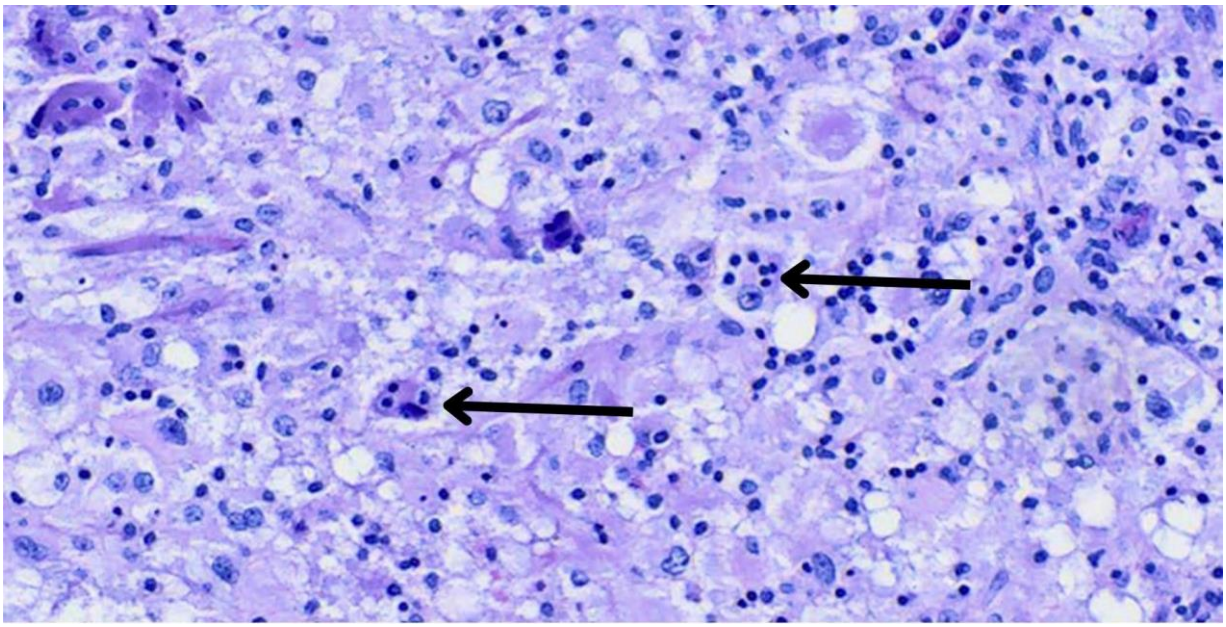

IMMUNOHISTOCHEMISTRY

The histological slides, obtained from the material processed in paraffin blocks, were submitted to antigen retrieval protocols, followed by incubation with specific monoclonal and polyclonal antibodies. The detection was carried out using a polymer-based system, with the aid of high-precision automated platforms, with external histological controls, ensuring consistent and reliable results. The histiocytoid/oncocytoid cells were positive for the markers S100 (polyclonal, Figure 3a), CD68 (clone KP1, Figure 3b) and histiocyte marker, clone HAM56 (Figure 3c), concluding that they are S100-expressing histiocytes. In addition, lymphocyte emperipolesis can be observed in greater detail on S100 immunostaining (Figure 4a). Immunostaining was negative for CD1a (clone 010), cytokeratins, SOX10 (clone BC34) and DOG1 (clone SP31), disfavoring HCL and oncocytoid epithelial lesions of the salivary gland. Staining of the common leukocyte antigen, CD45 (clone 2B11 and PD7/26), exhibited membranous and cytoplasmic staining of the histiocytes and

lymphocytes encompassed, reinforcing the hematological origin. The cell proliferation index at Ki-67 (MIB-1 clone) was 3%, reinforcing the indolent behavior of the lesion (Figure 4b).

Figure 4: A : S100 immunomarker positive in histiocytoid/oncocytoid cells (40x magnification); B: CD68 immunomarker marking histiocytoid/oncocytoid cells (200x magnification); C: HAM56 immunomarker marking histiocytoid/oncocytoid cells (200x magnification). Source: own (2025).

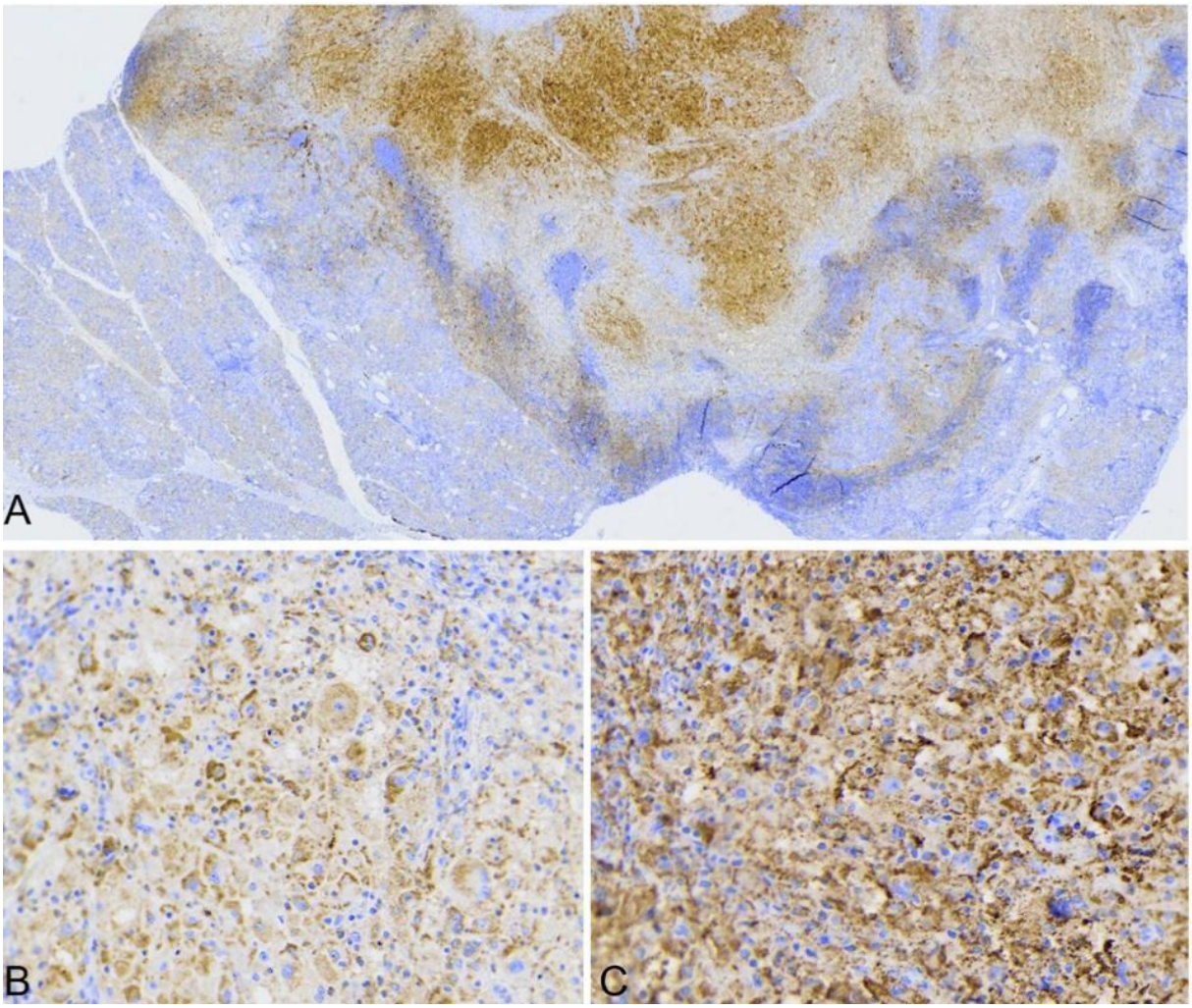

Figure 5: A : Positive nuclear and cytoplasmic immunostaining by S100 in histiocytes with evidence of emperipolesis of lymphocytes surrounded by a clear halo (arrow) (400x magnification). B: evaluation of the cell proliferation index at Ki67, showing nuclear labeling in about 3% of the cells (200x magnification). External control in the upper left corner. Source: own (2025).

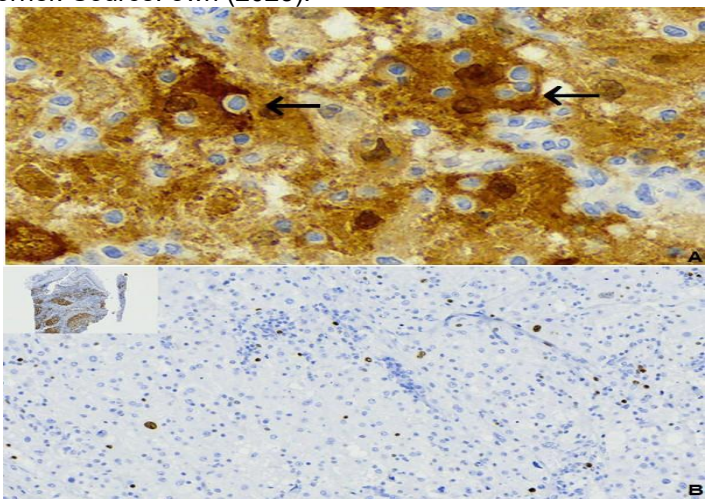

DIAGNOSIS AND FOLLOW-UP

Morphological and immunohistochemical findings confirmed the diagnosis of Rosai-Dorfman disease in the left submandibular gland, a rare condition of histiocytic proliferation characterized by emperipolesis and associated inflammatory infiltrate. The clinical and histopathological picture (Table 1) was consistent with the nodular and isolated presentation of the disease, without lymph node or systemic involvement. The patient had a good postoperative evolution and remained asymptomatic at a 9-month follow-up.

Table 1 - Summary of the main findings of the reported case.

	Descrição
Dados clínicos	Mulher, 41 anos, hígida, massa submandibular indolor, sem sintomas sistêmicos.
Exame físico	Massa firme, móvel, sem linfadenopatia regional.
Radiologia (USG)	Imagem nodular hipoecoica e heterogênea, de aspecto inespecífico.
Exame macroscópico	Nódulo lobulado, amarelado, 1,9 × 1,7 × 1,5 cm.
Histopatologia	Histiócitos com emperipolese, infiltrado linfoplasmocitário, sem necrose ou mitoses.
Imuno-histoquímica	S100+, CD68+, HAM56+. CD1a-, CK-, SOX10-, DOG1-. Ki-67: 3%.
Tratamento e evolução	Ressecção com margens livres, sem recidiva no curto prazo (9 meses).

Source: own (2025).

DISCUSSION

CLINICAL CHARACTERIZATION AND PATTERNS OF INVOLVEMENT

Rosai-Dorfman's disease (DRD), characterized by histiocytic proliferation associated with emperipolesis, is a rare condition, especially in its extranodal manifestations, such as involvement of the salivary glands.[3,22] In this context, Chen et al. (2023) reported 9 cases of DKD involving the submandibular gland.[8] However, for the present analysis, one of these cases added to the study by Chen et al. and described by Hasegawa et al. (2017) was excluded from the calculation, as their histopathological evaluation indicated that the submandibular gland presented only findings compatible with IgG4-related disease, with no evidence of DKD.[23]

In the cases previously documented in the submandibular topography, summarized in Chart 3 together with the present case, the clinical presentation was frequently associated with the effect of a slow-growing, painless mass accompanied by cervical lymphadenopathy. Some isolated cases presented nasal symptoms (nasal congestion, rhinitis, epistaxis), xerostomia, and bone compression.[7,8,24-28] In addition, about one-third of

patients with DKKD in the head and neck have type B symptoms (fever, weight loss, night sweats).[21]

Despite the self-perception of painless and slow growth reported by the patient in this case, there was no additional clinical manifestation, which reinforces the localized and indolent nature of the disease.

The literature describes that between 30 and 40% of DKD cases have extranodal involvement[22] and that this rate can reach 43%, according to Panikar et al. (2005). However, no study specifically mentions the occurrence of exclusive extranodal involvement, without concomitant lymph node involvement. Among the eight cases analyzed by Chen et al. (2023), two had exclusive extranodal involvement, a pattern also observed in the present report, in which the disease was restricted to the submandibular gland, with no evidence of associated lymphadenopathy. This observation suggests that, although extranodal involvement is recognized as frequent, its isolated manifestation may be underdiagnosed or underestimated.

ANALYSIS OF PREVIOUS REPORTS AND PROGNOSTIC IMPLICATIONS

The comparison between the present case and the one described by Panikar et al. (2005) reveals significant similarities, especially in relation to the age group and gender of the patients, both women around the fourth decade of life. However, while Panikar's patient had simultaneous involvement of the submandibular gland and ipsilateral cervical lymph nodes, associated with systemic symptoms such as fever, epistaxis and nasal congestion, the patient in the present report had manifestation restricted to the submandibular gland, without evident lymph node enlargement or systemic symptoms. In addition, in the case of Panikar, the management was conservative, after the diagnosis by fine-needle aspiration, with spontaneous regression of the lesion within one month, while in the present report, surgical resection was necessary for diagnostic elucidation. These findings suggest that the concomitant involvement of the submandibular gland and cervical lymph nodes may be associated with a more intense inflammatory response and, consequently, with a broader symptomatic spectrum, whereas forms restricted to the gland, as in the present case, tend to evolve in a more silent and localized manner.

Quadro 3 - Quadro clínico dos casos relatos em glândula submandibular.

Autor	Idade /Sexo	Exame físico	Achados da glândula SM	Achados laboratoriais	Achados de imagem	Tratamento	Prognóstico
Buchino et al., 1982	13/M	Linfadenopatia generalizada, massa na glândula SM, envolvimento multiorgânico	-	HGG, elevação de α1, β1 e γ-globulinas	-	EC da glândula submandibular e linfonodos adjacentes; RT para lesão espinhal	Óbito - progressão - envolvimento multissistêmico
Wenig et al., 1993	70/M	Massa indolor na glândula SM	-	-	-	Excisão cirúrgica	Sem recorrência após o tratamento
Benghorbel et al., 2005	53/F	Aumento das glândulas SM, LC, nódulo tireoidiano e massa renal	Tumefação das glândulas	VHS aumentada, fibrinogênio elevado e HGG	USG: adenomegalia cervical e BMN.	Corticoterapia	Remissão das lesões pulmonares, renais após 5 meses
Panikar et al., 2005	45/F	Aumento da glândula SM, LC, congestão nasal, epistaxe, febre e perda de peso	Glândula aumentada (2,5 cm)	Alta da taxa de sedimentação eritrocitária e HGG	-	Acompanhamento sem intervenção cirúrgica	Redução do tamanho da lesão após um mês
Guven et al., 2007 - Paciente 1	10/M	Massas parotídea/SM; xerostomia; cáries; gengivite; LC; lesões intracranianas; perda auditiva	Aumentada de tamanho	-	CG: captação diminuída nas glândulas submandibulares	Excisão de linfonodo e glândula SM; esteroides e metotrexato; uso de aparelho auditivo	Sem recorrência após tratamento
Guven et al., 2007 - Paciente 2	9/M	Massas em glândulas SM, LC, audição reduzida, cáries dentárias	Aumentadas de tamanho	-	CG: captação diminuída nas glândulas submandibulares	Tratamento específico não relatado	Sem sintomas após 6 anos
Kaltman et al., 2011	11/M	Massa cervical unilateral associada à glândula SM	Aderida a uma linfonodomegalia	-	TC: múltiplas massas cervicais	Excisão cirúrgica	Sem recorrência relatada
Chen et al., 2023	51/M	Massa na glândula SM direita, sem dor, febre, perda de peso e linfonodomegalias	Nódulo de 2 cm com limites claros	-	RM: nódulo de sinal longo em T1 e T2	Excisão cirúrgica	Sem recorrência após 24 meses
Caso atual	41/F	Massa SM esquerda de crescimento lento e indolor	Nódulo lobulado de (1,9 cm)	-	USG: imagem nodular hipoecoica e heterogênea, inespecífica	Excisão cirúrgica com margens livres	Sem sintomas após 9 meses

Legendas: SM: submandibular; HGG: hipergamaglobulinemia; EC: excisão cirúrgica; RT: radioterapia; LC: linfoadenopatia cervical; a: anos; M: masculino; F: feminino; VHS: velocidade de hemossedimentação; CG: cintilografia; TC: tomografia computadorizada; RM: ressonância magnética; USG ultrassonografia; BMN: bócio multinodular; CO: cintilografia óssea. Fonte: própria (2025).

Although some authors mention the possibility that DKKD in salivary glands is due to the involvement of intrasalivary lymph nodes,7 in the present case, it is in intimacy with the salivary gland parenchyma and no enlarged lymph node has been identified clinically or by imaging. These findings strongly suggest that it is a primary extranodal form, with exclusive involvement of the submandibular gland.

The analysis of the eight cases mentioned by Chen et al. (2023), demonstrates a significant variation in the clinical presentation and evolution of DKD in the submandibular gland. The age of the patients varied widely, from 9 to 74 years, with a predominance of males, corresponding to 75% of the cases. Notably, the four cases described in patients in the first and second decade of life occurred exclusively in male individuals. Although the disease has an indolent course in most cases, it is observed that when there is systemic involvement of the disease associated with lymph node enlargement, the cases have unfavorable outcomes or marked symptoms. In the cases analyzed, 25% (2/8) of the patients had systemic involvement, and, among them, 50% (1/2) evolved to an unfavorable outcome with death. As an example, the cases described by Buchino et al. (1982) and Benghorbel et al. (2005) demonstrated that patients with multiple locations of the disease, including the nodals, submandibular gland, and other extranodal sites, required more complex therapeutic approaches, such as corticosteroid therapy and radiotherapy. However, only the case reported by Buchino et al. (1982) evolved with an ominous outcome. This reinforces that the presence of extensive lymphadenopathy or multisystem involvement may be a negative prognostic factor and contribute to a more aggressive course of the disease. Thus, the absence of systemic symptoms and the confinement of the

disease to the submandibular gland may indicate a better prognosis and less need for extensive therapeutic intervention.

HISTOPATHOLOGICAL FINDINGS AND FINAL CONSIDERATIONS

From the histopathological point of view, the present case confirms the classic findings of DKD, such as histiocytic infiltrate with emperipolesis associated with lymphoplasmacytic infiltrate.[1-3,21] In addition, immunohistochemical findings were fundamental for diagnostic confirmation, with positivity for S100, CD68 and HAM56, corroborating the essential diagnostic criteria described for the disease.[3,21] Negativity for CD1a was decisive for ruling out LCH, a condition that can also be positive for S100 and emperipolesis1, but is distinguished by the presence of Birbeck granules and positivity for langerin and CD1a.[14]

A highlight in this report is the uniqueness of the presentation and handling. While some reports describe complex cases that require broader interventions, including adjuvant therapy,[5,19,20] lesion control in this case was achieved through surgical resection, with favorable postoperative evolution and absence of recurrence. This outcome reinforces the self-limiting nature of DKD in localized presentations and the importance of early and accurate diagnosis to avoid overtreatment.

Finally, the rarity of DKD in the submandibular gland highlights the relevance of this report. Despite advances in the understanding of extranodal manifestations of the disease, cases involving exclusively the submandibular gland remain underdocumented. This case broadens the clinicopathologic spectrum of DKD and emphasizes the importance of including this entity in the differential diagnosis of rare glandular masses, contributing to a better diagnostic accuracy and clinical management.

CONCLUSION

Rosai-Dorfman's disease (DKD) is a rare condition of uncertain etiology that may present nodal and extranodal manifestations, with salivary gland involvement being an uncommon finding. The case presented here highlights the importance of DKD as a differential diagnosis in salivary lesions, especially when there is a histiocytic infiltrate associated with emperipolesis. Detailed histopathological characterization, together with immunohistochemical study, is essential for the definitive diagnosis and exclusion of neoplasms and other histiocytoses. Although DRD has a generally indolent and self-limiting clinical course, its recognition is essential to avoid unnecessary therapeutic approaches. The present report contributes to the expansion of knowledge about this entity in an atypical

location, reinforcing the need for greater attention to its morphological and clinical presentation.

REFERENCES

1. MEDEIROS, L. Jeffrey. Doença de Rosai-Dorfman. In: MEDEIROS, L. Jeffrey. Patologia do Linfonodo de Ioachim. 5. ed. Lippincott Williams & Wilkins: Wolters Kluwer, 2022.

2. ROSAI, J.; DORFMAN, R. F. Sinus histiocytosis with massive lymphadenopathy: a pseudolymphomatous benign disorder. Cancer, v. 30, p. 1174-88, 1972.

3. NATKUNAM, Y.; ROSSI, S.; DEMICCO, E. G. et al. Rosai-Dorfman disease. In: WHO Classification of Tumours Editorial Board. Haematolymphoid tumours [Internet]. Lyon (France): International Agency for Research on Cancer; 2024. (WHO classification of tumours series, 5th ed.; vol. 11). Available from: https://tumourclassification.iarc.who.int/chapters/63.

4. GARCES, S.; MEDEIROS, L. J.; PATEL, K. P. et al. Mutually exclusive recurrent KRAS and MAP2K1 mutations in Rosai-Dorfman disease. Mod Pathol. 2017 Oct;30(10):1367-1377.

5. ABLA, O.; JACOBSEN, E.; PICARSIC, J. et al. Consensus recommendations for the diagnosis and clinical management of Rosai-Dorfman-Destombes disease. Blood, v. 131, n. 26, p. 2877-2890, 2018.

6. SODHI, K. S.; SURI, S.; NIJHAWAN, R. et al. Rosai-Dorfman disease: unusual cause of diffuse and massive retroperitoneal lymphadenopathy. Br J Radiol. 2005;78(933):845-847.

7. PANIKAR, N.; AGARWAL, S. Salivary gland manifestations of sinus histiocytosis with massive lymphadenopathy: fine-needle aspiration cytology findings. A case report. Diagn Cytopathol. 2005 Sep;33(3):187-90.

8. CHEN, P.; LI, J.; GAO, B. et al. Rosai-Dorfman disease of the submandibular gland. Oral and Maxillofacial Surgery Cases, v. 9, n. 2, 2023, 100308. ISSN 2214-5419.

9. RIBEIRO, B. N.; MARCHIORI, E. Rosai-Dorfman disease affecting the nasal cavities and paranasal sinuses. Radiol Bras. 2016 Jul-Aug;49(4):275-276.

10. WERNECK RODRIGUES, D. O.; WOLP DINIZ, R.; DENTZ, L. C. et al. Case Study: Rosai-Dorfman Disease and Its Multifaceted Aspects. J Blood Med. 2024 Mar 11;15:123-128.

11. LIU, L.; PERRY, A. M.; CAO, W. et al. Relationship between Rosai-Dorfman disease and IgG4-related disease: study of 32 cases. Am J Clin Pathol. 2013 Sep;140(3):395-402.

12. MAHZONI, P.; ZAVAREH, M. H.; BAGHERI, M. et al. Intracranial Rosai-Dorfman disease. J Res Med Sci. 2012;17(3):304-307.

13. RECH, K. L.; HE, R. Challenges in the Histopathologic Diagnosis of Histiocytic Neoplasms. J Natl Compr Canc Netw. 2021 Nov;19(11):1305-1311.

14. EMILE, J. F.; ABLA, O.; FRAITAG, S. et al. Revised classification of histiocytoses and neoplasms of the macrophage-dendritic cell lineages. Blood, v. 127, p. 2672–2681, 2016.

15. O'MALLEY, D. P.; DUONG, A.; BARRY, T. S. et al. Co-occurrence of Langerhans cell histiocytosis and Rosai-Dorfman disease: possible relationship of two histiocytic disorders in rare cases. Mod Pathol. 2010 Dec;23(12):1616-23.

16. KUO, T. T. Kikuchi's disease (histiocytic necrotizing lymphadenitis). A clinicopathologic study of 79 cases. Am J Surg Pathol. 1995 Jul;19(7):798-809.

17. RAMKUMAR, A. Kikuchi-Fujimoto disease as a differential diagnosis for cervical lymphadenopathy in India: a case report and review of literature. Indian J Otolaryngol Head Neck Surg. 2011 Jul;63(Suppl 1):110-2.

18. HENTER, J. I.; HORNE, A.; ARICÓ, M. et al. HLH-2004: Diagnostic and therapeutic guidelines for hemophagocytic lymphohistiocytosis. Pediatr Blood Cancer. 2007 Feb;48(2):124-31.

19. HSI, E. D.; SCHNITZER, B. Reactive Lymphadenopathies. In: JAFFE, E. S. Hematopathology. 2. ed. Philadelphia: Elsevier, 2016. Cap. 9, p. 164.

20. MANTILLA, J. G.; GOLDBERG-STEIN, S.; WANG, Y. Extranodal Rosai-Dorfman Disease: Clinicopathologic Series of 10 Patients With Radiologic Correlation and Review of the Literature. Am J Clin Pathol. 2016 Feb;145(2):211-21.

21. MAGABLEH, H. M.; JABER, H. D.; MAGABLEH, A. M. et al. Rosai-Dorfman Disease: Case Series and Literature Review. Cureus. 2023 Feb 19;15(2):e35193.

22. MEDEIROS, L. J.; DEMICCO, E. G.; WENIG, B. M. et al. Rosai-Dorfman disease. In: WHO Classification of Tumours Editorial Board. Head and neck tumours [Internet]. Lyon (France): International Agency for Research on Cancer; 2023 [cited 2025 Feb 1]. Available from: https://tumourclassification.iarc.who.int/chapters/52.

23. HASEGAWA, M.; SAKAI, F.; OKABAYASHI, A. et al. Rosai-Dorfman disease of the lung overlapping with IgG4-related disease. Intern Med 2017;56:937–41.

24. WENIG, B. M.; ABBONDANZO, S. L.; CHILDERS, E. L. et al. Extranodal sinus histiocytosis with massive lymphadenopathy (Rosai-Dorfman disease) of the head and neck. Human Pathology, v. 24, n. 5, p. 483-492, 1993.

25. KALTMAN, J. M.; BEST, S. P.; MCCLURE, S. A. Sinus histiocytosis with massive lymphadenopathy Rosai-Dorfman disease: a unique case presentation. Oral Surgery, Oral Medicine, Oral Pathology, Oral Radiology, and Endodontology, v. 112, n. 6, p. e124-e126, 2011.

26. GÜVEN, G.; ILGAN, S.; ALTUN, C. et al. Rosai–Dorfman disease of the parotid and submandibular glands: salivary gland scintigraphy and oral findings in two siblings. Dentomaxillofacial Radiology, v. 36, n. 7, p. 428–433, 2007.

27. BEN, G. I.; NAFFATI, H.; KHANFIR, M. et al. Disseminated form of Rosai-Dorfman disease. Rev Med Interne. 2005;26(5):415–9.

28. BUCHINO, J. J.; BYRD, R. P.; KMETZ, D. R. Disseminated sinus histiocytosis with massive lymphadenopathy: its pathologic aspects. Arch Pathol Lab Med. 1982;106:13–6.