LUMEN ET VIRTUS

Non-surgical treatment of a large periapical lesion: Case report

https://doi.org/10.56238/levv15n39-096

Rosana Maria Coelho Travassos[1], Cecília Alves Leopoldino[2], Gustavo Moreira de Almeida[3], Renata Wiertz Cordeiro[4], Luca Pasquini[5], Leonardo dos Santos Barroso[6], Adriana Marques Nunes[7], Eliana Santos Lyra da Paz[8], Francisco Braga da Paz Júnior[9], Carlos Fernando Rodrigues Guaraná[10].

ABSTRACT

The success of root canal treatment is based on thorough cleaning, shaping, and filling of the root canal system. A non-surgical endodontic treatment was planned because it is the most conservative approach, with continuous monitoring of the lesion at various follow-up periods. The treatment included chemical-mechanical debridement using the crown-apex technique without pressure, followed by filling of the canal with calcium hydroxide for 30 days, which was renewed monthly for a period of four months. Filling was performed using the active lateral condensation technique. Clinical and radiographic follow-up after one year showed total cure of the periapical lesion. This case report shows that the non-surgical conservative approach leads to complete healing of extensive periapical lesions.

Keywords: Non-surgical treatment, Periapical lesion, Endodontics, Dentistry.

[1] University of Pernambuco, Brazil
Email: rosana.travassos@upe.br
ORCID: https://orcid.org/0000-0003-4148-1288
[2] Faculty of Research and Teaching Institute
E-mail: ce.leopoldino@gmail.com
ORCID: https://orcid.org/0009-0000-5632-6980
[3] Research and Teaching Institute College
Email: drgustavoalmeida01@gmail.com
ORCID: https://orcid.org/0000-0002-1404-099X
[4] São Leopoldo Mandic College
E-mail: renata.wccordeiro@gmail.com
ORCID: https://orcid.org/0009-0007-7664-4207
[5] São Leopoldo Mandic College
E-mail: endodontialuca@gmail.com
ORCID: https://orcid.org/0009-0005-6009-6248
[6] University Center of Volta Redonda-RJ (UNIFOA)
Email: leosbarroso@gmail.com
ORCID: https://orcid.org/0000-0002-1273-5800
[7] University Center of Volta Redonda-RJ
Email: adrianaju@icloud.com
ORCID: https://orcid.org/0000-0002-6708-1197
[8] University of Pernambuco,Brazil
E-mail: eliana.lyra@upe.br
ORCID: https: orcid.org/0000-0003-4486-142X
[9] Federal Institute of Pernambuco, Brazil
Email: franciscobraga@recife.ifpe.edu.br
ORCID: https://orcid.org/0000-0003-1810-4011
[10] Federal Rural University of Pernambuco, Brazil
Email: carlos.guarana@ufrpe.br
ORDICID: https://ORCID.org/0000-0003-1312-3312

INTRODUCTION

Apical periodontitis is a sequelae of endodontic infection It is seen as a dynamic encounter between microbial factors and host defenses at the interface between the infected root pulp and the periodontal ligament that results in local inflammation, resorption of hard tissues, destruction of other periapical tissues. Treatment consists of eliminating infectious agents by endodontic and endodontic treatment. Even with correct cleaning and filling of the canals, it is possible that periapical periodontitis persists in the form of an asymptomatic radiographic transparency, giving rise to post-endodontic periapical lesion. (Hasic Brankovic et al. 2011).

Pulp infection can occur as a result of many factors, such as cavities or trauma, that cause tissue necrosis. Periapical infection is an inflammatory process that occurs in the periradicular tissues of the teeth, as a result of a dynamic interaction between endodontic pathogens and the host's defense mechanism. This interaction can lead to bone resorption and damage to periradicular tissues. Despite the defensive and preventive nature of these lesions periradicular to microbial infection, they are not self-healing. (Qusai et al. 2018).

Treatment approaches to deal with large periapical lesions range from non-surgical endodontic therapy with or without endodontic surgery to tooth extraction. Microbial elimination or its minimization of the pulp system using efficient chemical-mechanical preparation can lead to successful treatment. (Tartuk, Bulut, 2020). Conservative endodontic treatment procedures without surgery should be the first line of treatment for all inflammatory lesions of endodontic origin. Studies have reported 94.4% of total or partial resolution of endodontic lesions with simple nonsurgical treatment under adequate infection control. In case of unsuccessful non-surgical treatment, surgery is recommended.

This article presents a report of two patients undergoing non-surgical endodontic treatment of an extensive periapical lesion, using calcium hydroxide as an intracanal medication, which resulted in favorable clinical and radiographic results.

CASE REPORT

A 19-year-old male patient reported to the Endodontics Clinic with the main complaint of swelling in the region of the lower anterior teeth. The patient had a history of trauma to his teeth when he was 11 years old. Intraoral examination revealed a fistula and periodontal probing revealed intact normal gingiva. Intraoral periapical radiography revealed a large diffuse radiolucent lesion at the apex of teeth 31 and 41 (Figure 1). The teeth did not respond to the cold sensitivity tests; The adjacent and contralateral teeth responded within normal limits. Therefore, taking into account his dental history, a presumptive diagnosis of pulp necrosis of traumatic origin with extensive

inflammatory apical periodontitis was established. It was decided to perform root canal treatment of the aforementioned teeth.

Figure 1 - Diffuse radiolucent lesion at the apex of teeth 31 and 41



After anesthesia was performed and absolute isolation with a rubber dam, the coronary teeth were opened, and a yellowish suppurative fluid was drained via a canal. Initially, root canal space negotiation was done using a number 10 K-Flexofile file, and abundant irrigation was done using 2.5% Sodium Hypochlorite solution. The working length was determined, followed by gentle irrigation with sodium hypochlorite, the preparation of the canal of both teeth was performed by the crown-apex technique without pressure and at each instrument, irrigation with 2.5% sodium hypochlorite was performed. The root canal was then prepared up to the K-File 45 file. The foraminal patency was made a few millimeters beyond the apical foramen. For removal of the Smear Layer, irrigation with 5 mL of 17% EDTA and followed by sodium hypochlorite using manual dynamic stirring with master apical taper 1 mm short of working length with an up-and-down motion using an amplitude of 2 mm at a frequency of 100 strokes approximately 1 min. Subsequently, the root canal was filled with calcium hydroxide paste (Ultracal) (Figure 2).

Figure 2 - Filling of the root canal with calcium hydroxide paste (Ultracal).

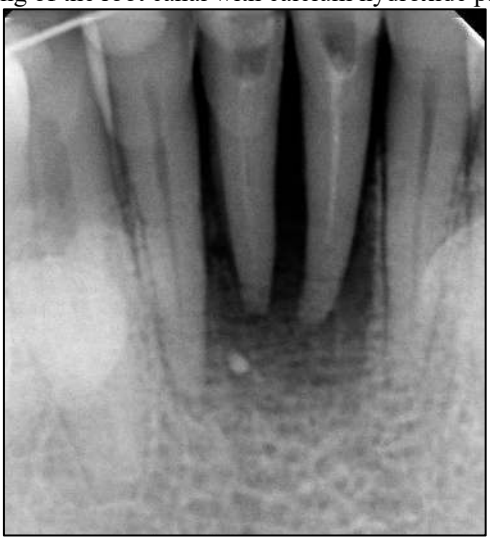

The calcium hydroxide paste (Ultracal) was renewed monthly for a period of four months, until the regression of periapical bone radiotransparency was observed, which was confirmed on periapical X-ray (Figure 3). A small extravasation of Ultracal is observed on this radiograph.

Figure 3 - Regression of periapical bone radiotransparency



Once the regression of the lesion was confirmed, it was decided to obturate the root canal system using the active lateral condensation technique (Figure 4).

Figure 4- Root canal system filling



The clinical and radiographic preservation consultation was performed one year after the root canal system was filled (Figure 5). This radiograph shows complete periapical bone neoformotion and the presence of ultralime beyond the apex of the tooth 41.

Figure 5 - Complete periapical bone neoformotion

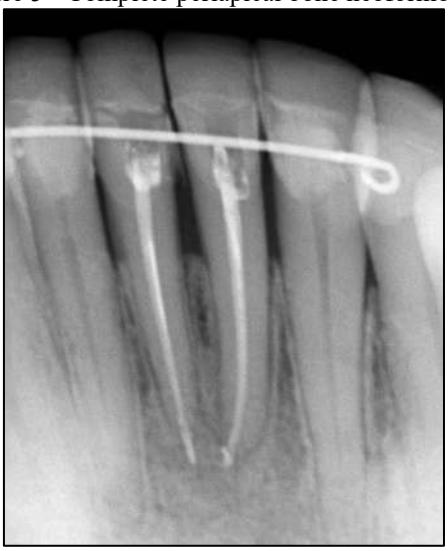

DISCUSSION

The progression of endodontically induced periapical lesions is clearly associated with the presence of microorganisms in the root canal system. There are surgical and non-surgical methods to treat these cases. Non-surgical root canal therapy is the treatment of choice in the management of teeth with large periapical lesions**.** When this treatment fails to resolve periradicular pathology, additional options should be considered, such as nonsurgical retreatment or periapical surgery. (Hasic Brankovic et al. 2011).

The success of non-surgical endodontic treatment is based on proper cleaning, shaping, and filling of the root canal. A thorough instrumentation with abundant irrigation is the cornerstone of a

successful root canal treatment. Although instrumentation and irrigation reduce bacterial count, an agent with bactericidal action is still needed to ensure optimal disinfection. Researchers have suggested extending the root canal instruments beyond the apical foramen for drainage and pressure relief. Sodium hypochlorite irrigation and proper biomechanical instrumentation are recommended for successful root canal treatment, followed by intracanal medication. (Shaiban et al. 2023). Calcium hydroxide is the most commonly used drug for root canal asepsis due to its high alkalinity and antibacterial activity. In this case, calcium hydroxide was used, and as the paste is progressively reabsorbed by the periapical fluids, regular renewal of the medication was necessary to reduce the intensity of the periapical inflammatory process.

Nonsurgical treatment of periapical lesions is preferable over surgical methods and should be considered. Possible damage to adjacent vital teeth, damage to anatomical structures in the vicinity of the injury, and pain and discomfort associated with surgical procedures can be eliminated by non-surgical methods. The patient's acceptance and apprehension regarding the surgical procedure, age, and medical conditions, which limit surgical procedures, are also factors that favor the non-surgical approach. Surgical procedures should be considered only when conventional root canal methods fail. (Nadakkavil et al. 2023). Elimination of bacterial invasion of the root canal is key to the successful treatment of periapical lesions. In the case of infection, non-surgical root canal treatment is the preferred option. In the present case, the same treatment was also chosen, using the appropriate chemical-mechanical method and intracanal medication that was renewed monthly for a period of four months in order to achieve a satisfactory result.

CONCLUSION

Root canal treatment performed with the highest standards of care with attention to asepsis, proper cleaning and shaping, irrigation, sanitation of the root canal system associated with calcium hydroxide-based medication can lead to total regression of extensive periapical lesions.

REFERENCES

Hasic Brankovic, L..et al. Endodontic treatment as non-surgical alternative in managing multiple periapical lesions . Health Sci Inst. 2011;29(4):250-3

Nadakkavil, Salahudheen; Nair, K. Radhakrishnan; Praveena, G.; Surya, KR. Non-surgical Management of a Large Periapical Lesion: A Case Report. Kerala Dental Journal, 2023 46(1):p 33-36.

Qusai, Al et al Nonsurgical Clinical Management of Periapical Lesions Using Calcium Hydroxide-Iodoform-Silicon-Oil Paste. Bio Med Research International ,12 2018

Shaiban, Amal Saeed. Healing of Large through-and-through Periapical Lesion 24 Managed by Non-Surgical Endodontic Treatment. Journal of Health Sciences 2023. 8(2):p 146-48.

Tartuk, G.A. Bulut, E.T. The effects of periapical lesion healing on bone density , International Dental Research. 2020. v. 10, n. 3.