LUMEN ET VIRTUS

Metachronous colorectal tumor of atypical location: Case report

https://doi.org/10.56238/levv15n39-067

Helen Brambila Jorge Pareja[1], Eduardo Alves Canedo[2], Elisangela Maria Nicolete Rampazzio[3], Maria Luiza Stefanuto[4], Isabella Silva Freitas[5], João Pedro Carvalho Cesar[6], Maria Eduarda Ferreira Ferraro[7] and Ana Julia Mendes Nascimento[8]

ABSTRACT

Colorectal cancer and esophageal cancer are distinct malignancies, but they share risk factors and mechanisms of carcinogenesis. Colorectal cancer, originating in the colon or rectum, is characterized by the uncontrolled growth of epithelial cells, and has a high global incidence, being the third most common and the second leading cause of cancer death. In 2022, Brazil recorded 13,921 deaths from this neoplasm, with a higher prevalence in people over 50 years of age, especially from the age of 70. Esophageal cancer, responsible for about 0.54 million deaths annually and the eighth most common cause of cancer, manifests as squamous cell carcinomas or adenocarcinomas and is strongly associated with family history, smoking, and alcohol consumption. Both types of cancer involve cellular dysfunction and resistance to apoptosis, and share risk factors such as male gender and family history, although there is no direct relationship between them.

Keywords: Colorectal Cancer, Metachronous Lesion, Surgery.

[1] Advisor and Dr.
General Surgeon and Ap. Digestive
University of Western São Paulo
[2] Doctor., General Surgery Resident
Hospital Regional de Presidente Prudente
[3] Medical Student
University of Western São Paulo
[4] Medical Student
University of Western São Paulo
[5] Medical Student
University of Western São Paulo
[6] Medical Student
University of Western São Paulo
[7] Medical Student
University of Western São Paulo
[8] Medical Student
University of Western São Paulo

INTRODUCTION

Colorectal cancer is a malignant neoplasm that originates in the colon or rectum, characterized by the uncontrolled growth of epithelial cells that form invasive tumors and can spread to other organs. Several pathophysiologies are associated with this event, such as abnormal cell proliferation, resistance to apoptosis, invasion of adjacent structures, and distant metastasis1.

Esophageal cancer, in turn, is a highly malignant condition, responsible for about 0.54 million deaths worldwide, being the eighth most frequent cause of cancer worldwide. It is strongly associated with a family history and may present histologically as squamous cell carcinomas (SCS), adenocarcinomas, sarcomas, small cell sarcomas, lymphomas, and melanomas (rare)[8]. Over the years, a decrease in the incidence of deaths related to this neoplasm was observed, in contrast to data on colorectal cancer. In 2022, in Brazil, there were a total of 8,571 deaths from esophageal neoplasia registered by the Unified Health System, with about 78.1% of men and 21.9% of women. These data also show that the 60-69 age group was the most affected in both sexes, with only 1 death recorded in people under 20 years of age (women)[3].

It is widely known that colorectal cancer is the third most common in terms of incidence worldwide, with adenomas being the most prevalent subtype and responsible for the second leading cause of cancer death. Annually, 1.9 million new cases are registered globally2,4. In Brazil, in 2022, 13,921 deaths due to colon-related cancer of primary origin were recorded, with 51% of cases occurring in women and the highest incidence observed in the age group of 50 years and over, specifically the 70-year-old group3. It is observed that, in the last decade, this type of neoplasm has increasingly affected younger populations, which further emphasizes its importance as a public health issue6.

Squamous cell carcinoma is the most common subtype of esophageal cancer, accounting for about 90% of cases. Adenocarcinoma is the most predominant subtype in North America and Europe, standing out in men and in the white race, around 50 years of age, in contrast to the literature that states that risk factors include black race and 60 years of age. This discrepancy can be attributed to sociocultural habits in a given geographic region that fall on modifiable risk factors, such as smoking and alcoholism. Esophageal neoplasia usually begins asymptomatically, later progresses to progressive dysphagia, dyspepsia, odynophagia, weight loss, and others. Thus, in view of these symptoms, upper digestive endoscopy is indicated to rule out cancerous formation in patients over 45 years of age13.

Several studies associate risk factors with colon cancer, such as type II Diabetes Mellitus, use of acetylsalicylic acid, smoking, prolonged alcohol consumption, and use of non-steroidal anti-inflammatory drugs. However, there are few studies that address the specific risk factors for the appearance of metachronic tumors. Age is considered a relevant factor, although inconclusively. It is

known, however, that the presence of synchronous lesions potentially increases the risk of metachronous lesions. Regarding the appearance of adenomas, factors such as male gender, age, and obesity are considered important points2,6. Obesity is strongly associated with increased risk of colorectal cancer for several reasons. Excess body fat can cause chronic low-grade inflammation, which can lead to cancer-prone cellular changes. In addition, obesity alters hormone levels, such as estrogen and insulin, involved in the development of cancer; Estrogen, for example, can influence the proliferation of intestinal epithelial cells. Obesity is also often associated with unhealthy eating habits and lower physical activity, both of which contribute to the risk of colorectal cancer. For patients already diagnosed with cancer, obesity can worsen prognosis and survival, increasing the mortality rate related to the disease13,14.

Colorectal adenomas and esophageal adenocarcinomas are distinct types of tumors, with different origins and histological characteristics, and there is no direct relationship between them described in the literature. However, some risk factors and genetic characteristics can create indirect connections between these two types of neoplasms. Factors such as male gender, smoking, and excessive alcohol consumption are known to increase the risk for both colorectal adenomas and esophageal adenocarcinomas. In addition, genetic predisposition plays a significant role, with a family history of colorectal or esophageal cancer often associated with an increased risk for both types of cancer. Both tumors share carcinogenesis mechanisms related to cellular dysfunction, such as dysregulated proliferation and resistance to apoptosis. Studies suggest that chronic inflammation, common in both types of cancer, may also contribute to the progression of neoplasms. Therefore, although there is no direct relationship between colorectal adenomas and esophageal adenocarcinomas, the overlap in risk factors and biological mechanisms offers a perspective on how these cancers may be indirectly connected13,14,15.

Generally, the liver is the first organ to metastasize from colorectal cancer. However, a tumor is classified as metachronous when it is a new primary cancer diagnosed within six months of the diagnosis of the first one. In the context of colorectal cancer, it is necessary to consider factors such as the size of the second tumor, whether it is of the villous or tubovillous type, the presence of dysplasia, among others2,4,5,6.

In terms of therapy, surgery is indicated for esophageal cancers for those whose histology reveals early-stage squamous cell carcinoma or adenocarcinomas, with chemoradiotherapy for the standard approach in locally advanced neoplasms. Some studies show that there are no significant implications for the quality of life of surgery and chemotherapy, but the mortality rate for locally advanced squamous cell carcinomas reaches 50% and the rates of local or distant metastases remain high. Immunotherapy may be a good alternative for these neoplasms in question, or even an advantageous adjuvant action for those of the resectable type10.

For colorectal tumors, approximately one-fifth of nonmetastatic patients will develop metachronous metastases, with the most common sites in the gastrointestinal tract itself, such as the sigmoid colon, ascending colon, transverse colon, and descending colon, or distant metastases to the liver, lung, peritoneum, and regional lymph nodes. Surveillance colonoscopy is essential for the subsequent follow-up of treated patients, while surgeries (resection of the affected intestinal segment) and radiotherapy represent the therapeutic options of choice5,6,7.

Surgical resection via esophagectomy is the primary choice for localized esophageal neoplasms, stage IIA and IIB, with a risk of postoperative complications of these surgeries of 30% to 50%, with in-hospital mortality of about 5%. Advanced regional disease in stage III, with neoadjuvant chemotherapy being 5% superior to surgery alone13. Esophageal adenocarcinomas are usually very advanced at the time of diagnosis, presenting distant metastases, with a survival rate of only 5%. Non-resectable (IV) stagings can benefit from chemoradiotherapy, esophageal stents, surgical placement of jejunostomy or gastrostomy tubes and esophageal bypass surgery10,13.

The literature on colorectal cancer often addresses the metastatic sites and hematogenous spread of the neoplasm. Some studies mention the sites of metachronic tumors, but there is still a gap in relation to atypical sites of these tumors. This study aims to report and contribute to filling this scientific gap.

METHODOLOGY

This is a case report study, whose information was collected through a review of medical records. In parallel, to support the ideas discussed in this article, a literature review was carried out in scientific databases such as PubMed. The production of this scientific article followed the regulations proposed by the National Research Council (CONEP).

CASE REPORT

A 73-year-old obese male patient with no other comorbidities, denying habits such as alcoholism and smoking, evolved with signs and symptoms of acute obstructive abdomen, who underwent laparotomy that showed a tumor mass in the sigmoid. Hartmann-style rectosigmoidectomy (amputation of the distal stump and colostomic anastomosis of the proximal stump) was performed without intercurrences. The anatomopathological examination confirmed infiltrative and ulcerated adenocarcinoma, moderately differentiated. The patient evolved stable, with good acceptance of the diet. Upper abdominal tomography was requested and performed 3 months after surgery for control. This showed a discrete irregular concentric wall thickening of the upper third of the esophageal, without invasions. A new CT scan was performed, this time of the neck, which showed an expansive lesion in the topography of the proximal esophagus, hypoattenuating,

with heterogeneous contrast uptake, measuring 30x20 cm, with a wide contact surface with the trachea and the right thyroid lobe with signs of paralysis of the right vocal cord.

The hypothesis of an advanced metachronous tumor of atypical location was raised, after anatomopathological examination confirmed a moderately differentiated infiltrating tubular adenocarcinoma. Chemotherapy treatment was chosen in an attempt to have a possibility of resection. In oncological follow-up, the patient progresses with dysphagia to solids and, later, liquids. According to the scale *Palliative Perfomance Scale*, totaling 30 points, it was decided to maintain supportive therapy and palliative care of the patient, as well as adjuvant therapy, observing the patient's age and clinical conditions. Metastases were observed locally and then at a distance. The patient was referred for an unsuccessful attempt to pass a nasogaric tube through upper gastrointestinal endoscopy, which showed vegetative and stenosing lesions of the proximal esophagus, preventing the progression of the gastroscope. Thus, a gastrostomy was scheduled for the patient's symptomatological resolution and permission for nutritional support that would condition a certain comfort in his terminal neoplasm.

DISCUSSION

The scientific literature widely recognizes that colorectal tumors are more prevalent in men, as well as malignant tumors of the esophagus5,8. However, according to the National Cancer Institute (INCA) and data released by the Unified Health System (DATASUS)[3], in 2022, mortality associated with esophageal cancer was predominantly higher among men, accounting for about 71% of cases. In contrast, in colorectal cancer, mortality was slightly higher among women, with approximately 51% of recorded deaths occurring in females. According to these same data, the death rate decreased in relation to esophageal cancer in the period from 2013 to 2022 and there was an increase in relation to colorectal cancer.

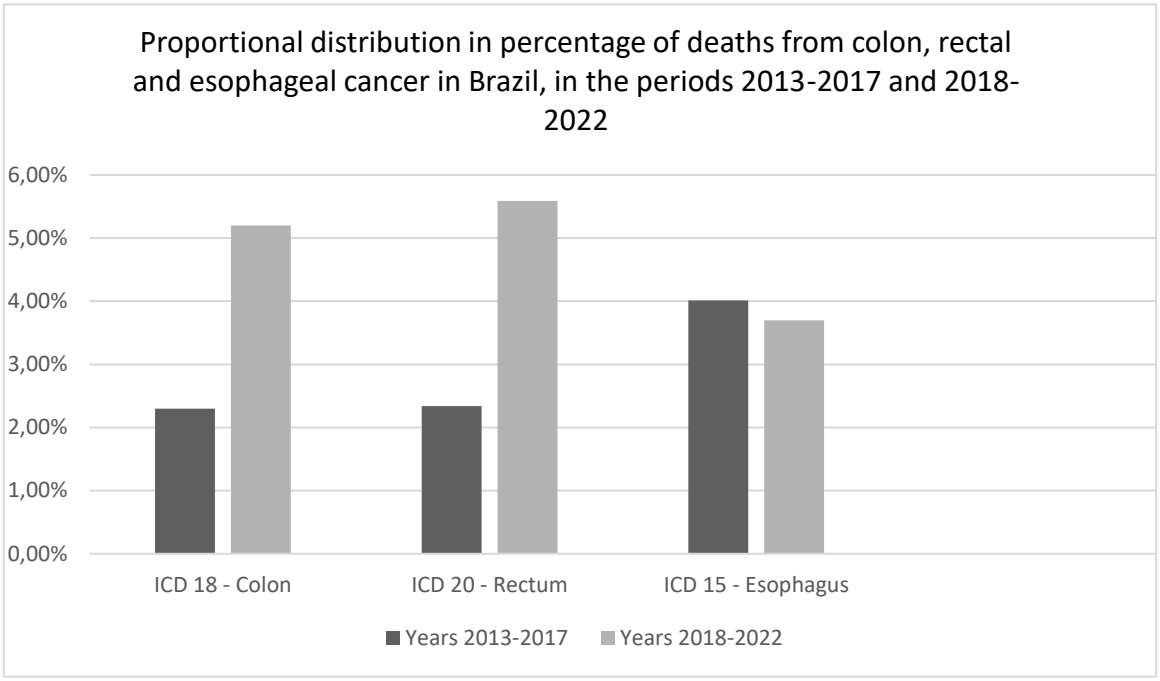

Source: MS/SVS/DASIS/CGIAE/Mortality Information System - SIMMP/Brazilian Institute of Geography and Statistics Foundation - IBGEMS/INCA/Conprev/Surveillance Division3

According to the same source of information3, it is observed that the highest incidence of deaths occurs in the 70-year age group, both in men and women. However, there was a significant increase in the number of deaths from colorectal cancer among the younger population, aged around 40 years. Correlating this information with the existing literature5, it is possible to conclude that the number of people affected and dying from this pathology is increasing, and the condition is affecting younger and younger individuals. Thus expressing these numbers, we observed that the patient in question is 73 years old, coinciding with this statistical collection. Although he did not die, the rapid and comorbid evolution with which the patient presented the metachronous tumor suggests a poor prognosis.

Regarding the histological type of cancer, it was observed that adenomas present an increased risk with advancing age. In addition, male gender and increased Body Mass Index (BMI) are specific risk factors for the appearance of these lesions. According to scientific studies, this patient has all three risk factors for adenoma-type colorectal cancer. Although no studies were found that correlated increasing age with increased risk of metachronous neoplasia, it was found that adenomas, both low and high risk, do not have a relevant impact on the appearance of these neoplasms. According to a study referenced in this study, it is not necessary to increase the frequency of colonoscopies for individuals with adenoma-type colorectal cancer6.

Obesity is strongly associated with an increased risk of colorectal cancer. This occurs for several reasons. First, excess fat in the body can cause chronic low-grade inflammation, a state that can lead to cancer-prone cellular changes. In addition, obesity alters the levels of hormones in the

body, such as estrogen and insulin, which have been implicated in the development of cancer, since estrogens supposedly develop a protective factor against the proliferation of intestinal epithelial cells. In addition to these biological mechanisms, obesity often results in less healthy eating habits and lower physical activity, both of which contribute to colorectal cancer risk. For those who have already been diagnosed with cancer, obesity can negatively impact prognosis and survival, increasing the mortality rate associated with the disease6,13,14. In this report, the absence of significant risk factors further increases the impact of obesity on the development and outcome of the disease, since it was the only factor presented by the patient, besides male gender.

Regarding the appearance of metachronous metastases, the most common sites are hepatic and pulmonary, suggesting a poor prognosis. Primary metachronous lesions usually occur in the gastrointestinal tract, but in the colon and rectum itself. No studies were found to suggest the esophagus as a possible site. In this case, the anatomopathological study was indispensable to identify the histological subtype and raise the hypothesis of metachronicity of atypical location5,6,7,11.

The prognosis of esophageal cancer itself is poor. The high malignancy of this pathology suggests rapid progress in order to significantly decline the patient's health. It has a high relationship with family history, which was not observed in this report. This cancer is the sixth leading cause of death from cancer, it should be considered that this ranking implies that esophageal cancer has fewer cases in numbers than colorectal8.

For the treatment of colorectal cancer, resection of the affected intestinal segment is the best option. The presence of the neoplasm itself is a solid indication for such a procedure, in addition to the presence of benign lesions and trauma. The morbidity and mortality of surgery is directly related to the eligibility criterion, whether it is elective or on an emergency basis. The surgeon's experience determines technical issues such as the use of staples or hand sewing in the intestinal anastomosis, for example. The "fast-track" protocol authorizes the introduction of oral diet on the first postoperative day with good acceptance, as was the case of the patient reported in this study7. In metastatic cases, adjuvant chemotherapy becomes necessary in the face of large blood dissemination of cancer cells9.

Subsequent colonoscopies are necessary to detect cases of tumor recurrence for colorectal cancers without much information regarding the impact on metachronous lesions specifically, as previously stated[6]. This patient underwent such follow-up, but as his lesion was present in an atypical site, there was no impact on early detection, since the diagnosis of esophageal cancer arose from abdominal computed tomography and this showed advanced tumor.

As for esophageal cancer, chemotherapy needs to be introduced. It is a multidisciplinary pathology, whose patient observes their potentially reduced quality of life. Immunotherapy presents a

good alternative for this and associated with chemotherapy, in the face of a resectable tumor, the results can be promising10. Non-advanced tumors in early stages are chosen for surgical resection, with gastrostomy being an indication in these cases. For the patient in this case, surgery was not possible, since the neoplasm was infiltrated in adjacent structures, advanced in the staging. In view of the need to maintain nutritional support on an outpatient basis, percutaneous endoscopic gastrostomy was successfully performed and with a good solid indication for this procedure12,14.

To support the decision to undergo gastrostomy, the *Palliative Performance Scale16* of the patient, whose limitation imposed by the esophageal neoplasm and his advanced situation, prevented the patient from remaining independent and returning to his usual functions, totaling 30 points on the scale. Thus, adjuvant care was chosen, without surgical intervention or other invasive methods that would compromise the palliative care to which he was submitted. Although the gastrostomy has a certain invasive character, it was necessary to maintain nutritional support at the end of this patient's life and ensure less suffering for the patient and greater ease for the family to perform the necessary care at home.

Colorectal adenomas and esophageal adenocarcinomas are different types of tumors, and there is no relationship described between them in the literature, as occurred in this case reported, but there are some connections and shared risk factors that may relate them indirectly, such as male gender, smoking, and alcohol consumption. In addition, both tumors share a strong genetic trait, with family history as a significant impact factor. Both are also related to the mechanism of carcinogenesis in relation to cellular dysfunction13,14,15.

CONFLICTS OF INTEREST

The authors state that there is no potential conflict of interest that could compromise the impartiality of the information presented in this scientific article.

REFERENCES

1. Ionescu VA, Gheorghe G, Bacalbasa N, Chiotoroiu AL, Diaconu C. Colorectal Cancer: From Risk Factors to Oncogenesis. Medicina (Kaunas). 2023;59(9):1646. Published 2023 Sep 12. doi:10.3390/medicina59091646

2. Zhang Y, Karahalios A, Aung YK, Win AK, Boussioutas A, Jenkins MA. Risk factors for metachronous colorectal cancer and advanced neoplasia following primary colorectal cancer: a systematic review and meta-analysis. BMC Gastroenterol. 2023;23(1):421. Published 2023 Nov 30. doi:10.1186/s12876-023-03053-2

3. "Taxas de Mortalidade por Câncer, brutas e Ajustadas por Idade pelas Populações Mundial e Brasileira, por 100.000 Habitantes em 2022." Atlas Online de Mortalidade, Departamento de Informática do Sistema Único de Saúde (DATASUS), [2024], https://mortalidade.inca.gov.br/MortalidadeWeb/pages/Modelo03/consultar.xhtml#panelResultado. Acesso em 16 mar 2024.

4. Hao M, Wang K, Ding Y, Li H, Liu Y, Ding L. Which patients are prone to suffer liver metastasis? A review of risk factors of metachronous liver metastasis of colorectal cancer. Eur J Med Res. 2022;27(1):130. Published 2022 Jul 25. doi:10.1186/s40001-022-00759-z

5. van Gestel YR, de Hingh IH, van Herk-Sukel MP, et al. Patterns of metachronous metastases after curative treatment of colorectal cancer. Cancer Epidemiol. 2014;38(4):448-454. doi:10.1016/j.canep.2014.04.004

6. Enwerem N, Cho MY, Demb J, et al. Systematic Review of Prevalence, Risk Factors, and Risk for Metachronous Advanced Neoplasia in Patients With Young-Onset Colorectal Adenoma. Clin Gastroenterol Hepatol. 2021;19(4):680-689.e12. doi:10.1016/j.cgh.2020.04.092

7. "Overview of Colon Resection." UpToDate, UpToDate, https://www.uptodate.com/contents/overview-of-colon-resection. Accessed 17 Aug. 2024.

8. Liu CQ, Ma YL, Qin Q, et al. Epidemiology of esophageal cancer in 2020 and projections to 2030 and 2040. Thorac Cancer. 2023;14(1):3-11. doi:10.1111/1759-7714.14745

9. Shin AE, Giancotti FG, Rustgi AK. Metastatic colorectal cancer: mechanisms and emerging therapeutics. Trends Pharmacol Sci. 2023;44(4):222-236. doi:10.1016/j.tips.2023.01.003

10. Ge F, Huo Z, Cai X, et al. Evaluation of Clinical and Safety Outcomes of Neoadjuvant Immunotherapy Combined With Chemotherapy for Patients With Resectable Esophageal Cancer: A Systematic Review and Meta-analysis. JAMA Netw Open. 2022;5(11):e2239778. Published 2022 Nov 1. doi:10.1001/jamanetworkopen.2022.39778

11. Nyström, Karin; Olsson, Louise. Uma revisão sistemática de estudos populacionais sobre metástases metacrônicas de câncer colorretal. World Journal of Surgery, 2024.

12. Fugazza A, Capogreco A, Cappello A, et al. Percutaneous endoscopic gastrostomy and jejunostomy: Indications and techniques. World J Gastrointest Endosc. 2022;14(5):250-266. doi:10.4253/wjge.v14.i5.250

13. Short, Matthew W., Kristina G. Burgers, and Vincent T. Fry. "Esophageal cancer." American family physician 95.1 (2017): 22-28.

14. Wang, Huaqing et al. “The comparison of risk factors for colorectal neoplasms at different anatomical sites.” International journal of colorectal disease vol. 38,1 26. 31 Jan. 2023, doi:10.1007/s00384-022-04296-3

15. Meyerhardt, Jeffrey A., and Edward L. Giovannucci. "Obesity and Cancer Risk: Evidence, Mechanisms, and Recommendations." American Journal of Clinical Nutrition, vol. 97, no. 6, 2013, pp. 1336-1343. American Society for Nutrition, doi:10.3945/ajcn.112.048492.

16. Anderson, Michael C., et al. "The Palliative Performance Scale (PPS): A New Tool for the Assessment of Patients with Advanced Cancer." Palliative Medicine, vol. 10, no. 4, 1996, pp. 245-253.