LUMEN ET VIRTUS
ISSN: 2177-2789

INCIDENTAL FINDING OF HEPATOCYTIC PROLIFERATION OF UNCERTAIN BIOLOGICAL BEHAVIOR

https://doi.org/10.56238/levv15n42-071

Submitted on: 26/10/2024 **Publication date:** 26/11/2024

Helen Brambila Jorge Pareja[1], Elisangela Maria Nicolete Rampazzio[2], Isadora Ortiz de Carvalho[3], Luiza Queiroz Pettinate[4], Armando Carromeu Dias Pioch[5], Pedro Linares de Oliveira Martins[6], Tís Bargas Vioto[7], Douglas José Fernandes[8], Ana Paula Fleury de Carvalho[9] and Guilherme Guardachoni de Padua Calixto[10]

ABSTRACT

Since 1995, research on liver tumors has been driven by groups such as the International Working Party (IWP) and the International Consensus Group for Hepatocellular Neoplasia (ICHN). These groups classified liver nodules into regenerative lesions, such as focal nodular hyperplasia, and dysplastic or neoplastic lesions, such as adenomas and hepatocellular carcinomas. Hepatocellular adenomas occur more in young women, often linked to the use of combined oral contraceptives, whereas hepatic hemangiomas and focal nodular hyperplasia usually remain benign but may require follow-up if they increase in size.

[1] Advisor and Dr.
Oncological surgeon of ap. Digestive
University of Western São Paulo
E-mail: Brambila_hj@hotmail.com
[2] Medical Student
University of Western São Paulo
E-mail: Lis.nicolete@gmail.com
[3] Medical Student
University of Western São Paulo
E-mail: isa.decarvalho@hotmail.com
[4] Medical
University of Western São Paulo
Email: luizapettinate@gmail.com
[5] Doctor
University of Western São Paulo
Email: armando.pioch@gmail.com
[6] Medical Student
University of Western São Paulo
E-mail: pedrinholinares@hotmail.com
[7] Medical Student
University of Western São Paulo
Email: thaisbvioto@hotmail.com
[8] Medical Student
University of Western São Paulo
E-mail: douglasjosefernandes@hotmail.com
[9] Medical Student
University of Western São Paulo
Email: anafc2@gmail.com
[10] Medical Student
University of Western São Paulo
LATTES: http://lattes.cnpq.br/9421089846200449

The diagnosis of liver tumors is made mainly by imaging tests, and biopsy is used to evaluate the histological type. Treatment ranges from conservative to surgical, depending on size, symptoms, and malignant potential. In asymptomatic incidental findings, management is usually conservative. However, large, symptomatic, or malignant tumors require surgical intervention, and may include resection or chemotherapy in advanced cases. Little is said in the literature about uncertain histopathological behaviors, a fact that this research seeks to elucidate and help the scientific community.

Keywords: Liver tumor. Surgery. Incidental finding.

INTRODUCTION

Since 1995, research groups have suggested some classifications regarding the study of liver tumors. The International Working Party (IWP) and the International Consensus Group for Hepatocellular Neoplasia (ICHN) are collaborations that aimed to classify the management of hepatocellular neoplasms, especially those related to carcinomas, and to develop guidelines that would help professionals treat their patients diagnosed with these pathologies. According to the IWP and ICHN, hepatocellular nodules are divided into regenerative lesions and dysplastic/neoplastic lesions. The first refers to focal nodular hyperplasia and the second to hepatocellular adenomas, dysplastic nodules and hepatocellular carcinomas.

The management of such tumors is uncertain regarding conservative and surgical treatment1. For the Brazilian College of Hepato-Biliary Pancreatic Surgery2, recent studies published in the Brazilian Journal of Digestive Surgery have highlighted the risks of surgically approaching the liver, correlating techniques and superimposing them on the advantages of such an approach.

Hepatic cell adenomas are more prevalent in females and are related to the use of combined oral contraceptives, especially estrogen, with a diagnosis rate of 1 per 100,000 inhabitants, predominantly in the age group under 40 years, with a 3% risk of malignant complications; Hepatic hemangioma, another benign lesion, is formed by blood cavities, with a tendency to remain stable over the years, with very low malignant potential, except when its size exceeds 10 cm, in which case it requires regular follow-up and even surgical intervention; Focal nodular hyperplasia is a very common benign involvement, also occurring in women of reproductive age, it is believed to arise from a hyperplastic response with disorganized growth of hepatocytes and bile ducts. Other benign situations involve Caroli's disease, adenomatosis, angiomyolipoma, inflammatory pseudotumors, and regenerative nodules1,3,4.

Of the malignant transformations worth noting, hepatic carcinomas are the most common, which arise from cirrhotic livers, whose arterialization process allows identification through computed tomography and/or magnetic resonance imaging1. Other malignant transformations may be associated with genetic dysfunction responsible for the emergence of familial syndromes or the metastasis of primary tumors from other locations.

The use of imaging tests for the diagnosis of other pathologies has made incidental findings of liver tumors more common, each with its own characteristics. In other words, it can be concluded that the main diagnostic method for both benign and malignant tumors is imaging tests, with biopsy and anatomopathological examination used to understand the

histological behavior of each one. In the United States, the incidence of incidental diagnoses of benign tumors exceeded the diagnoses of malignant transformations3. For these tumors, surgery may involve resection or enucleation, but conservative treatment is the standard management, in which case such therapies depend on the size of the tumor and whether the lesions are symptomatic4. Malignant transformation or the appearance of metastases is a clear solid indication for surgical outcome, whether or not it is associated with neoadjuvant chemotherapy2.

To better evaluate the issue of management of benign and malignant tumors, each tumor should be evaluated in terms of individual histological behavior. Another indication for resection has been a consumptive coagulopathy or Kasabach-Merritt syndrome. However, in practice, symptomatology has been the main triggering factor for surgical outcome4. It is not clear in the literature regarding the management of asymptomatic incidental findings, a fact that this study aims to help elucidate by reporting the case of a patient with histopathological findings of uncertain behavior.

METHODOLOGY

This is a case report study, whose information was collected through a review of medical records. In parallel, to support the ideas discussed in this article, a literature review was carried out in scientific databases such as PubMed. The production of this scientific article followed the regulations proposed by the National Research Council (CONEP).

CASE REPORT

A 59-year-old female patient was followed up on an outpatient basis due to irritable bowel syndrome and a family history of colorectal cancer. Pain in the left iliac fossa associated with nausea and hyporexia with worsening stress begins. In long-term use of mesacol®. He states that in the last 6 months he developed with worsening of intestinal constipation. On physical examination, the patient had a distended abdomen and increased bowel sounds.

She underwent abdominal ultrasound, which showed multiple gallbladder stones and bilateral kidney stones. Upper gastrointestinal endoscopy reported findings of sliding hernia measuring 2 cm, grade I esophagitis, mild gastritis, and subepithelial injury. Colonoscopy without alterations. The patient underwent elective laparoscopic cholecystectomy, which in turn was responsible for the incidental finding of hepatic mass (Figure 1) with removal of intraoperative material for biopsy. The patient received a diet one day after surgery and was discharged from the hospital.

Figure 1 – Tumor mass in the hepatic lobe visualized by videolaparoscopy.

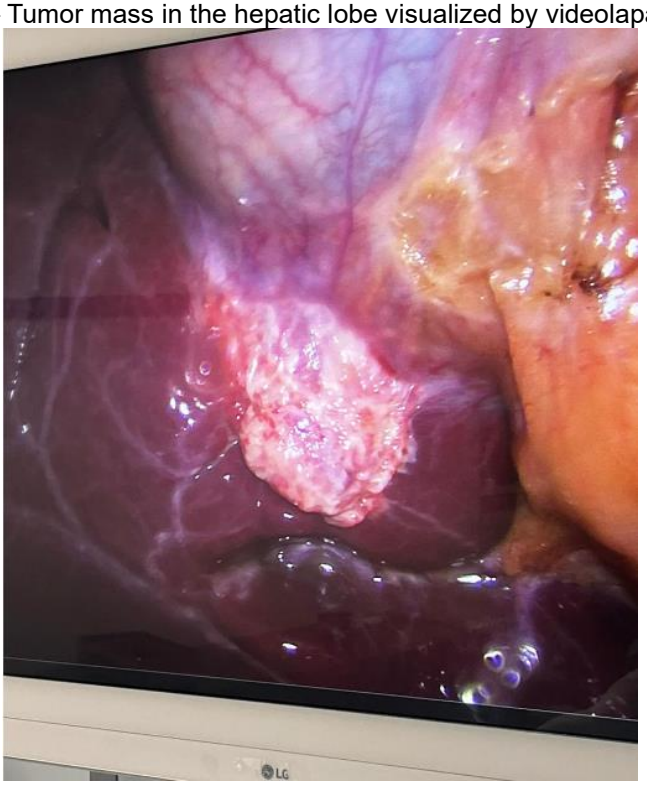

Source: the authors

The anatomopathological study received histological sections stained with hematoxylin-eosin, demonstrating a predominant sample of hyalinized hypocellular fibrous tissue that, in part, represents a thickened hepatic capsule. This fibrous tissue surrounds/encompasses some irregular portions of hepatic tissue composed of cellular sheets (without perceptible lobular architecture) made up of atypical hepatocytes with focally pleomorphous hyperchromatic nuclei and showing an increased nucleocytoplasmic ratio. The conclusion was hepatocytic proliferation of uncertain biological behavior. There were insufficient criteria for the diagnosis of hepatocellular carcinoma or other type of hepatocytic neoplasm. The team searches the literature for evidence of appropriate management for such histopathological behavior.

DISCUSSION

Hepatocellular tumors have typical imaging features. Currently, the most common diagnosis arises from focal nodular hyperplasia (UFH), predominantly in women. Despite being a benign tumor, all concern ends about the possible malignant transformation that may come from these findings. Both UFH and adenomas (the second most common) may present with some diagnostic challenges and atypical characteristics, representing some difficulty in radiological examinations1,3. However, what to do when tumors are found incidentally without giving a trace in imaging tests?

Benign hyperplasia is predominant in women and liver cancer diagnoses were more numerous in men in Brazil. In 2023, according to the National Cancer Institute (INCA), a total of 6,390 diagnoses of primary site in the liver were made in this genus alone8,10. The concern about this neoplasm is genuine, as hepatocellular carcinoma represents the fifth leading cause of cancer death in the world7.

In view of the concern of malignant transformation, it is worth noting that the most common liver neoplasm (hepatocellular carcinoma - HCC) arises predominantly from a cirrhotic liver7. Here, we report a patient with no risk factors for such involvement and with previously healthy liver and hepatic tracts. Hepatocellular carcinoma is associated with specific risk factors for this, especially regarding the epidemiology of chronic alcoholism and contagion by the hepatitis C virus. This fact is the main justification for the predominance of the condition in men diagnosed with this malignant tumor, in addition to the association with genetic factors9.

The treatment of benign liver tumors is conservative and this fact is attributed to a high mortality rate related to surgical intervention in the 70s and 80s. Currently, with the innovation of surgical techniques, the approach has become simpler and less interventionist, allowing a decrease in postoperative complication rates. No data were found in the literature regarding the incidental diagnosis of liver tumor, but biopsy was possible in this case. If the anatomopathological study of this patient showed no signs of malignant transformation, the patient could benefit from outpatient follow-up without further interventions4. This reasoning is contrary to the literature of R. Ott and W. Hohenberger (1998)[5] who states that the intervention of benign liver tumors can avoid discomfort in the long term, but these authors also recommend that removal surgery be indicated for symptomatic patients or those with very large tumors. This states that the malignant transformation of UFH is very rare and its follow-up can be enjoyed only on an outpatient basis.

The surgical dimension of a hepatic intervention should be emphasized. A study by J. Pertschy et al (1994)[6] states that laparotomy is necessary for resection of liver tumors almost everywhere, even if atypical or segmental resections of the liver are performed. As previously mentioned, the symptomatology is relevant for surgical decisions and patients are almost always complained of abdominal pain2. The patient reported here complained of this symptom, which was associated with the presence of a stone in the bile duct. It is noteworthy that imaging tests ruled out associated cholecystitis, so it can be associated with a tumor symptom, disregarding differential diagnoses related to the patient's comorbidity.

The therapeutic decision is entirely up to the multidisciplinary team, which comprises the individual submitted to the diagnosis as a whole, exercising person-centered medicine. If multidisciplinary discernment chooses to avoid surgical intervention, some resources can be used in order to perform outpatient follow-up of this patient. The MELD scores and the Child-Pugh score aid in understanding liver function. Expanding resources to the laboratory area, tests such as alpha-fetoprotein are used in the follow-up of hepatocellular carcinomas and their serum concentration is increased in 60-70% of cases, but this accuracy has been widely questioned in recent studies. In a study conducted in a Brazilian population, it was demonstrated that the serum concentration of alpha-fetoprotein was elevated in only 36% of patients with HCC, and its use as a diagnostic tool was not very effective9.

Once we have reasoned out the advantages and disadvantages of a comprehensive surgical approach, we must consider the uncertain biological behavior of the sample taken in biopsy. The patient is outside the epidemiological profile of benign transformations and possibly symptomatic. Therefore, the best therapeutic option to be chosen by the team may be the resection of the affected segment.

CONFLICTS OF INTEREST

The authors state that there is no potential conflict of interest that could compromise the impartiality of the information presented in this scientific article.

REFERENCES

1. Grazzini, G., et al. (2020). Hepatic tumors: pitfall in diagnostic imaging. Acta bio-medica: Atenei Parmensis, 91(8-S), 9-17. https://doi.org/10.23750/abm.v91i8-S.9969

2. Chendid, M. F., et al. (2023). Partial hepatectomy using linear cutter stapler: Are there advantages?. ABCD. Arquivos Brasileiros de Cirurgia Digestiva (São Paulo), 36. Disponível em: https://doi.org/10.1590/0102-672020230057e1775. Acesso em: 29 out. 2024. Epub 08 dez. 2023. ISSN 2317-6326.

3. Bellini, M. I., et al. (2022). Benign hepatic tumors and liver transplantation: A literature review. Experimental and Clinical Transplantation: Official Journal of the Middle East Society for Organ Transplantation, 20(3), 231-236. https://doi.org/10.6002/ect.2021.0447

4. Buell, J. F., et al. (2010). Management of benign hepatic tumors. The Surgical Clinics of North America, 90(4), 719-735. https://doi.org/10.1016/j.suc.2010.04.006

5. Ott, R., & Hohenberger, W. (1998). FNH und Leberzelladenom: Operation oder Beobachtung? [Focal nodular hyperplasia and liver cell adenoma: Operation or observation?]. Zentralblatt für Chirurgie, 123(2), 145-153.

6. Pertschy, J., et al. (1994). Diagnostik und chirurgische Therapie benigner Lebertumoren [Diagnosis and surgical therapy of benign liver tumors]. Zentralblatt für Chirurgie, 119(7), 495-500.

7. Neeff, H., et al. (2009). Leberresektion beim Hepatozellulären Karzinom - Eigene Ergebnisse und Literaturübersicht [Hepatic resection for hepatocellular carcinoma--results and analysis of the current literature]. Zentralblatt für Chirurgie, 134(2), 127-135. https://doi.org/10.1055/s-0028-1098881

8. Instituto Nacional de Câncer (INCA). (2022). Estimativa 2023: Incidência de câncer no Brasil (160 p.). Rio de Janeiro: INCA.

9. Magalhães, C. R., et al. (2023). Perfil clínico e epidemiológico do carcinoma hepatocelular no Brasil. Revista Foco, 16(3), e1388.

10. Instituto Nacional de Câncer (INCA). (2012). Atlas de mortalidade por câncer. Rio de Janeiro: INCA. Disponível em: http://mortalidade.inca.gov.br/Mortalidade/