LUMEN ET VIRTUS

Clinical management in the face of extensive periapical lesion with the presence of a fused metal core

https://doi.org/10.56238/levv15n39-007

Rosana Maria Coelho Travassos[1], Priscila Prosini[2], Maria do Socorro Orestes Cardoso[3], Luciano Barreto da Silva[4], Maria Regina Almeida de Menezes[5], Marcely Cristiny Figueredo Cassimiro da Silva[6], Adriana da Costa Ribeiro[7] and Marina Guimarães Rocha[8]

ABSTRACT

This study aims to present a clinical case of retreatment of a tooth with an extensive periapical lesion with the presence of a fused metal core and clinical and radiographic preservation after two years. A 56-year-old female patient was referred for dental treatment due to the need for retreatment in elements 21 and 22. On clinical examination, the presence of fistula was observed and the patient reported pain on vertical and horizontal percussion, absence of periodontal pocket, and on radiographic examination extensive periapical bone radiotransparency, presence of filling material, as well as molten metal nuclei were observed. Retreatment was performed with rotary instrumentation (Prodesign Logic RT ®). 2.5% Sodium Hypochlorite was used as an irrigating solution, and the intracanal medication used was calcium hydroxide paste (UltraCal®). The filling of the root canal system was performed by the single cone technique associated with active lateral condensation and AH-Plus cement. It is concluded that endodontic retreatment associated with intracanal medication renewal determined clinical and radiographic success.

Keywords: Endodontics, Periapical Diseases, Retreatment.

[1] University of Pernambuco, Brazil
E-mail: rosana.travassos@upe.br
ORCID: https://orcid.org/0000-0003-4148-1288
[2] University of Pernambuco, Brazil
E-mail: priscila.prosini@upe.br
ORCID:https://orcid.org/0000-0002-7199-0414
[3] University of Pernambuco, Brazil
E-mail: socorro.orestes@yahoo.com.br
ORCID: https://orcid.org/0000-0001-9866-0899
[4] University of Pernambuco-Brazil
E-mail: lucianobarreto63@gmail.com
ORCID: http://orcid.org/0000-0002-1508-4812
[5] University of Pernambuco-Brazil
E-mail: regina.menezes@upe.br
ORCID: http://orcid.org/0000-0003-3012-3979
[6] University of Pernambuco, Brazil
E-mail: marcely.cassimiro@upe.br
ORCID: https://orcid.org /0000-0003-0537-9761
[7] University of Pernambuco, Brazil
E-mail: adriana.costaribeiro@upe.br
ORCID: https://orcid.org/ 0009-0005-8337-8096
[8] University of Pernambuco, Brazil
E-mail: marina.guimaraesr@upe.br
ORCID: https://orcid.org/0000-0002-0867-251X

INTRODUCTION

Chronic apical periodontitis is a type of inflammatory pathology that is located in the periapical region of the tooth, characterized by the destruction of the periodontal ligament and resorption of hard tissues, which is generated by the action of osteoclastic cells. It is a sequela of endodontic infection, since microorganisms of various species from infected root canals release virulence factors in the periradicular tissue , initiating and sustaining an inflammatory response to contain the endodontic infection, causing the development of apical periodontitis (Darcey, Qualtrough, 2013). The persistence of a periapical lesion is one of the criteria for determining, in the long term, the failure of treatment. Thus, it is known that infection is the probable cause of a periapical lesion, so the result of endodontic retreatment and its various techniques and biologics will be directly or indirectly involved in this process (TRAVASSOS et al. 2023). Adequate follow-up of the therapeutic conduct, the initial radiographic record, the immediate aspect and the final aspect through these radiographic records is essential (Travassos *et al* 2021).

Conventional endodontic retreatment is indicated in cases in which inadequate endodontic filling of a root canal has occurred, as well as where there is radiographic evidence of the lesion. Another indication for retreatment is in situations of coronary restoration replacement, so that any adverse clinical or radiographic manifestations can be avoided. Also indicated when there is persistence of symptoms, such as discomfort with percussion and palpation; edema or fistula; infeasibility of chewing and mobility (DE Oliveira Claro, 2022).

The use of calcium hydroxide as a medication in cases of teeth with periapical lesions demonstrates advantages due to the antimicrobial action in the root canal system, thus complementing the action of biomechanical preparation and enabling the proper repair of periapical tissues, obtaining action on remaining microorganisms. In addition, this intracanal drug has biological properties such as biocompatibility and inactivation of bacterial endotoxin (MATOS, 2011).

CASE REPORT

The present Final Paper refers to a clinical, descriptive and qualitative case report, in which the conservative retreatment of an extensive periapical lesion is observed. Regarding the ethical terms, the patient signed the Informed Consent Form and the ethical principles described in the Declaration of Helsinki were respected.

A 52-year-old female patient, classified as ASA I, attended the Pernambuco School of Dentistry (FOP) due to the presence of pain in vertical and horizontal percussion. After radiographic

performance, it was found that there was circumscribed periapical bone radiotransparency, unsatisfactory filling and the presence of a fused metal core in teeth 21 and 22. (Figure 1).

Figure 1 - Initial radiographic aspect. Presence of circumscribed periapical bone radiotransparency and fused metal nuclei.



Thus, the treatment plan was outlined, starting with the apparent length of the teeth. After oral antisepsis and infiltrative anesthesia with anesthetic (2% mepivacaine), the metal nuclei were removed with ultrasound tips. After absolute isolation, the filling of the filling material (gutta oercha) with the EasyLogic RT® rotary files (Easy, Jardinópolis, Belo Horizonte – MG, Brazil) was initiated according to the protocol described by the company itself, in the "Crown Down" mode. 21 mm sequence 30.10 torque 4 N and 900 RPM, 25.08 torque 4 N and 900 RPM. The root canals were irrigated with 2.5% sodium hypochlorite due to its bactericidal properties, removing the Smear Layer with the aid of 17% EDTA (Biodinâmica, Ibiporã, PR, Brazil) until complete defilling. The channel was reprepared with Prodesign Logic 2 rotary files, number 40.05.

After drying the canal with absorbent paper tips, intracanal medication based on calcium hydroxide (UltraCal® XS) was placed (Figure 2) and adaptation of the crown, which was cemented with calcium hydroxide cement (Dycal). The medication was renewed monthly for a period of four months, due to the size of the periapical lesion and secondary infection.

Figure 2 - Removal of the filling material and radiographic confirmation of the UltraCal® XS.

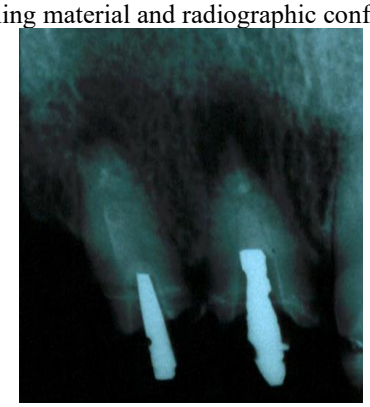

After the absence of discomfort was verified, the gutta-percha cones calibrated with the Maileffer ruler were selected (Figure 3). The filling of the root canal system was performed by the

active lateral condensation technique associated with AH Plus endodontic cement (Dentsply) The patient was referred for the manufacture of a single fixed prosthesis and in the preservation consultation, after 2 years of the filling of the root canals, the radiographic examination demonstrated the complete repair of the periapical lesion, through periapical bone neoformation (Figure 4).

Figure 3- Adaptation of the main gutta percha . Repair of the periapical lesion is observed.



Figure 4 - Radiographic preservation performed after 2 years and fixed prosthesis in both teeth



DISCUSSION

Retreatment is always a greater challenge for the operator, previous quality imaging exams are essential for a smoother and more predictable intervention, they are essential for planning, they reduce the chance of surprises during the procedure, such as anatomical variations, atresias and accentuated curvatures, and the use of efficient and quality materials reduce work time and provide greater comfort to the patient, providing a favorable prognosis. (Mergoni et al., 2022)

It is considered necessary for the operator to have scientific knowledge and manual skill to perform the necessary operative steps that have a higher learning curve. Factors such as a good prognosis, longevity of the treatment and above all the health and function of the tooth in question must be achieved. In this same context, all therapy should be evaluated in its preservation for final confirmation of success in endodontic treatment. The persistence of a periapical lesion is one of the criteria for determining, in the long term, the failure of treatment. Thus, it is known that infection is the probable cause of a periapical lesion, so the result of endodontic retreatment and its various

techniques and biologics will be directly or indirectly involved in this process (TRAVASSOS et al. 2023). Therefore, it is important to note that endodontic treatment does not end with its filling, but after the minimum period of preservation that varies from 6 to 12 months (Travassos et al. 2023). When root canal treatment is insufficient and failure occurs, they can lead to periapical lesions and should be treated. Root canal retreatment is a non-surgical procedure that involves removing the filling materials from the root canal of the tooth, mastering the anatomy, followed by cleaning, shaping, and filling the root canals. (Del Fabbro et al. 2016).

Endodontics is a dental specialty and its function is to repair and treat injuries and diseases that affect the pulp and periapex. Endodontic treatment failure is caused by poorly performed techniques by the Dental Surgeon. Such failures result from microbial factors, indicating an extraradicular or intraradicular infection that has not been cleared during the treatment process. Treatments performed with an ill-fitting or exposed restoration for a long time without an adequate restoration, endodontic retreatment must be performed, causing contamination. (Gouveia, 2024). Endodontic retreatment involves the execution of a new treatment, thus removing the filling material, and reinstrumenting them again. Retreatment is performed because the first has failed or has been contaminated by exposure of the pulp cavity for a prolonged time. (Ritt et al 2012). In the present case, it was decided to renew the intracanal medication based on calcium hydroxide, which was renewed monthly for a period of four months.

It is concluded that, even in teeth with extensive lesions, endodontic retreatment associated with a calcium hydroxide-based medication is indispensable for the complete sanitation of the root canal system, avoiding parendodontic surgery.

REFERENCES

1. Darcey, J., & Qualtrough, A. (2013). Resorption: Part 2. Diagnosis and management. *British Dental Journal, 214*(10), 493-509.

2. De Oliveira Claro, et al. (2022). Retratamento endodôntico seletivo de molar inferior com periodontite apical – relato de caso. *Research, Society and Development, 11*(1), e46411125211-e46411125211.

3. Del Fabbro, M., et al. (2016). Endodontic procedures for retreatment of periapical lesions. *Cochrane Database of Systematic Reviews, 10*, 1-79.

4. Matos, G. R. M., & Filho, M. T. (2011). Resolução por retratamento não cirúrgico de dente com lesão periapical: relato de caso clínico. *Full Dentistry in Science*, 173-176.

5. Mergoni, G., et al. (2022). Single versus multiple visits for endodontic treatment of permanent teeth. *Cochrane Database of Systematic Reviews, 12*(CD005296), 1-124.

6. Ritt, A. S., et al. (2012). Avaliação da eficácia da instrumentação manual x automatizada durante o retratamento endodôntico em canais radiculares obturados com guta-percha e cimento à base de hidróxido de cálcio. *RFO, Passo Fundo, 17*(1), 55-59.

7. Travassos, R. M. C., Oliveira, A. C. C., Charley Gomes Filho, H. P., Sousa, I. S. S., Alves, J. M. S., Santos, K. M., Paz, M. E. S., & Prado, V. F. F. (2021). Análise de regressão da lesão periapical: relato de caso clínico. *Research, Society and Development, 10*(12), e201101220267.

8. Travassos, R. M. C., et al. (2023). Retratamento endodôntico com Prodesign Logic RT: Retratamento endodôntico. *Brazilian Journal of Implantology and Health Sciences, 5*(4), 2393-2408.

9. Gouvea, Y. M. A. (2024). Retratamento endodôntico – Relato de caso clínico. *facsete*. Disponível em: https://facsete.com.br/retratamento-endodontico. Acesso em: 2 de agosto de 2024.