LUMEN ET VIRTUS
ISSN: 2177-2789

COMPARATIVE ANALYSIS OF MACROSCOPIC VS MICROSCOPIC MEASUREMENT CRITERIA OF INDUCED TOOTH MOVEMENT

https://doi.org/10.56238/levv17n56-014

Date of submission: 12/07/2025 **Date of publication:** 01/07/2026

José Roberto Alves Moreira[1], Osmar Aparecido Cuoghi[2], Marcos Rogério de Mendonça[3], Alberto Consolaro[4], Maria Fernanda Martins-Ortiz[5], Henrique Barcelos Brandão[6], Luiz Gonzaga Gandini Junior[7], Ary dos Santos Pinto[8]

ABSTRACT

This study aims to compare microscopic changes in the periodontal ligament (PDL) thickness with macroscopic tooth displacement in a rat model of orthodontic tooth movement. Seventy rats were divided into two experimental groups (GI and GII, N = 30 each) and a control group (GC, N = 10). GI received continuous orthodontic force with a coil spring appliance (50 cN), while GII received interrupted forces, applied in four-day cycles. The experimental groups were randomly subdivided (N = 10 per subgroup), and euthanized on days 8, 16, and 24 post-appliance installation. The distance between the distal face of the last molar and the mesial face of the first molar was measured to assess macroscopic displacement, calculated by subtracting the measurements of the unmoved side. PDL thickness was measured microscopically, and thickness changes (TC) were calculated by subtracting the mean PDL thickness of the control group. Pearson correlation analysis revealed a strong positive correlation between PDL TC and tooth displacement across all time points ($r > 0.83$). No significant differences in macroscopic displacement were observed between GI and GII at any time point ($p > 0.05$), however, the PDL TCs were significantly smaller in GI at all time points ($p < 0.02$), suggesting faster bone formation in this group. Microscopic changes in PDL

[1] Master of Science in Orthodontics. Department of Morphology and Child Clinic – Orthodontics, UNESP, Araraquara, State of São Paulo, Brazil. E-mail: jose.r.moreira@unesp.br Orcid: https://orcid.org/ 0009-0003-1790-2051 Lattes: http://lattes.cnpq.br/5245525150765815

[2] Professor, Department of Orthodontics. School of Dentistry, São Paulo State University (UNESP), Araçatuba Campus, Araçatuba, São Paulo, Brazil. E-mail: osmar.cuoghi@unesp.br Orcid: https://orcid.org/: 0000 0001 7085 9249 Lattes: http://lattes.cnpq.br/8568814008546317

[3] Professor, Department of Orthodontics. School of Dentistry, São Paulo State University (UNESP), Araçatuba Campus, Araçatuba, São Paulo, Brazil. E-mail: rogerio.mendonca@unesp.br Orcid: https://orcid.org/: 0000 0001 8081 9144 Lattes: http://lattes.cnpq.br/1245541242013543

[4] Professor, Department of Orthodontics. Ribeirão Preto Dental School, University of São Paulo (USP), Ribeirão Preto, São Paulo, Brazil. E-mail: consolaro@uol.com.br Orcid: https://orcid.org/: 0000 0002 5902 5646 Lattes: http://lattes.cnpq.br/8436597223735064

[5] Professor, Department of Orthodontics. Integrated College of Three Ponds (Três Lagoas), Três Lagoas, Mato Grosso do Sul, Brazil E-mail: mfmartinsortiz@gmail.com Orcid: https://orcid.org/: 0000 0002 7826 0879 Lattes: http://lattes.cnpq.br/7907345074518109

[6] Master of Science in Orthodontics. Department of Morphology and Child Clinic – Orthodontics, UNESP, Araraquara, State of São Paulo, Brazil. E-mail: henrique.brandao@unesp.br Orcid: https://orcid.org/0000-0002-7238-7078 Lattes: https://lattes.cnpq.br/2053748244308327

[7] Professor, Department of Orthodontics. Department of Morphology and Child Clinic – Orthodontics, UNESP, Araraquara, State of São Paulo, Brazil. E-mail: luiz.gandini@unesp.br Orcid: https://orcid.org/0000-0001-8656-6010 Lattes: http://lattes.cnpq.br/6493049604923160

[8] Professor, Department of Orthodontics. Department of Morphology and Child Clinic – Orthodontics, UNESP, Araraquara, State of São Paulo, Brazil. E-mail: ary.santos-pinto@unesp.br Orcid: https://orcid.org/ 0000 0003 3355 0001 Lattes: http://lattes.cnpq.br/6562540057111580

TC correlated strongly with macroscopic tooth displacement in our rat model. Bone formation was achieved faster in the continuous force group compared to the interrupted force group while the final tooth displacement was similar.

Keywords: Orthodontic Tooth Movement. Periodontal Ligament. Microscopic. Macroscopic. Experimental Animal Models.

ANÁLISE COMPARATIVA DE CRITÉRIOS DE MEDIÇÃO MACROSCÓPICO VS MICROSCÓPICO DE MOVIMENTO DENTÁRIO INDUZIDO

RESUMO

Este estudo tem como objetivo comparar alterações microscópicas na espessura do ligamento periodontal (LPD) com o deslocamento dentário macroscópico em um modelo de movimentação dentária ortodôntica em ratos. Setenta ratos foram divididos em dois grupos experimentais (GI e GII, N = 30 cada) e um grupo controle (GC, N = 10). O GI recebeu força ortodôntica contínua com aparelho de mola helicoidal (50 cN), enquanto o GII recebeu forças interrompidas, aplicadas em ciclos de quatro dias. Os grupos experimentais foram subdivididos aleatoriamente (N = 10 por subgrupo) e eutanasiados nos dias 8, 16 e 24 após a instalação do aparelho. A distância entre a face distal do último molar e a face mesial do primeiro molar foi medida para avaliar o deslocamento macroscópico, calculado subtraindo as medidas do lado não movimentado. A espessura do LPD foi medida microscopicamente e as alterações de espessura (TC) foram calculadas subtraindo-se a espessura média do LPD do grupo controle. A análise de correlação de Pearson revelou uma forte correlação positiva entre o CT do LPD e o deslocamento dentário em todos os momentos ($r > 0,83$). Não foram observadas diferenças significativas no deslocamento macroscópico entre GI e GII em nenhum momento ($p > 0,05$), no entanto, os CTs do LPD foram significativamente menores no GI em todos os momentos ($p < 0,02$), sugerindo formação óssea mais rápida neste grupo. Alterações microscópicas no PDL TC correlacionaram-se fortemente com o deslocamento macroscópico do dente em nosso modelo de rato. A formação óssea foi alcançada mais rapidamente no grupo de força contínua em comparação com o grupo de força interrompida, enquanto o deslocamento final do dente foi semelhante.

Palavras-chave: Movimentação Dentária Ortodôntica. Ligamento Periodontal. Microscópico. Macroscópico. Modelos Animais Experimentais.

ANÁLISIS COMPARATIVO DE CRITERIOS DE MEDICIÓN MACROSCÓPICO VS MICROSCÓPICO DEL MOVIMIENTO DENTAL INDUCIDO

RESUMEN

Este estudio tiene como objetivo comparar los cambios microscópicos en el grosor del ligamento periodontal (LPD) con el desplazamiento macroscópico de los dientes en un modelo de movimiento dental ortodóncico en ratas. Setenta ratas se dividieron en dos grupos experimentales (GI y GII, N = 30 cada uno) y un grupo de control (GC, N = 10). GI recibió fuerza ortodóncica continua con un aparato de resorte helicoidal (50 cN), mientras que GII recibió fuerzas interrumpidas, aplicadas en ciclos de cuatro días. Los grupos experimentales se subdividieron aleatoriamente (N = 10 por subgrupo) y se sacrificaron los días 8, 16 y 24 después de la instalación del dispositivo. Se midió la distancia entre la cara distal del último molar y la cara mesial del primer molar para evaluar el desplazamiento macroscópico, calculado restando las medidas del lado inmóvil. El espesor del PDL se midió microscópicamente y los cambios de espesor (TC) se calcularon restando el espesor medio del PDL del grupo de control. El análisis de correlación de Pearson reveló una fuerte

correlación positiva entre PDL TC y el desplazamiento de los dientes en todos los puntos temporales ($r > 0,83$). No se observaron diferencias significativas en el desplazamiento macroscópico entre GI y GII en ningún momento ($p > 0,05$); sin embargo, los TC del PDL fueron significativamente más pequeños en GI en todos los momentos ($p < 0,02$), lo que sugiere una formación ósea más rápida en este grupo. Los cambios microscópicos en PDL TC se correlacionaron fuertemente con el desplazamiento macroscópico de los dientes en nuestro modelo de rata. La formación ósea se logró más rápido en el grupo de fuerza continua en comparación con el grupo de fuerza interrumpida, mientras que el desplazamiento final de los dientes fue similar.

Palabras clave: Movimiento Dental Ortodóncico. Ligamento Periodontal. Microscópico. Macroscópico. Modelos Animales Experimentales.

1 INTRODUCTION

Orthodontic planning aims to set therapeutic goals for achieving the best relationship between the dental arches and the cranio-mandibular complex. This should result in the desired normocclusion, which, when properly maintained, supports inter-arch stability and enhances facial aesthetics.[1] In vivo experiments are crucial for orthodontic planning, providing information on relationship between applied forces and tissue remodeling. In recent years, rats have become the animal of choice for these in vivo experiments due to their relatively inexpensive housing, simple histological preparation methods, availability of antibodies for molecular studies, and relatively large size (compared to mice) allowing easy application of appliance.[2,3]

Measuring tooth movement in rat models have proven to be challenging, with many studies inappropriately reporting their measurement technique, not defining reproducible landmarks, or using two-dimensional radiological techniques that have the disadvantage of object superimposition.[3]

Microscopic evaluation of periodontal ligament (PDL) thickness is a proposed measurement technique for tooth movement.[4] This technique, has the advantage of providing extra information on histomechanical properties of moved tooth, allowing researchers to asses histology and its relationship with tissue remodeling. Microscopic evaluation of tooth movement can also potentially allow concomitant studying of medications, systemic and local clinical conditions, and types of forces and movements. To this end, we designed this study to find relationship between macroscopic and microscopic measurements of tooth movement, through defining reproducible landmarks for both techniques allowing future researchers to apply both methods in their studies of orthodontic tooth movement (OTM). The main aim of this study was to assess correlation between microscopic measurement of PDL thickness change with macroscopic measurement of tooth displacement in a rat experimental model.

As the secondary aims, we compare interrupted force OTM to uninterrupted continuous force OTM in terms of final macroscopic displacement and microscopic PDL thickness changes. Furthermore, we assess whether displaced teeth revert to their original location following removal of the appliance.

2 METHODOLOGY

This study was designed as an experimental research project and conducted at the XXX. The project was approved by the Animal Experimentation Ethics Committee (CEEA) of the XXX under protocol no. 2008-004460 in accordance with XXX. Seventy male Wistar rats (Rattus norvegicus, albinos) weighing between 250 and 350g and approximately 90 days old

were used. The animals, obtained from the XXX, were housed in groups of five per cage and fed granulated chow (XXX) with water provided ad libitum.

The models were divided into Experimental Groups (GI and GII) and a Control Group (GC). All animals in GI and GII had an appliance for inducing tooth movement installed between the upper incisors and the upper right first molar. GI consisted of 30 animals, subjected to continuous forces, and further divided into three subgroups of ten animals each. After the initiation of induced tooth movement, the animals were euthanized at the experimental time points of eight, 16, and 24 days.

GII included the same number of animals as in GI and their respective subgroups, but they were subjected to interrupted continuous forces at the experimental time points of eight, 16, and 24 days. The forces were interrupted by loosening the ligature attached to the incisors, without removing the springs, for a period of four days after their application for the same duration. The animals were euthanized after completing eight days, and those in the 16 and 24-day subgroups repeated the same cycles of interruption and reactivation until completing the experimental period from the onset of induced tooth movement.

Control Group (GC): This group consisted of ten animals that were not subjected to induced tooth movement. The right hemimaxillae of these animals underwent histotechnical processing.

In this research, the tooth movement-inducing appliance developed by Heller and Nanda[5] was used. The appliance consisted of a three-millimeter closed-coil spring that released 50 cN of force (Sentalloy, COIL SPRINGS model 10-000-25, manufactured by GAC International - Japan), batch numbers A348, A447, A476, A398. The use of these springs for retraction allowed for the verification of continuous force and its interruption.[6-9] To enhance the retention of the device and prevent potential displacement, 0.25 mm diameter ligature wires (Morelli, Sorocaba, SP - Brazil), tied to the incisors, were coated with light-curing resin Opallis (FGM Produtos Odontológicos, Joinville, Santa Catarina - Brazil).

During the installation and maintenance of the mechanical device, a mixture of the muscle relaxant Xylazine Hydrochloride (Dopaser) at a dose of 0.03 ml/100 g of body weight and the anesthetic Ketamine Hydrochloride (Vetaset) at a dose of 0.07 ml/100 g of body weight was administered intramuscularly. This combination provided approximately two hours of analgesia, sufficient to safely install the devices while preventing any signs of pain or anxiety in the animals. Analgesia was repeated in Group GII during the periods of force interruption (loosening of the incisor ligatures) as well as during their reactivation.

To acclimate and maintain the subjects prior to experimental procedures, the animals were housed in cages for seven days under a 12/12-hour light cycle and constant temperature.

After completing the adaptation period, the animals assigned to Experimental Groups GI and GII were prepared in advance of the procedures. After weighing, they received appropriate doses of analgesics and relaxants, and were monitored to assess the effectiveness of the administered treatments. Only after confirming efficacy did the installation of the devices begin.

Prior to installation, the terminal rods of the springs were trimmed using a high-speed diamond drill (KG Sorensen 3113F), reducing their length so that they could be properly stretched within the space between the incisors and the upper right first molar, thus allowing effective activation. Using ligatures to attach the springs to the molars, the springs were stretched after secure fixation by tying the other end to the incisors.

To prevent displacements and/or fractures of the appliances during the experimental periods and avoid exclusion of any animal, two preventive measures were established: A. immediately after appliance installation, the lower incisors were reduced by approximately one mm using a high-speed diamond drill (KG Sorensen 3113F) to prevent trauma during mastication; B. granular feed was provided as the regular diet for maintaining the animals, intentionally starting from the acclimatization period. With these precautions, the animals were observed every four days, and the correct positioning of the appliances was checked, with any necessary repositioning carried out as needed.

After completing the experimental periods of eight, 16, and 24 days in GI and GII, the animals were euthanized using a muscle relaxant (Xylazine Hydrochloride 0.03 ml/100 g body weight) and twice the anesthetic dose (Ketamine Hydrochloride 0.14 ml/100 g body weight). Subsequent steps included decapitation and dissection to remove soft tissues, collecting the experimental hemimaxilla with preservation limited to the molar regions. Prior to sectioning the specimens, three observers took two measurements of the maxilla to quantitatively assess the macroscopic movement achieved on the experimental sides and the control side, using a Mitutoyo Absolute Digimatic digital caliper model CD-6”CSX-B (Mitutoyo Sul Americana Ltda., Suzano - SP - Brazil).

To standardize the measurement procedure among examiners, the maxilla was placed on the surgical field, on a clinical table, and under the illumination of a dental reflector. Examiners used a loupe (Intex Brasil), providing 3.5x magnification, and positioned the caliper on the specimen with the tips placed on the most cervical regions of the distal face of the last molar and the mesial face of the first molar. Data were collected from both the moved and unmoved sides.

The displacement quantity after dental movement was obtained using the method of Gameiro et al. (2008),[10] measured as the difference between the moved and unmoved sides. These measurements were collected by three examiners and an average was calculated.

Dissection of the hemimaxilla was restricted and standardized to the region of the first molar to prevent adjacent tissue excess from affecting the demineralization rate, ensuring morphological preservation of the tissues and a good technical outcome. The specimens to be fixed were labeled and stored in cassettes, and immersed in a 10% formalin solution (v/v) (4 g of monosodium phosphate, 6.5 g of disodium phosphate, 900 ml of distilled water, 100 ml of formalin p.a.), in a quantity twenty times greater than their volumes, for 48 hours. At the end of fixation, the specimens were washed in running water for 24 hours and then decalcified in a 5% Disodium Ethylenediaminetetraacetate (EDTA) solution for six weeks, followed by another 24-hour wash in running water.

Following decalcification, dehydration was performed followed by embedding the specimens in paraffin blocks. These blocks were then sectioned using a Leitz microtome (Germany). The sections were carefully positioned and cutting began with constant observation from the removal of the first ribbons to ensure the most parallel alignment possible to the occlusal face. Sections were cut until a ribbon containing the beginning of the interradicular septum was obtained, where the presence of the five well-defined and separated roots was observed. Serial sections, 6 µm in thickness, of the upper right first molar were collected in sets of five, starting from the first section where clear separation of the roots was evident. Subsequently, the five ribbons were properly positioned on slides, ensuring the correct sequence of the cuts, and were stained with Harris hematoxylin and Lison eosin.

Images of the tissue sections were captured using a Canon PowerShot A 640 digital camera, with a ten-megapixel resolution, attached to a Carl Zeiss Axiophot binocular optical microscope (Germany) equipped with a 2.5x / 0.075 objective (for panoramic viewing) and properly calibrated. The focus was primarily on the intermediate vestibular root and mesial root for histometric analysis. Measurements were recorded and stored on a computer using AxioVision 4.6 software (Carl Zeiss, Germany) for future analysis.

The histological sections were digitized to outline and delineate variations in the thickness of the periodontal ligament in the traction (distal) region of the intermediate vestibular root. This region was chosen due to its smaller volume and distance from potential inflammatory areas (distal region of the distal root and mesial region of the mesial root), which might have been affected by the trauma from the ligature wire. Reference lines and points used to measure the periodontal ligament thickness in the intermediate vestibular root were established starting from the mesial root.

Line 1: The greatest mesiodistal length of the pulp canal lumen (mesial root). Point **1** : Perpendicular to Line 1, at its midpoint, is Point 1.

Line 2: The greatest mesiodistal length of the pulp canal lumen (intermediate vestibular root).

Point 2: Perpendicular to Line 2, at its midpoint, is Point 2.

The measurement of the periodontal ligament, captured by AxioVision 4.6 software (Carl Zeiss, Germany), which determined the thickness of the periodontal ligament, was obtained by extending the line connecting Point 1 to Point 2 until it reached the alveolar bone in the distal portion of the intermediate vestibular root (Figure 1A-B). The measurement was taken along this line, recording the distance between the cementum of the intermediate vestibular root and the alveolar bone.

Figure 1

Measurement of periodontal ligament thickness. (A) The union of points 1 and 2, and their extension, determine the line to measure the thickness of the periodontal ligament. (B) Line drawn from point 1, passing through point 2, measuring the thickness of the periodontal ligament over its extension (cementum of the intermediovestibular root to the hard lamina of the alveolar bone distal portion of the intermediovestibular root). Staining - HE, objective - 4 times. Arrow shows the direction of the force.

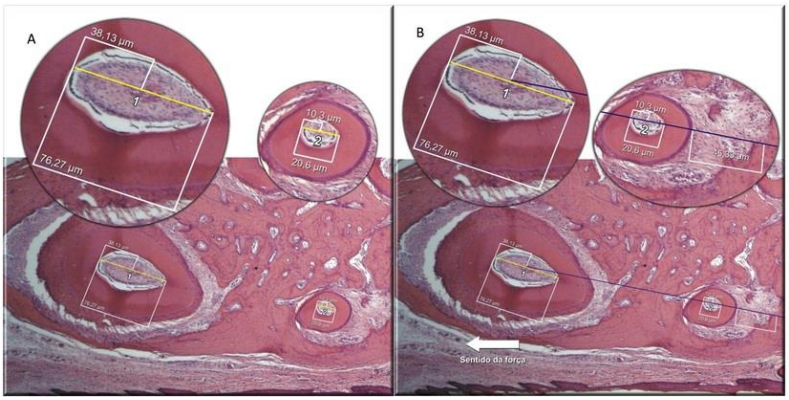

2.1 STATISTICAL ANALYSIS

PDL thickness change (TC) was calculated by subtracting the PDL thickness of the experimental animal from the mean PDL thickness of control animals. Displacement was calculated macroscopically by subtracting the moved side measurement from the unmoved side.

The data tables display the means and standard deviations (SD) of periodontal ligament thickness for each group (GI, GII, and Control) at eight, 16, and 24 days. Intra-group comparisons were made for the 8, 16, and 24-day periods, while inter-group comparisons between GI and GII at the same time points were performed using the Student's t-test and

confirmed by Tukey's test. The correlation between micrometric and macrometric measurements was assessed using the Pearson Correlation Coefficient.

3 RESULTS

From a tissue volume perspective, the periodontal space during induced dental movement was increased compared to the Control Group (Figure 2) at all three time points in both experimental groups.

Figure 2

Increased periodontal space in the experimental groups. (A) Regular periodontal space of approximately 0.12 - 0.16 mm for the Control Group.[11] (B) Increased periodontal space in the distal portion in the Experimental Group (HE staining, objective - 2.5 times). (arrow in the distomesial direction).

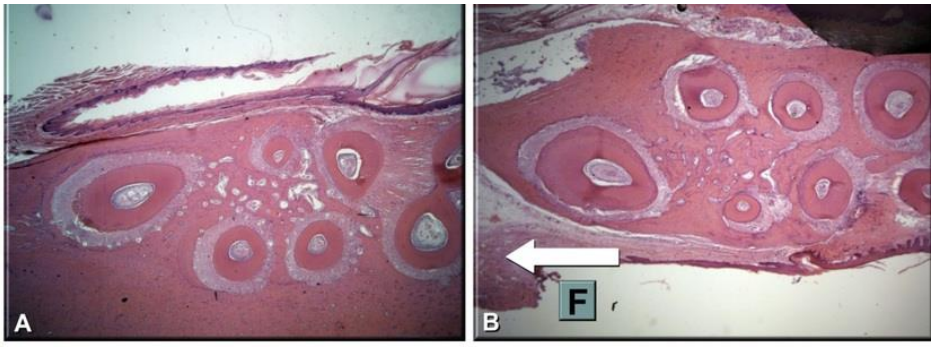

Table 1 shows measurements of PDL thickness, its change from control, and macroscopic displacement at each time point. Both groups showed increased PDL thickness on day eight. In GI, however, mean TC was negative on day 16 and close to zero on day 24. Table 2 shows the t-test results of within group comparison between time points. PDL TC on day eight was significantly different from day 16 ($p = 0.004$) but not from day 24 ($p = 0.27$). In the interrupted group, mean TC ± SD was lower on day 16 (38.12 ± 20.71) and day 24 (44.53 ± 10.76) compared to day eight ($p = 0.003$ and 0.008 respectively, Table 2). Macroscopically, the highest displacement was measured on day 24 in both GI and GII. T-test showed that between GI and GII, the amount of macroscopic displacement was not significantly different at any time point ($p = 0.23$, 0.52, and 0.16 for days eight, 16, and 24, respectively), while PDL TC was significantly different ($p < 0.05$ for all time points).

Table 1 shows the correlation between macroscopic displacement and microscopic PDL TC at each time point. On both groups there were strong positive correlation between the two calculations.

Table 1

Measurements, displacements, and correlation between microscopic and macroscopic calculations in rat experimental model of induced tooth movement.

		Microscopic measurement (PDL thickness, μm)		Macroscopic measurement (distance*, mm)			Correlation# (r)
	Day	Mean ± SD	PDL TC, mean ± SD	Moved side, mean ± SD	Unmoved side, mean ± SD	Displacement, mean ± SD	
GI	8	154.69 ± 38.89	25.58 ± 26.28	7.20 ± 0.13	6.95 ± 0.12	0.25 ± 0.10	0.83
	16	127.02 ± 39.16	-2.09 ± 26.73	7.31 ± 0.12	7.00 ± 0.12	0.31 ± 0.12	0.95
	24	132.90 ± 53.86	3.79 ± 39.56	7.49 ± 0.13	7.09 ± 0.13	0.40 ± 0.13	0.92
GII	8	204.41 ± 36.15	75.30 ± 25.36	7.13 ± 0.07	6.93 ± 0.10	0.20 ± 0.08	0.82
	16	167.23 ± 31.18	38.12 ± 20.71	7.27 ± 0.09	6.98 ± 0.10	0.29 ± 0.04	0.95
	24	173.64 ± 26.10	44.53 ± 10.76	7.43 ± 0.19	6.96 ± 0.16	0.47 ± 0.10	0.92
GC	-	129.11 ± 18.43	-	-	-	-	

Thickness change in the microscopic measurement was calculated by subtracting the PDL thickness of the experimental animal from the mean PDL thickness of control animals. Displacement was calculated macroscopically by subtracting the moved side measurement from the unmoved side.

(*) Distance between the most cervical region of the distal face of the last molar and the mesial face of the first molar; (#) Pearson correlation coefficient between microscopic PDL thickness change and macroscopic displacement; GI: Group I, underwent uninterrupted (continuous) force; GII: Group II, underwent interrupted force; GC: control group; PDL: periodontal ligament; SD: standard deviation; TC: thickness change.

Table 2

Pearson correlation and paired t-test for within group comparison of induced tooth displacement between different time points.

Group		Microscopic displacement				Macroscopic displacement			
		Day 16		Day 24		Day 16		Day 24	
		r	t-test (p)	r	t-test (p)	r	t-test (p)	r	t-test (p)
GI	Day 8	0.84	0.004*	0.91	0.27	0.92	0.18	0.91	0.01*#
	Day 16	-	-	0.97	0.39	-	-	0.92	0.17
GII	Day 8	0.98	0.003*#	0.98	0.006*#	0.95	0.01*#	0.96	<0.001*#
	Day 16	-	-	0.99	0.42	-	-	0.95	<0.001*#

(*) $p < 0.05$: statistically significant; (#) Tukey test confirmed.

4 DISCUSSION

The PDL in humans is a connective tissue, abundant in type I collagen fiber, with an average thickness of 0.2 mm, ranging between 0.15 to 0.38 depending on its location on the root.[11] On the root surface, the deposited cementum has a thickness of 0.5 to 0.10 mm in the cervical and middle portions. The internal surface of the alveolus is covered by a thin layer of woven bone, which represents a true alveolar lining of ectomesenchymal origin. On the cementum surface, osteoremodeling units are rarely observed in their Howship's lacunae, but they are frequently present on the bone surface, without significant periodontal irregularities on the alveolar bone surface.

During induced dental movement, numerous osteoremodeling units and Howship's lacunae develop on the alveolar bone surface, creating irregularities associated with the periodontal ligament, which becomes rich in cellular mediators and inflammatory exudate due to cellular compression and hypoxia from reduced blood vessel caliber. OTM in its final stage leads to coordinated resorption and formation of tissues in the surrounding bone and periodontal ligament.[9,11-13] This new bone formation may explain why PDL thickness in our study initially increased (GI and GII on day eight, Table 1) while it decreased in later days in GI or the amount of change was lowered in GII. The constant positive macroscopic tooth movement (Table 1) in our study indicates possible replacing of PDL with alveolar bone.

In the experimental model of Heller and Nanda,[5] after the tenth day, the experimental appliances inducing movement, anchored on the incisors, tended to become loose due to wear from attrition and continuous dental eruption. These two phenomena were not observed in the murine molars, only in the incisors, as the latter exhibited continuous odontogenesis. Beyond 8th day of OTM, the incisors may undergo partial rotation in the alveolus causing distal displacement, significantly reducing the distance between the incisors and the first molar, which has also been moved mesially. This may be another reason that both groups had the thickest PDL on day eight. However, given that the macroscopic tooth movement was not affected, it is unlikely that reduced tension due to reduced distance is causing this discrepancy.

Lastly, the macroscopic measurements were taken at the coronal level, while microscopic measurements were taken at the cervical root level. The discrepancy may mean that the teeth were tilted. Unfortunately, our study is limited due to lack of detailed histological description, including evidence of bone neoformation that could potentially differentiate between tilted tooth and new alveolar bone formation.

After periods of appliance activation and subsequent dissipation of forces, the periodontal tissues tend to repair, with deactivation of osteoremodeling units and reversal of resorptive processes. On the bony surfaces, this reversal is characterized by the

disappearance of osteoclasts and the appearance of a basophilic line marking the resumption of bone synthesis and deposition. This line is known as the traumatic calcium line or reversal line. During the process of periodontal tissue reorganization and repair, including fibroblast and collagen fiber rearrangement and reversal of resorptive processes, the reapplication of forces may induce a more extensive or intense disorganization and hypoxia compared to normal tissues.[14-16]

In our study, the interruption of forces in GII every four days lead to a greater PDL thickness, despite similar macroscopic dislocation compared to the uninterrupted GI model. This suggests delayed alveolar bone neoformation, possibly due to interrupted osteoblast activity and/or increased inflammation. This exacerbation of periodontal ligament thickness can, in a broad sense, be extrapolated to orthodontic clinical situations characterized by reciprocating movements, such as the use of intermaxillary elastics.[14]

Finally, examining the displacement in the interrupted force experimental group (GII) on day eight (Table 1), it can be inferred that after the force was interrupted on day four, the teeth did not completely return to their original position.

5 CONCLUSION

Microscopical measurement of periodontal ligament thickness and its changes during induced tooth movement strongly and positively correlated with macroscopic displacement on days eight, 16, and 24 post-installation. Both interrupted and uninterrupted continuous forces efficiently moved the teeth with comparable results, however, the changes in the periodontal ligament thickness were not similar between groups, suggesting faster bone formation by continuous uninterrupted force. The teeth did not move back to their original location within four days of removal of the appliance.

ACKNOWLEDGMENTS

We would like to express our deep gratitude to the entire technical team of the animal facility for their support and attention throughout the development of the project, as well as technicians Maria Dirce Colli Boatto and Gilmar Martins de Oliveira for their technical and laboratory support.

This study was designed as an experimental research project and conducted at the Center for Experimental Surgery Research, Prof. Dr. Tetuo Okamoto, at the School of Dentistry of Araçatuba - São Paulo State University (UNESP). The project was approved by the Animal Experimentation Ethics Committee (CEEA) of the School of Dentistry of Araçatuba - UNESP

under protocol no. 2008-004460 in accordance with the Ethical Principles in Animal Experimentation of the Brazilian College of Animal Experimentation (COBEA).

Seventy male Wistar rats (Rattus norvegicus, albinos) weighing between 250 and 350g and approximately 90 days old were used. The animals, obtained from the Animal Facility of the School of Dentistry of Araçatuba - UNESP, were housed in groups of five per cage and fed granulated chow (Probiotério MP-77, Moinho Primor S.A., São Paulo, Brazil) with water provided ad libitum.

REFERENCES

1. Arnett GW, Jelic JS, Kim J, et al. Soft tissue cephalometric analysis: diagnosis and treatment planning of dentofacial deformity. Am J Orthod Dentofacial Orthop 1999;116(3):239–53.

2. Ren Y, Maltha JC, Kuijpers-Jagtman AM. The rat as a model for orthodontic tooth movement-a critical review and a proposed solution. Eur J Orthod 2004;26(5):483–90.

3. Kirschneck C, Proff P, Fanghaenel J, Behr M, Wahlmann U, Roemer P. Differentiated analysis of orthodontic tooth movement in rats with an improved rat model and three-dimensional imaging. Ann Anat 2013;195(6):539–53.

4. Cuoghi OA, Tondelli PM, Aiello CA, Mendonça MR de, Costa SC da. Importance of periodontal ligament thickness. Braz Oral Res 2013;27(1):76–9.

5. Heller IJ, Nanda R. Effect of metabolic alteration of periodontal fibers on orthodontic tooth movement. An experimental study. Am J Orthod 1979;75(3):239–58.

6. Miura F, Mogi M, Ohura Y, Hamanaka H. The super-elastic property of the Japanese NiTi alloy wire for use in orthodontics. Am J Orthod Dentofacial Orthop 1986;90(1):1–10.

7. Miura F, Mogi M, Ohura Y, Karibe M. The super-elastic Japanese NiTi alloy wire for use in orthodontics. Part III. Studies on the Japanese NiTi alloy coil springs. Am J Orthod Dentofacial Orthop 1988;94(2):89–96.

8. Gianelly AA, Bednar J, Dietz VS. Japanese NiTi coils used to move molars distally. Am J Orthod Dentofacial Orthop 1991;99(6):564–6.

9. King GJ, Keeling SD, McCoy EA, Ward TH. Measuring dental drift and orthodontic tooth movement in response to various initial forces in adult rats. Am J Orthod Dentofacial Orthop 1991;99(5):456–65.

10. Hauber Gameiro G, Nouer DF, Pereira Neto JS, et al. Effects of short- and long-term celecoxib on orthodontic tooth movement. Angle Orthod 2008;78(5):860–5.

11. Li Y, Jacox LA, Little SH, Ko C-C. Orthodontic tooth movement: The biology and clinical implications. Kaohsiung J Med Sci 2018;34(4):207–14.

12. Lv T, Kang N, Wang C, Han X, Chen Y, Bai D. Biologic response of rapid tooth movement with periodontal ligament distraction. Am J Orthod Dentofacial Orthop 2009;136(3):401–

11.

13. Gonçalves A, Mathelié-Guinlet Q, Ramires F, et al. Biological alterations associated with the orthodontic treatment with conventional appliances and aligners: A systematic review of clinical and preclinical evidence. Heliyon 2024;10(12):e32873.

14. Graber TM, Vanarsdall Junior RL, Vig KWL. Orthodontics: Current Principles &Techniques. 4th ed. St Louis: Elsevier, 2005. 1232 p.

15. Jeon HH, Teixeira H, Tsai A. Mechanistic Insight into Orthodontic Tooth Movement Based on Animal Studies: A Critical Review. J Clin Med 2021;10(8):1733.

16. Nakai Y, Praneetpong N, Ono W, Ono N. Mechanisms of Osteoclastogenesis in Orthodontic Tooth Movement and Orthodontically Induced Tooth Root Resorption. J Bone Metab 2023;30(4):297–310.