LUMEN ET VIRTUS

What is the prevalence of tumors that cause the loss of bone structures in the face?

https://doi.org/10.56238/levv15n38-070

Isabela Ferrari Lima[1]
Mariana do Nascimento Borba[2]
Samara Maria da Silva[3]
Anna Beatriz Arruda Barroso de Moraes[4]
Irani de Farias Cunha Junior[5]

ABSTRACT

INTRODUCTION: Tumors are a tissue growth disorder, benign tumors are usually well defined, while malignant tumors can spread and lead to death. In some cases, the first indication of the presence of a bone tumor is a pathological fracture, especially those that have bone involvement. OBJECTIVE: To identify the prevalence and incidence of tumors that cause loss of facial bone structures, in addition to analyzing the efficacy of surgical treatment in cases of tumors that destroy facial bone structures. METHODOLOGY: This is a literature review in which the search for articles was carried out in the LILACS and MEDLINE databases through the electronic libraries Virtual Health Library (VHL) and Pubmed, respectively. A total of 13 articles were selected to compose the study, filtered by the inclusion and exclusion criteria sought from the DECS/MESH descriptors: Odontogenic Tumors, Mandible, Maxilla, Ameloblastoma, Incidence, Prevalence, Maxillomandibular Neoplasms, Oral Diagnosis, Oral Surgery, Predisposing Factors, Mortality, Osteosarcoma and Bone Neoplasms, using the Boolean operator "and". RESULTS: It was seen that most odontogenic tumors are benign, the most recorded cases are in the third and fourth decade of life and most are located in the mandible, more specifically in the posterior region, while in malignant tumors this predisposition is noted around the fourth decade. The main aid for suspected diagnosis is the use of imaging tests. CONCLUSION: It is concluded that tumors that cause bone loss mainly affect men between 22 and 56 years of age and that surgery is the best treatment to prevent recurrence.

Keywords: Prevalence, Odontogenic Tumors, Maxillomandibular Neoplasms.

[1] E-mail: isabela.ferrari@ufpe.br
LATTES: http://lattes.cnpq.br/0144985823755586
[2] E-mail: mariana.nascimentoborba@ufpe.br
LATTES: http://lattes.cnpq.br/5984437187190879
[3] E-mail: samara.msilva@ufpe.br
LATTES: https://lattes.cnpq.br/0052803482855785
[4] Email: anna.arruda@ufpe.br
LATTES: https://lattes.cnpq.br/8331337562599875
[5] Email: irani.cunhajr@ufpe.br
LATTES: http://lattes.cnpq.br/3985540334863481

INTRODUCTION

Tumor can be defined as a tissue growth disorder triggered by a series of mutations affecting a single cell and its clonal progeny. These mutations provide neoplastic cells with a survival and growth advantage, resulting in an excessive proliferation that is independent of physiological growth signals (KUMAR; ASTER; ABBAS, 2016).

A tumor is benign when its microscopic and macroscopic aspects are considered relatively innocent, restricting its location to a well-defined region. Malignant tumors (cancers) can invade and destroy adjacent structures and spread to distant areas (metastasize), leading to death. However, not all cancers follow a deadly course, some are discovered early enough to be surgically excised or treated positively with chemotherapy and radiotherapy (KUMAR; ASTER; ABBAS, 2016).

Primary bone tumors are rare, and surgery, often disfiguring, is necessary for the treatment of malignancies, which can present in a variety of ways. The most common benign lesions are often asymptomatic and discovered accidentally. However, many tumors are symptomatic, which characterizes a high discomfort for the patient. In some circumstances, the first indication of the presence of a bone tumor is a pathological fracture, so radiographic examinations play an important role in the diagnosis of these lesions (KUMAR; ASTER; ABBAS, 2016).

Another possible tissue proliferation process is those involving odontogenic tumors - resulting from the teeth-forming apparatus - divided mainly into two categories: malignant and benign. These are rare neoplasms that constitute less than 1% of oral tumors, but the knowledge of these by the dentist can make a total difference in the treatment of an affected patient (SOLUK-TEKKESIN; WRIGHT, 2022; XIA *et al*, 2023).

Therefore, the objective of this literature review is to evaluate the prevalence and incidence of tumors that cause the loss of facial bone structures, in order to address benign and malignant tumors, predisposing factors, early diagnosis, and surgical treatment.

THEORETICAL FRAMEWORK

TUMORS THAT CAUSE BONE LESIONS

These are tumors that have bone involvement and appearance and can come from different places. Regarding the face, ameloblastoma is the most frequently identified example of odontogenic neoplasm - originating from the odontogenic epithelium, it can be found in the maxilla, mandible, paranasal sinuses and skull base. Also common, odontomas are tissue clusters that can also be identified in the clinical life of dental surgeons (EL-NAGGAR *et al*., 2017 apud HASYIM *et al*., 2023).

Benign tumors

Benign tumors are usually designated from the insertion of the suffix *oma* to the nomenclature of the originating cell type, such as mesenchymal cells (KUMAR; ASTER; ABBAS, 2016). Lipomas are the most common benign mesenchymal tumors, comprising mature adipocytes without atypia. They can occur wherever there is adipose tissue, but they are commonly found in intramuscular, retroperitoneal, and bone tissue, such as the intraosseous lipoma of the maxilla - the latter being rare and responsible for bone lesions, pain, and paresthesia (PÉRES, 2010 apud TABAKOVIC *et al*., 2018).

Tumores malignos

Malignant tumors can invade and destroy adjacent structures and be disseminated to the most diverse body areas, which can lead to death. These tumors are poorly differentiated, have high growth rates and can cause metastases. Regarding facial tumors, odontogenic carcinosarcoma (OSC) is an example of an extremely rare malignant mixed neoplasm, characterized by being a biphasic tumor predominant in both epithelial and mesenchymal components. This phenomenon is complex and responsible for painful lesions in the jaw, often from an untreated ameloblastoma that has undergone malignant changes (EL-NAGGAR *et al*., 2017 apud HASYIM *et al*., 2023; KUMAR; ASTER; ABBAS, 2016).

PREVALENCE AND INCIDENCE OF TUMORS

A general analysis of the frequency of odontogenic tumors and cysts brought clinical data from several countries, resulting in the frequency of odontogenic tumors, in which ameloblastoma leads (36.6%), followed by odontogenic keratocyst, the latter when it was considered an odontogenic tumor (8.3%), myxoma (3.8%), followed by adenomatoid odontogenic tumor (3.2%) and, finally, ameloblastic fibroma (1.1%). In a study carried out in Enugu, Nigeria, the tumors with the highest incidence were mapped and analyzed - finding a total of 11 benign cases (64.7%) and 6 malignant cases (35.3%). Ameloblastoma has a high recurrence rate when compared to other odontogenic tumors due to its local invasion, high growth rate, aggressive behavior, and malignant transformation (NWOGA, 2022).

Mortality

Ameloblastic carcinomas are aggressive and show accelerated growth, causing pain, paresthesia, trismus, and dysphonia. In pediatric patients it is extremely rare, with only a few case reports to date. Overall survival rates are twice as bad for maxillary tumors compared to mandible tumors (OSAMA *et al.*, 2022). Survival rates vary according to the progression of the disease, at

what stage it was found, and type of treatment, varying according to the malignant pathology (LOPEZ; TUFARO, 2019).

Predisposing factors

In a period of 5 years, 51 cases of ameloblastoma were recorded, representing an average of about 10 cases per year. The patient was aged between 21 and 56 years, and most patients were between 21 and 30 years old. Regarding the duration of the tumor, a period of approximately 33.4 to 46.2 months was observed. The male-to-female ratio was 1.4 to 1, with a higher incidence in the jaw (NWOGA, 2022).

PRECOCCE DIAGNOSIS

The diagnosis of these tumors is based on the manifestations presented by the patients. As many tumors have an asymptomatic characteristic when in the early stages, the results of these analyses may vary depending on the period chosen for their construction. In this sense, it is necessary to combine the patient's clinical history with clinical examinations of the oral cavity, since they may present pain, swelling and suppuration. These with the possibility of being evidenced by radiographs, biopsies and histopathological surveys for the construction of an effective diagnosis (ACUNÃ *et al.*, 2019; KATO *et al.*, 2020).

This investigation can be complex for several reasons, such as: inadequate sample collection, coexistence of inflammation and ulceration, preventing the differentiation of normal tissues. Thus, the way to obtain a specific diagnosis of these lesions is not a consensus in the scientific community, varying among different authors. Moubayed *et al.* (2016), for example, recommends as a strategy the performance of biopsies - incisional or excisional - depending on the size of the lesion and its origin. Carreon-Burciaga, in turn, believes that immunohistochemistry is a fundamental tool to decide the appropriate treatment of various neoplasms, as cell proliferation can be evaluated (KATO *et al.*, 2020; VALLE *et al.*, 2018).

SURGICAL TREATMENT

There are several treatment modalities for these tumors, and this will depend on the histopathology, location, size, age of the patient and the type of lesion. These can be classified as aggressive or conservative treatments, and the use of Carnoy's solution is very frequent in the conservative route, as it reduces the frequency and mitigates the severity of complications (MARTORELLI *et al.*, 2021; VALLE *et al.*, 2018).

In addition, numerous authors agree that surgery is one of the most effective ways to control these neoplasms, but that a greater number of controlled clinical trials are still needed. Therefore,

studies with larger sample spaces and monitoring periods should be carried out in order to obtain homogeneous results that allow the establishment of a treatment called the "gold standard" (ACUNÃ *et al.*, 2019; FORTEZA-LÓPEZ *et al.*, 2018).

OBJECTIVES

GENERAL OBJECTIVES

To identify the prevalence of tumors that cause the loss of facial bone structures.

SPECIFIC OBJECTIVES

- Identify predisposing factors for the development of bone tumors in the facial region;
- To evaluate the results of surgical treatments such as treatment of tumors that cause facial bone loss.
- Observe early diagnosis strategies.

METHODOLOGY

STUDY DESIGN

This is an integrative review of the literature.

DATA COLLECTION

The selection of articles for the construction of this review took place through the VHL (Virtual Health Library) database and PubMed, in the period from October 2023 to July 2024. Articles were selected using the following descriptors indexed in DeCS/MeSH: Odontogenic Tumors, Mandible, Maxilla, Ameloblastoma, Incidence, Prevalence, Maxillomandibular Neoplasms, Oral Diagnosis, Oral Surgery, Predisposing Factors, Mortality, Osteosarcoma, Bone Neoplasms.

INCLUSION CRITERIA

1. Articles in English, Spanish and Portuguese;
2. Articles published in the last 5 years;
3. Articles that had full text in databases;
4. Articles with titles related to the prevalence and incidence of tumors that cause the loss of bone structures of the face.

EXCLUSION CRITERIA

1. Articles not available in full and duplicates;
2. Narrative literature review articles;

3. Non-free items;
4. Articles that did not present content consistent with the objective;
5. Articles not related to the topic of interest of the work;

SEARCH STRATEGY

To select the articles used in this literature review, the Boolean operators AND and OR were used, with the following search expressions: "Tumors" AND "mandible"; "Tumors" AND "mandible" OR "maxilla" AND "bone lesions"; "Ameloblastoma" AND "Incidence" OR "prevalence"; "Benign tumors" AND "bones"; "Bone neoplasms" AND "case report" AND "bone injury"; "Early Diagnosis" AND "Oral Diagnosis" OR "Oral Diagnosis" AND "Maxillomandibular Neoplasms"; "Diagnosis" AND "Maxillomandibular Neoplasms"; "General Surgery" AND "Maxillomandibular Neoplasms"; "Oral Surgery" AND "Maxillomandibular Neoplasms"; "Therapeutics" AND "Maxillomandibular Neoplasms"; "Prevalence" AND "Bone Tumors"; "Mortality" AND "Bone Tumor" AND "Factors"; "Mortality" OR "Epidemiological Data" AND "Osteosarcoma"; "Bone Neoplasms" OR "Osteosarcoma" AND "Ewing's Sarcoma" OR "Prevalence"; "Odontogenic Tumors" OR "Bone Tumors AND Prevalence", "Prevalence" AND "Odontogenic Tumors", "Incidence" AND "Odontogenic Tumors", "Causality" AND "Odontogenic Tumors" and "Maxillomandibular Neoplasms" AND "Prevalence" AND "Incidence". The number of articles found from these search expressions in the VHL database generated table 1. Subsequently, the articles of interest were selected for the construction of the integrative literature review, generating table 2.

Table 1 - Number of articles identified by database.

Database	Results
VHL	2853
PubMed	687
Total	3540

Table 2 - Number of articles selected by database.

Database	Results
VHL	8
PubMed	5
Total	13

Source: Prepared by the authors.

Among the 3,540 articles found in the Virtual Health Library (VHL) and PubMed, 51 were pre-selected for the construction of this literature review according to the inclusion and exclusion criteria. Of these 30 pre-selected articles, 13 articles that presented the best adequacy to the objectives of the study were chosen for the construction of this integrative review.

After the selection, a detailed reading of the chosen articles was carried out and their highlights were compiled in Table 3.

RESULTS

For the elaboration of this literature review, a total of 8 articles were found. In the following flowchart it is possible to check the selection steps that generated the choice of articles:

FLOW CHART

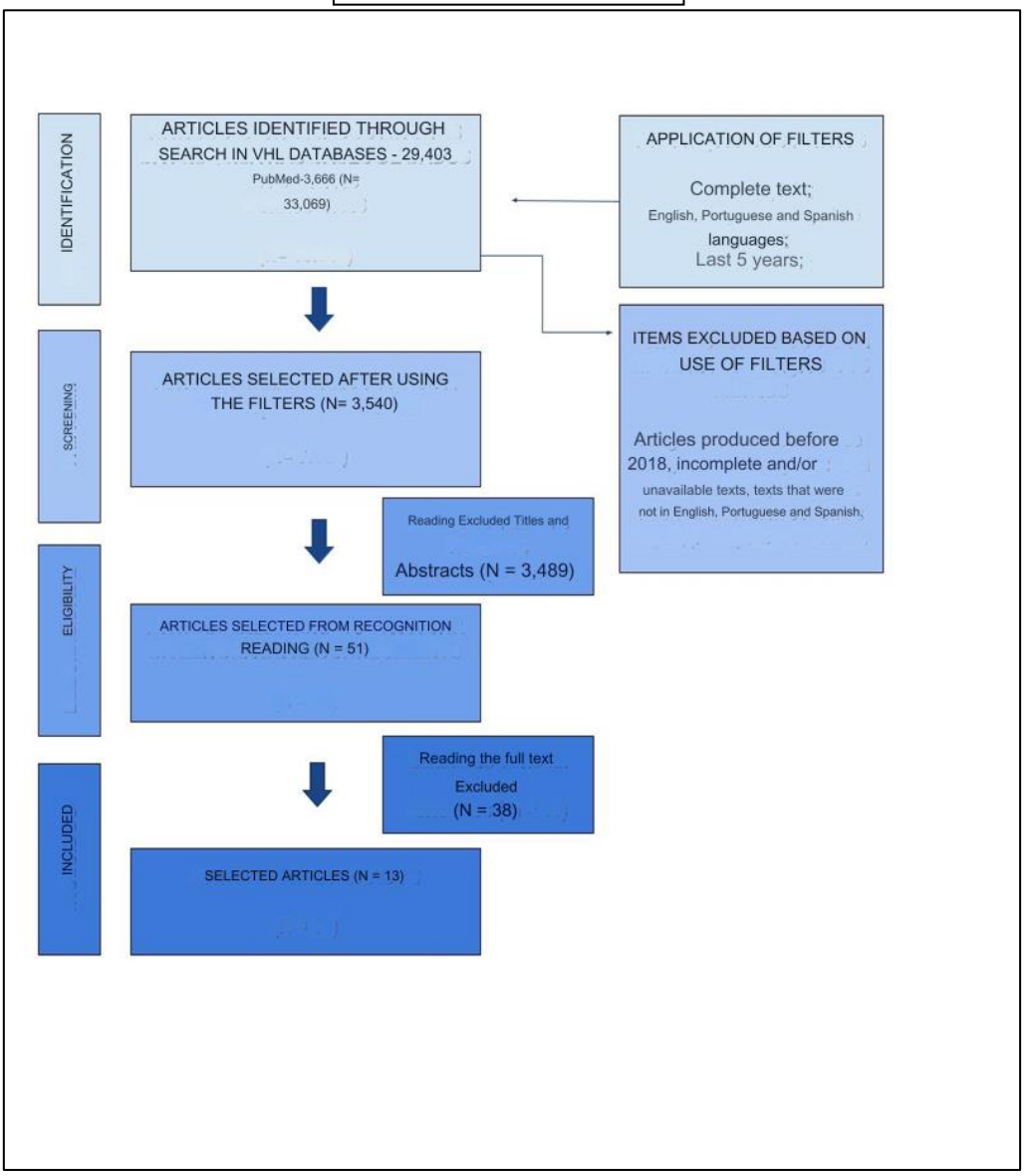

Source: Prepared by the authors.

Using the criteria exposed and the proposed methodology, it was possible to observe the selected articles in table 3.

Table 3 - List of selected articles:

AUTHOR	OBJECTIVES	METHODOLOGY	RESULTS	CONCLUSIONS
BARROS *et al*., 2019	To establish the frequency of odontogenic lesions over 12 years in a reference service in Oral Pathology in the Brazilian Northeast.	All medical records with biopsy reports of the maxillofacial region issued from January 1999 to December 2010 were analyzed. In addition to the histopathological diagnosis, data on the location of the lesion, age, sex, and skin color were recorded	Among 3,034 samples, 409 were odontogenic cysts and 199 were odontogenic tumors (OT). The most frequent Odontogenic Cysts (OC) were the root cyst with 129 and odontogenic keratocyst with 99. Among the OTs, the most frequent were ameloblastoma with 80 and odontoma with 47.	There was a considerable reduction in the relative frequency of odontogenic tumors after reclassification in the 4th Edition of the WHO Classification of Head and Neck Tumors. Despite similarities in the epidemiological profile, the importance of standardizing classification methods according to the most recent WHO guidelines is highlighted.
GHAZI *et al.*, 2023	To determine the relative frequency of central odontogenic tumors in an Iraqi population, utilizing the 2022 WHO tumor classification.	60 cases of central odontogenic tumors were recovered from a total of 1869 case records in the archives of the histopathology laboratory in Baghdad Medical City, in the period 2016 to 2021.	Odontogenic tumors accounted for 3.2% of the total cases analyzed, most of which were benign. Ages ranged from 11 to 75 years, with the majority in the third and fourth decades of life. Most of these tumors were located in the jaw.	Odontogenic tumors occurred more frequently in the mandible and did not show a predilection for sex. Most cases were diagnosed in the third and fourth decades of life, with ameloblastoma being the most frequent odontogenic tumor.
MACDONALD, D. (2020)	Review the radiological presentation that identifies the most frequent and/or important lesions affecting the facial bones and jaws.	18 radiological images derived from lesions affecting the face and jaws were analyzed. Information about the lesions was outlined in a flowchart.	Important diagnostic features are presented on radiographic images of lesions affecting the bones of the face and jaws. It is stated that the most frequent lesion found in the practice of dentistry is the PRIO.	The most important and/or frequent lesions can be diagnosed through the use of radiographs. Being the inflammatory periapical lesion, one of the most common lesions found in the dental clinic.

MCLEAN, A. (2023)	To evaluate the histopathological differences of two clinical cases with cystic lesions in the mandible.	Two clinical cases were presented in parallel, followed by an illustrated discussion of the most likely diagnostic differences.	It was an Odontogenic keratocyst and the other an Adenomatoid Odontogenic Tumor. Endodontic treatments were performed in both cases, which did not resolve the patients' lesions. Highlighting the importance of a diagnosis before procedures	The maxillomandibular region can have a wide variety of cystic, odontogenic and non-odontogenic lesions. Therefore, clinical and radiographic information are very important for diagnostic evaluations.
MEDEIROS *et al.*, 2018	OBJECTIVE: To determine the frequency and distribution of odontogenic tumors (OT) over a 22-year period at a public university in northeastern Brazil.	All OT cases from the oral pathology laboratory of the Federal University of Rio Grande do Norte (UFRN) from 1996 to 2017 were reviewed. The 247 cases of OT diagnosed in the analyzed period are taken into account.	Epithelial tumors were more common. The most common tumors were ameloblastoma, odontoma, and odontogenic myxoma. Malignant odontogenic tumors accounted for 0.8% of the total. In general, the mandible was the most affected anatomical site.	Odontogenic tumors were rare in the sample studied (2.2%), being ameloblastoma and odontoma the most common tumors.
PIRES *et al.*, 2020	To evaluate the prevalence of odontogenic and non-odontogenic tumors related to the maxillomandibular complex in a Reference Center for Oral Lesions.	This was a cross-sectional study based on the medical records of a Reference Center for Oral Lesions at the State University of Feira de Santana, from 2006 to 2018.	The prevalence of tumors was 2.27%. Of the benign odontogenic tumors, odontoma was the most frequent, followed by ameloblastoma. As for non-odontogenic patients, neurofibroma and osteoma were the most common among benign cases, while osteosarcoma accounted for 6.10% of cases.	OTs were more frequent in women, aged up to 39 years, and the odontoma was more common in the posterior region of the mandible. Among non-odontogenic tumors, central neurofibroma and osteoma were the most common.

RAGUNATHAN *et al.*, 2022	To establish the prevalence of ameloblastoma in India and to establish a national epidemiological profile for these lesions.	A systematic review was conducted in search of epidemiological studies on odontogenic tumors and ameloblastoma.	The patients were on average in the third decade of life, predominantly male, with lesions in the posterior region of the mandible. The most common type of malignant lesion is ameloblastic carcinoma.	There was a slight male predisposition to ameloblastoma, with a peak incidence in the third decade of life and the mandible as the preferred anatomical site. Solid/multicystic ameloblastoma is the most prevalent histopathological pattern.
PALE-TEKKESIN, M; WRIGHT, J. M. (2022)	To analyze odontogenic tumors and cysts of the mandible, according to the 5th edition of the WHO Classification of Head and Neck Tumors,	It consists of the analysis of odontogenic tumors and mandible cysts, some changes were identified in relation to the 2017 classification.	The 2022 edition presents few conceptual changes in relation to the previous classification of odontogenic lesions.	It provides an analysis of changes in the classification of OTs and cysts of the mandible by the WHO, highlighting the importance of the new diagnostic criteria.
ALY *et al.* (2022)	To evaluate the frequency of oral and maxillofacial pathologies in Egyptian children.	An observational study of the research conducted at Cairo University was done. Evaluating the frequency of pathologies, age and sexual predilection.	Analysis of 1,108 samples showed that reactive soft tissue lesions were most prevalent, followed by odontogenic cysts. Malignancy was found in 19 of these cases.	The prevalence of pathologies increased over time, in addition to the majority of lesions being benign, reactive and inflammatory, appearing between 11 and 15 years of age.
LOPEZ *et al.* (2019)	Discuss the most common malignant maxillofacial bone tumors.	A literature review was conducted analyzing the epidemiology, pathogenesis, prognosis, and management of the most common bone malignancies of the maxillofacial skeleton.	The management for malignant tumors is controversial, but surgical excision with margins followed by chemotherapy or radiotherapy depending on the tumor is the most recommended.	Due to their rarity, the appropriate treatment for these lesions is still unclear. Therefore, larger studies are needed to determine the appropriate strategies to reduce morbidity.

ROONEY et al. (2021)	To report on treatment patterns and survival outcomes for one of the largest cohorts of patients with odontogenic cancers.	Patients with odontogenic tumors that did not have metastatic disease from 2004 to 2016 were included. Patient and treatment were evaluated using logistic regression.	A total of 437 patients with odontogenic cancer were identified. In the analysis, survival was associated with age (<57), lower comorbidity scores, surgical resection, and absence of lymph node metastases.	In this series of odontogenic cancers, any type of surgical resection was associated with greater survival. Lymph node metastases were associated with lower survival.
VILLEGAS, K. M; PAPARELLA, M. L. (2022)	To report in a single diagnostic center over a period of 38 years, 30 cases of malignant odontogenic tumors.	All cases of malignant odontogenic tumors diagnosed between 1980 and 2018 were retrieved from the archives of the Faculty of Dentistry of the University of Buenos Aires, comparing the data obtained with those in the literature.	Malignant odontogenic tumors accounted for 2% of odontogenic tumors and 0.05% of all oral-maxillofacial diseases. The mean age was 43 years, with the most frequent location in the mandible, with odontogenic carcinoma being the most frequent, and primary intraosseous carcinomas were the most common in this group.	The diagnosis of these tumors is challenging due to their rarity and complexity, depending on a thorough analysis of their clinical, radiographic, and histopathological characteristics.
AL-AROOMY *et al. (2022)*	To evaluate the frequency and distribution of odontogenic tumors based on the current 2017 WHO Classification of Head and Neck Tumors over a 5-year period.	Records of patients diagnosed with odontogenic tumors were obtained from six educational hospitals and one institute in Cairo. These registries were reviewed over a 5-year period (2014-2018) and investigated for frequency, age, gender, and location.	A total of 230 cases of odontogenic tumors were collected and reviewed, 2.17% of which were malignant. Ameloblastoma was the most frequent odontogenic tumor (55.65%), followed by cemento-ossifying fibroma (14.78%) and odontoma (9.13%). In the third and fourth decades of life with a predilection for the female sex and the mandible.	Knowledge of the relative incidence of odontogenic tumors in different parts of the world improves the understanding of lesions, which contributes significantly to improving the concepts of treatment and prognosis.

Source: Prepared by the authors.

DISCUSSION

With complete odontogenesis, epithelial remains remain in the gums and gnathic bones, which can promote odontogenic cysts and tumors when stimulated by inflammatory or genetic impulses (MCLEAN; VARGAS, 2023). Thus, odontogenic tumors (OTs) are neoplastic lesions originating from remnants of the formation of dental tissues, usually surrounded by complex treatments and diagnoses (BARROS *et al*, 2019; PIRES *et al*, 2020).

Some factors can alter the incidence and prevalence of odontogenic tumors, such as radiation exposure, age, and gender. Research carried out in Asia and Africa pointed to a higher prevalence when compared to studies involving America and Europe - with a statistical inequality of about 3 percentage points (MEDEIROS *et al*, 2018).

OTs are rare regardless of whether they have malignancy or not - although malignant ones are statistically less frequent than benign ones. Ameloblastoma is one of the most common benign tumors in Africa and Asia, belonging to an aggressive clinical behavior (BARROS *et al*, 2019; GHAZI, 2023; MEDEIROS *et al*, 2018; PIRES *et al*, 2020). The WHO classifies ameloblastoma as conventional, solid/multicystic, unicystic and peripheral - with solid/multicystic being the most incident and extraosseous being the rarest (MEDEIROS *et al*, 2018; SOLUK-TEKKESIN; WRIGHT, 2022). The WHO also indicates that the male sex is the main victim of ameloblastoma during the second decade of life, affecting mainly the mandible (SOLUK-TEKKESIN; WRIGHT, 2022). Intraosseous ameloblastoma and conventional ameloblastoma also have their specificities: intraosseous ameloblastoma, acting during the fifth and seventh decades, presents a risk to both the mandible and maxilla, while conventional ameloblastoma does not require any predilection between the sexes (SOLUK-TEKKESIN; WRIGHT, 2022).

In relation to affected individuals, in most studies, a greater predisposition is observed in men than in women, especially around the second and third decades of life. In malignant tumors, this predisposition is noticed around the fourth decade (RAGUNATHAN *et al*, 2022). Most of these lesions have a preference for the mandible, especially the posterior region, when compared to the maxilla (BARROS *et al*, 2019; MEDEIROS *et al*, 2018; PIRES *et al*, 2020). Other places, such as the gingiva, the alveolar process, the lingual vestibule, and the mandibular vestibule, were also the most reported sites (RAGUNATHAN *et al*, 2022). Radiography plays a crucial role in the early identification and effective treatment of odontogenic tumors (MACDONALD, 2020), such as adenomatoid, a benign tumor, which usually presents with unilocular radiolucent lesions (MACLEAN; VARGAS, 2023).

Computed tomography, magnetic resonance imaging, and cone beam tomography are considered routine diagnostic tools for odontogenic tumors. Before considering surgical intervention, it is necessary to consider some factors, such as age, size, location, persistence of the lesion, the

occurrence of cortical bone damage, soft tissue infiltration, and whether the tumor is primary or recurrent (RAGUNATHAN *et al*, 2022).

According to Aly, Abdul-aziz and Elchaghaby (2022), in a sample made with biopsies from patients under 18 years of age, benign maxillofacial bone pathologies reached only 0.9%, while those with a malignant course represented 21%, although giant cell lesions and fibrobone lesions were the most frequent pathologies that cause bone lesions among the samples. According to Al-aroomy *et al* (2022), intraosseous odontogenic tumors represent 2.56% of all biopsies analyzed, in which 97.8% were benign and 2.17% were malignant, showing that in both studies benign lesions stand out, however, visualizing a difference between their prevalence.

Regarding treatment, most malignant tumors are initially treated with surgical excision with a safety margin, followed by chemotherapy or radiotherapy, depending on each pathology. Their prognoses vary, with survival rates ranging from 30% to 81%, depending on the pathology and its stage of advancement (LOPEZ; TUFARO, 2019). Surgery has been shown to be beneficial in most cases in relation to malignant tumors, patients who were treated surgically had 87.5% survival and 26.6% for those who did not receive surgical treatment (ROONEY *et al*, 2021). For diagnostic purposes, a careful clinical, radiographic and histopathological analysis is necessary in order to diagnose as efficiently as possible (VILLEGAS; PAPARELLA, 2022).

CONCLUSION

Therefore, the most common tumors that cause facial bone lesions are those related to odontogenesis - mostly benign, such as ameloblastomas, seen as the most frequent tumor of odontogenic tumors, with prevalence rates ranging from (0.9% to 2.56%) in some studies, but always with benignity rates higher than malignancy.

Computed tomography, magnetic resonance imaging, and cone-beam tomography, when combined with clinical examinations, were considered acceptable tools for the diagnosis of these tumors, and are therefore of great importance for the assertiveness of the proposed prognosis

Regarding the predisposing factors, according to the literature, the most affected age group was 22 to 56 years, more men than women.

Regarding surgery, it is the best option for most tumors with bone involvement, due to the longer survival for the patient.

REFERENCES

Acuña, J. G. S., Morales, D. N., & Féiria, O. H. (2019). Colgajo temporal en la reconstrucción de un defecto maxilar por exéresis de carcinoma ameloblástico. Revista Cubana de Estomatología, 56(4), e2108. Available at: https://pesquisa.bvsalud.org/portal/resource/pt/biblio-1093256. Accessed on: December 20, 2023.

Al-Aroomy, L., et al. (2022). Odontogenic tumors: A retrospective study in Egyptian population using WHO 2017 classification. Medicina Oral, Patología Oral y Cirugía Bucal, 27(3), e198. https://doi.org/10.4317/medoral.24661. Available at: https://www.ncbi.nlm.nih.gov/pmc/articles/PMC9054167/pdf/medoral-27-e198.pdf. Accessed on: July 11, 2024.

Aly, M. M., Abdul-Aziz, M. A. M., & Elchaghaby, M. A. (2022). A retrospective analysis of oral and maxillofacial pathological lesions in a group of Egyptian children over 21 years. BMC Oral Health, 22(1), 2. https://doi.org/10.1186/s12903-021-02037-6. Available at: https://link.springer.com/article/10.1186/s12903-021-02037-6. Accessed on: July 10, 2024.

Barros, A. V. M., et al. (2019). Cistos e Tumores Odontogênicos em uma população brasileira: Análise retrospectiva de 12 anos à luz da 4ª Edição da Classificação dos Tumores de Cabeça e Pescoço da OMS. Revista de Cirurgia e Traumatologia Buco-Maxilo-Facial, 19(4), 13–19. Available at: https://www.revistacirurgiabmf.com/2019/04/Artigos/03ArtOriginalCistoseTumoresOdontogenicos.pdf. Accessed on: January 5, 2024.

Del Valle, S. U., Martinez, E. T., & Aparício, E. L. (2018). Ameloblastoma multicístico de rápido crescimento com reconstrução parcial. Revista Cubana de Estomatología, 55(4), 1–8. Available at: https://www.medigraphic.com/cgi-bin/new/resumen.cgi?IDARTICULO=86903. Accessed on: January 5, 2024.

Forteza-López, A., et al. (2019). Tratamento do tumor odontogênico ceratocístico: Revisão sistemática. Revista Espanhola de Cirurgia Oral e Maxilofacial, 41(1), 26–32. https://doi.org/10.20986/recom.2019.1026/2019. Available at: https://scielo.isciii.es/scielo.php?pid=S1130-05582019000100026&script=sci_arttext&tlng=en. Accessed on: January 5, 2024.

Ghazi, O. M. (2023). Frequency of central odontogenic tumors: A retrospective study in an Iraqi population utilizing 2022 WHO head and neck tumors classification. Brazilian Dental Science, 26(2). https://doi.org/10.4322/bds.2023.e3645. Available at: https://bds.ict.unesp.br/index.php/cob/article/view/3645. Accessed on: July 12, 2024.

Hasyim, N. A., et al. (2023). Odontogenic carcinosarcoma: An updated literature review and report of a case. Head and Neck Pathology, 17(3), 731–738. https://doi.org/10.1007/s12105-023-01545-x. Available at: https://pubmed.ncbi.nlm.nih.gov/36997684/. Accessed on: December 20, 2023.

Kato, C. N. A. O., et al. (2020). Infected cemento-osseous dysplasia: Analysis of 66 cases and literature review. Head and Neck Pathology, 14(1), 173–182. https://doi.org/10.1007/s12105-019-01037-x. Available at: https://www.ncbi.nlm.nih.gov/pmc/articles/PMC7021850/. Accessed on: January 5, 2024.

Kumar, V., Aster, J. C., & Abbas, A. K. (2021). Robbins & Cotran Patologia: Bases patológicas das doenças (9th ed.). Rio de Janeiro: Guanabara Koogan.

Lopez, J., & Tufaro, A. P. (2019). Malignant maxillofacial bone tumors. Current Opinion in Otolaryngology & Head and Neck Surgery, 27(4), 294–301. https://doi.org/10.1097/MOO.0000000000000555. Available at: https://journals.lww.com/co-otolaryngology/abstract/2019/08000/malignant_maxillofacial_bone_tumors.12.aspx. Accessed on: July 11, 2024.

MacDonald, D. (2020). The most frequent and/or important lesions that affect the face and the jaws. Oral Radiology, 36, 1–17. https://doi.org/10.1007/s11282-019-00367-4. Available at: https://link.springer.com/article/10.1007/s11282-019-00367-4. Accessed on: July 12, 2024.

Martorelli, S. B. F., et al. (2021). Mixoma odontogênico de mandíbula tratado por curetagem, osteotomia periférica e uso de solução de Carnoy: Relato de caso mandibular. Odontologia Clínica-Científica, 20(2), 79–84. https://doi.org/10.25243/issn.1677-3888.v20i2p79-84. Available at: https://pesquisa.bvsalud.org/portal/resource/pt/biblio-1369198. Accessed on: January 5, 2024.

McLean, A. C., & Vargas, P. A. (2023). Cystic lesions of the jaws: The top 10 differential diagnoses to ponder. Head and Neck Pathology, 17(1), 85–98. https://doi.org/10.1007/s12105-023-01525-1. Available at: https://link.springer.com/article/10.1007/s12105-023-01525-1. Accessed on: January 18, 2024.

Medeiros, W. K. D., et al. (2018). Clinicopathological analysis of odontogenic tumors over 22 years period: Experience of a single center in northeastern Brazil. Medicina Oral, Patologia Oral y Cirugía Bucal, 23(6), e664. https://doi.org/10.4317/medoral.22618. Available at: https://www.ncbi.nlm.nih.gov/pmc/articles/PMC6261000/pdf/medoral-23-e664.pdf. Accessed on: July 12, 2023.

Nwoga, M. C. (2022). Recurrent tumours of ameloblastoma: Clinicopathologic features and diagnostic outcome. Nigerian Journal of Clinical Practice, 25(9), 1771–1777. https://doi.org/10.4103/njcp.njcp_82_22. Available at: https://pubmed.ncbi.nlm.nih.gov/36149215/. Accessed on: December 20, 2023.

Osama, M. A., et al. (2023). Transformation of ameloblastoma to ameloblastic carcinoma in a 10-year-old child. Journal of Cancer Research and Therapeutics, 19(8), 426–429. https://doi.org/10.4103/jcrt.jcrt_282_22. Available at: https://pubmed.ncbi.nlm.nih.gov/37147971/. Accessed on: December 20, 2023.

Pires, A. L. P. V., et al. (2021). Prevalence of tumours of the maxillomandibular complex diagnosed in a reference center in Brazil. Brazilian Journal of Oral Sciences, 20, e211817. http://dx.doi.org/10.20396/bjos.v20i00.8661817. Available at: https://periodicos.sbu.unicamp.br/ojs/index.php/bjos/article/view/8661817. Accessed on: January 18, 2024.

Ragunathan, Y. T., et al. (2022). Prevalence and epidemiological profile of ameloblastoma in India: A systematic review and meta-analyses. Asian Pacific Journal of Cancer Prevention, 23(11), 3601–3610. https://doi.org/10.31557/APJCP.2022.23.11.3601. Available at: https://www.ncbi.nlm.nih.gov/pmc/articles/PMC9930951/. Accessed on: July 12, 2024.

Rooney, M. L. K., et al. (2021). Patterns of care and survival outcomes for odontogenic cancers. The Laryngoscope, 131(5), E1496–E1502. https://doi.org/10.1002/lary.29173. Available at: https://onlinelibrary.wiley.com/doi/abs/10.1002/lary.29173. Accessed on: July 11, 2024.

Soluk-Tekkesin, M., & Wright, J. M. (2022). The World Health Organization classification of odontogenic lesions: A summary of the changes of the 2022 (5th) edition. Turkish Journal of Pathology, 38(2), 168–184. https://doi.org/10.5146/tjpath.2022.01573. Available at: https://www.turkjpath.org/pdf/pdf_TPD_2008.pdf. Accessed on: December 20, 2023.

Tabakovic, S. Z., et al. (2018). Intraosseous lipoma of the maxillary tuberosity: A case report. Journal of Stomatology, Oral and Maxillofacial Surgery, 119(2), 151–153. https://doi.org/10.1016/j.jormas.2017.11.010. Available at: https://pubmed.ncbi.nlm.nih.gov/29158069/. Accessed on: December 20, 2023.

Villegas, K. M., & Paparella, M. L. (2022). Malignant odontogenic tumors. A report of a series of 30 cases and review of the literature. Oral Oncology, 134, 106068. https://doi.org/10.1016/j.oraloncology.2022.106068. Available at: https://www.sciencedirect.com/science/article/abs/pii/S1368837522003578. Accessed on: July 10, 2024.

Xia, M. M. Y., et al. (2023). Ghost cell odontogenic carcinoma: A rare case report and review of literature. Medicine, 102(38), e35225. https://doi.org/10.1097/MD.0000000000035225. Available at: https://www.ncbi.nlm.nih.gov/pmc/articles/PMC4312695/. Accessed on: December 20, 2023.