




## ENDODONTIC TREATMENT OF UPPER FIRST PREMOLAR WITH 3 ROOT CANALS

## TRATAMENTO ENDODÔNTICO DE PRIMEIRO PRÉ-MOLAR SUPERIOR COM 3 CANAIS RADICULARES

## TRATAMIENTO ENDODÓNTICO DEL PRIMER PREMOLAR SUPERIOR CON 3 CONDUCTOS

 <https://doi.org/10.56238/levv16n50-029>

Submitted on: 06/07/2025

Publication date: 07/07/2025

**Rosana Maria Coelho Travassos<sup>1</sup>, Pedro Henrique Pereira de Souza<sup>2</sup>, Samuel Nogueira Lima<sup>3</sup>, Victoria Caroline da Silva<sup>4</sup>, Luciane Farias de Araújo<sup>5</sup>, Josué Alves<sup>6</sup>, Priscila Prosini<sup>7</sup>, William José Lopes de Freitas<sup>8</sup>, Alexandre Batista Lopes do Nascimento<sup>9</sup>, Eliana Santos Lyra da Paz<sup>10</sup> and Verônica Maria de Sá Rodrigues<sup>11</sup>**

---

<sup>1</sup>Dr. in Dentistry and Endodontics Faculty of Dentistry of Pernambuco - FOP University of Pernambuco - UPE - Brazil

rosana.travassos@upe.br

<sup>2</sup>University of Nova Iguaçu - Campus V - Itaperuna RJ

E-mail -dr.pedrosouzaa@gmail.com

<sup>3</sup>Doctor in dental clinics.

Mário Jucá University Center- UMJ Wiliam Wale Rodrigues Martins

Specialist in Endodontics UNIC University of Cuiabá MT -CACOAL RO

drwilliammartins@hotmail.com

<sup>4</sup>Specialist in endodontics

Catholic University Center of Quixadá-CE

victoriacsilva@outlook.com

<sup>5</sup><https://orcid.org/0000-0002-8563-8999> Dr. in Dental Radiology from Unicamp Professor at the University of Pernambuco

Email: luciane.araujo@upe.br

<sup>6</sup>Associate Professor FOP-UPE

Dr. in Oral Rehabilitation from FOB-USP

Professor at the University of Pernambuco

Email: josue.alves@upe.br

<sup>7</sup>Dr. in Dentistry, University of Pernambuco, Brazil

E-mail: priscila.prosini@upe.br

<sup>8</sup>Doctor of Dentistry

Prof FOP/UPE

Pedro Guimarães Sampaio Trajano dos Santos

Undergraduate in Dentistry, Faculty of Dentistry of Recife

pedroguimaraessampaio@gmail.com

<sup>9</sup>Doctor of Dentistry, Associate Professor at FOP/UFPE

alexandre.nascimento1@upe.br

<sup>10</sup>Prof Adjunto -UPE/ FOP

E-mail eliana.lyra@upe.br

University of Pernambuco-Brazil

monica.pontes@upe.br

<sup>11</sup>Dr. in Dentistry Assistant Professor at FOP /UPE

veronica.rodrigues@upe.br

## ABSTRACT

This case report highlights the successful non-surgical endodontic treatment of a maxillary first molar with unusual morphology. The treatment was performed with special C-Pilot and Glide Path files to obtain patency, and a rotary mechanized system, Sequence Rotary File from MK Life, with 2.5% Sodium Hypochlorite as an irrigating solution. The obturation was performed using the single cone technique associated with Sealer Plus sealer. It is concluded that a thorough knowledge of the variations in root canal anatomy is necessary for the success of the endodontic procedure.

**Keywords:** Endodontic. Premolar. Root canal. Anatomical variation.

## RESUMO

Este relato de caso destaca o tratamento endodôntico não cirúrgico bem-sucedido de um primeiro molar superior com morfologia incomum. O tratamento foi realizado com limas especiais da C-Pilot e Glide Path para se obter a patência, e sistema mecanizado rotatório, Sequence Rotary File da MK Life, Hipoclorito de Sódio 2,5% como solução irrigadora. A obturação foi realizada pela técnica do cone único associado ao cimento Sealer Plus. Conclui-se que o conhecimento profundo das variações na anatomia do canal radicular é necessário para o sucesso do procedimento endodôntico.

**Palavras-chave:** Endodontia. Pré-molar. Tratamento de canal. Variação anatômica.

## RESUMEN

Este informe de caso destaca el exitoso tratamiento endodóntico no quirúrgico de un primer molar maxilar con morfología inusual. El tratamiento se realizó con limas especiales C-Pilot y Glide Path para obtener la permeabilidad, y un sistema mecanizado rotatorio, Lima Rotatoria Sequence de MK Life, Hipoclorito de Sodio al 2.5% como solución irrigante. El relleno se realizó mediante la técnica de cono único asociado al cemento Sealer Plus. Se concluye que un conocimiento profundo de las variaciones en la anatomía del conducto radicular es necesario para el éxito del procedimiento endodóntico.

**Palabras clave:** Endodoncia. Premolar. Conducto radicular. Variación anatómica.

## INTRODUCTION

The variation in the number of roots, canals, root direction, longitudinal depressions of the roots, the various shapes of the pulp cavity and the problems in visualizing the apical limit by radiographs make the endodontic procedure of these teeth quite challenging. (Khan et al. 2024).

Numerous factors influence the variations found in the root canal morphology including ethnic background, gender, method of data collection, sample size and the mode of studying the root canal space [9]. Three-rooted premolars are more frequent in Caucasian populations and practically non-existent in Asian populations. (Soares, Leonardo, 2003).

Visualization of three canals in a maxillary premolar on pre-operative radiographs can often be difficult. Although the pre-operative radiograph gives a two dimensional image of a three dimensional object, there are some guides that suggest the presence of a third canal/root. Whenever there is an abrupt straightening or loss of radiolucent canal in the pulp cavity, a third canal should be suspected, either in the same root or in the other independent root [12]. Also, whenever the mesio-distal width of the mid-root area is equal to or greater than the mesio-distal width of the crown, the tooth most likely has three roots and multiple canals are common when a radiograph shows an eccentrically placed instrument in roots. (Sieraski et al. 1985).

Maxillary first premolars present significant challenges in pulp treatment due to their variable root number, complex root canal structure, diverse root orientation and longitudinal depression, and varying pulp cavity configurations. The variation in maxillary first premolars is significant, with the majority exhibiting two root canals, while the incidence of three root canals ranges from 0.5% to 7.5% (Kong et al. 2020). Determining the number of root canals and the location of root canal orifices in the early stage of treatment is crucial for the success of root canal therapy

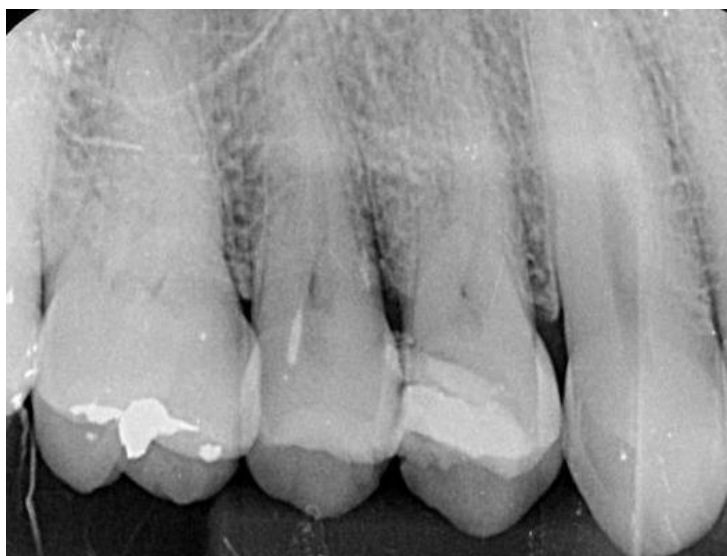## CASE REPORT

The aim of this case was to understand and treat the intricate root canal anatomy observed in complex maxillary first premolar, particularly those exhibiting three root canals, emphasizing the significance of understanding root canal morphological variations in their treatment.

The patient was a 23-year-old male. On November 23, 2022, he presented with occasional intermittent spontaneous pain due to caries in the left upper posterior tooth. Clinical Examination: The distal adjacent surface of the left maxillary first premolar exhibited

resin filling, with visible edges and loose filling material upon probing. Pain was elicited upon exploration, with slight percussion tenderness noted. No evidence of loosening or redness and swelling of the gingiva was observed. The temperature test was sensitive. The radiograph confirmed the presence of 3 root canals of the upper right first premolar as shown in Figure 1.

Figure 1 - Presence of 3 root canals of the upper right first premola



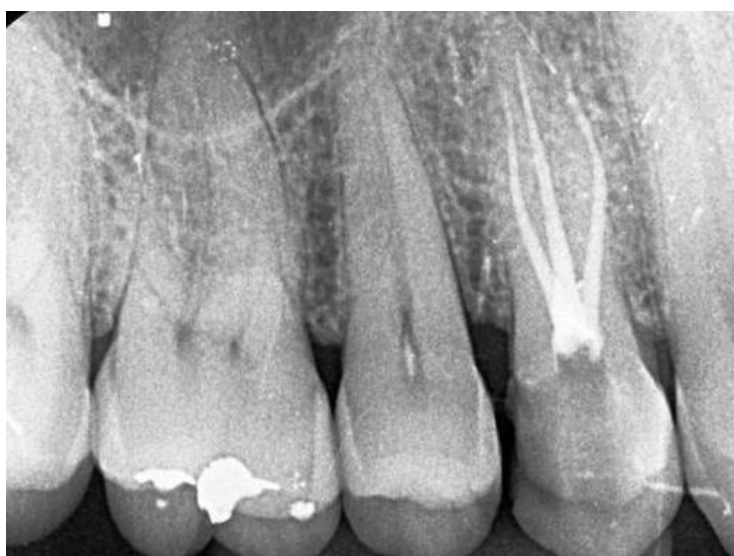Treatment, discovery, and confirmation of three root canals: Root canal therapy of left upper first premolar. Informed consent was obtained from the patient. Epinephrine-containing lidocaine local infiltration anesthesia for dental procedures, with the rubber septum. In the maxillary left first premolar, the pulp was accessed following pulp exposure, and the mesiobuccal root canal was detected using the DG-16 probe. The triangular access cavity of this premolar resembled that of a molar and three distinct orifices were located corresponding to three canals. Mesio-buccal (MB) and disto-buccal (DB) orifices were located in close proximity to each other and the palatal orifice was found to be located in line with the palatal cusp tip.

One root canal was identified on the palatal side. The root canals were unobstructed with 10 stainless steel K (MANI Company, Japan). Two root canals were found to be unobstructed and curved at an angle. Additionally, two pulp extraction needles were removed during the procedure. The length of the root canal was measured using the root canal length measuring instrument (Root ZX, Morita, Japan), with the palatal root canal measuring 21 mm and the buccal root canal also measuring 21 mm. images were observed in the distal buccal root canals, raising suspicion regarding the presence of additional distal buccal root canals. When the dentin canals of the

isthmus were repaired under the microscope, two root canals, namely, the proximal buccal and distal buccal root canals, were observed a few millimeters away from the original buccal root canal.

Three canals were prepared using ProTaper Niti rotary instruments (Den Berg, USA) to F2, and the root canals were irrigated with 5.25% sodium hypochlorite solution. Root canal filling was performed using the single cone technique associated with Bio-C Sealer cement. AH-plus Jet and F2 06 taper gutta-percha tip were used. The postoperative X-ray showed that all the 3 canals were filled (Figure 2).

Figure 2 - Root canal filling was performed using the single cone technique.



## DISCUSSION

Thorough knowledge of anatomic variations of the root canal system, careful interpretation of the angled radiographs and adequate access cavity preparation and exploration of the canals are required for successful endodontic therapy. The variation in the number of roots, canals, root direction, longitudinal depressions of the roots, the various shapes of the pulp cavity and the problems in visualizing the apical limit by radiographs make the endodontic procedure of maxillary first premolars quite challenging.. Khan et al. (2024). Additional radiographs with different angulations can be taken to confirm any uncommon anatomical features when a preoperative radiograph reveals an irregular contour and shape of the tooth.<sup>16</sup> An abrupt straightening or loss of a radiolucent channel in the pulp cavity might be suggestive of an additional canal in the same or a separate root.

In premolars, the existence of an eccentric orifice that is not in its normal place raises the possibility that there may be an additional canal. (Chaniotis , Ordinola-Zapata, 2002).

The maxillary first premolar is the most commonly bi- rooted tooth with occasional presentation of three roots system; it is a transitional tooth between incisors and molars. Although it usually has two canals, it may rarely have three and this third canal can easily be missed. Thus meticulous knowledge of tooth morphology, careful interpretation of angled radiographs, proper access cavity preparation and a detailed exploration of the interior of the tooth is needed to ensure a proper endodontic treatment. (Sulaiman, Dosumu, Amedari, 2013).

The x-ray examination is essential for a correct endodontic treatment, in both the diagnosis and treatment plan or to assess the outcome; however, it frequently fails in the detection of roots and auxiliary canals because the amount of data obtained by conventional film and periapical x-rays is limited by a series of events: (i) the 3D anatomy of the zone that has been x-rayed compresses into a 2D image, (ii) superposition of structures, (iii) geometric distortion of the anatomical structures. These issues can be overcome by the use of CBCT, which can produce 3D images of the individual teeth and surrounding tissues, allowing exploration on the sagittal and coronal planes, deprojecting the anatomical structures and providing accurate information about the number of roots and canals. (Patel et al. 2007).

This case was treated with a rubber stamp and a microscope. The rubber dam helped maintain a clear field of view during the treatment. In dental treatment, a clear field of view is crucial for clinicians, as it prevents saliva, blood, and medication from obstructing vision, thus improving the efficiency and accuracy of treatment.( Krasner, Rankow, 2004). The morphology of the pulp floor can be observed under the microscope, which helped reduce the likelihood of missing root canals (Lin, 2020).

The clinical management of premolars with three canals is complex due to their different anatomical variations. Nowadays, for root canal treatment, magnification (magnifying glasses, microscope), biomechanical preparations with mechanized instruments (rotary, reciprocating) and ultrasonic irrigation are used and are very helpful (Crozeta et al. 2020). In this case, the dentine shoulder collar of the distal buccal root canal orifice was accurately removed under the microscope, facilitating the establishment of a straight path for root canal clearance. Compared with traditional root canal therapy, the widely popularized microroot canal therapy is particularly significant in terms of both curative effect and root canal detection rate. In this case, the ProTaper Nickel titanium system was used to treat the root canal. the use of a nickel–titanium system can reduce the

operation time, preserve the original shape of the root canal, and reduce the complications after root canal treatment, and the success rate of root canal treatment over time is more than 96%. (Mengya et al. 2024).

Clinically, the access opening for the upper premolars is generally oval in the bucco-palatal direction. In cases of premolars with three roots, it is recommended that the access opening be modified, slightly expanding it in a more mesiodistal direction to discover the second buccal canal, completing the preparation of the cavity by giving it a triangular shape, similar to the access opening for an upper first molar, but smaller. (Velmurugan et al. 2005).

Failure in root canal treatment can be attributed to many factors such as lack of knowledge of canal anatomy, unfilled or incompletely debrided canals, persistence of bacteria, iatrogenic procedural errors, such as poor cavity conformation at the time of chamber opening, as well as complications at the time of biomechanical preparation. (Vera, 2020). New technological tools, such as dental study microscopy, greatly enhance the viewing area of root canal holes, allowing the work area to be enlarged and illuminated to a greater extent. Considering these advantages, de Carvalho, Zuolo, 2000, explained the importance of microscopes, which can significantly improve the prognosis of treatment.<sup>15</sup> In order for the root canal treatment to be successful, a dental microscope was used for the detection of extra canals and the appropriate chemomechanical preparation.

Knowledge of the relevant tooth's root canal anatomy and its variations from the normal is important for the success of root canal treatment. A detailed interpretation of radiographs coupled with accessibility and inspection of the pulpal floor under magnification can play an important role in the root canal treatment of complex root canal anatomy in endodontics. (Saklar et al. 2023).

The case report design, while valuable for highlighting unique clinical scenarios, has inherent limitations. Our study is limited by the small sample size, which restricts the generalizability of the findings. Additionally, the lack of a control group or comparative analysis with alternative treatment modalities may affect the interpretation of the results. Future research involving larger cohorts and controlled studies would provide a more comprehensive understanding of the treatment approaches for complex endodontic cases.

## CONCLUSION

It is concluded that thorough knowledge of the variations in root canal anatomy is necessary for the successful outcome of the endodontic procedure.



## REFERENCES

1. Carvalho, M. C., & Zuolo, M. L. (2000). Orifice locating with a microscope. *Journal of Endodontics*, 26(9), 532–534. <https://doi.org/10.1097/00004770-200009000-00012>
2. Chaniotis, A., & Ordinola-Zapata, R. (2022). Present status and future directions: Management of curved and calcified root canals. *International Endodontic Journal*, 55(S3), 656–684. <https://doi.org/10.1111/iej.13712>
3. Crozeta, B. M., Chaves de Souza, L., Correa Silva-Sousa, Y. T., Sousa-Neto, M. D., Jaramillo, D. E., & Silva, R. M. (2020). Evaluation of passive ultrasonic irrigation and GentleWave system as adjuvants in endodontic retreatment. *Journal of Endodontics*, 46(9), 1279–1285. <https://doi.org/10.1016/j.joen.2020.06.001>
4. Khan, D., Ahmed, A., Sabana Haq, S., & et al. (2024). Endodontic treatment of upper first premolar with 3 canals—Case report. *Journal of Rawalpindi Medical College*, 28(2), 352–355.
5. Kong, Q., Liang, L., Wang, G., & Shiqi, Q. (2020). Cone beam CT study of root and root canal morphology of maxillary premolars. *Prevention and Treatment of Oral Diseases*, 28(4), 246–251.
6. Krasner, P., & Rankow, H. J. (2004). Anatomy of the pulp-chamber floor. *Journal of Endodontics*, 30(1), 5–16. <https://doi.org/10.1097/00004770-200401000-00002>
7. Lin, T. (2020). Analysis of the curative effect of traditional root canal therapy and microscopic root canal therapy on difficult root canals. *Family Medicine Choice*, 5(5), 81–82.
8. Mengya, L., Lu, Y., & Xu, Q. (2024). Progress in root canal irrigation techniques and irrigation. *The Chinese Journal of Practical Stomatology*, 17(2), 247–252.
9. Patel, S., Dawood, A., Ford, T. P., & Whaites, E. (2007). The potential applications of cone beam computed tomography in the management of endodontic problems. *International Endodontic Journal*, 40(10), 818–830. <https://doi.org/10.1111/j.1365-2591.2007.01299.x>
10. Saklar, F., Öncü, A., Sevgi, S., & Çelikten, B. (2023). Endodontic treatment of premolar teeth with different root canal anatomy: Two case reports and literature review. *Cyprus Journal of Medical Sciences*, 8(6), 453–456. <https://doi.org/10.4274/cjms.2023.2022-42>
11. Sieraski, S. M., Taylor, G. T., & Kohn, R. A. (1989). Identification and endodontic management of three-canal maxillary premolars. *Journal of Endodontics*, 15(1), 29–32. [https://doi.org/10.1016/S0099-2399\(89\)80096-8](https://doi.org/10.1016/S0099-2399(89)80096-8)
12. Soares, J. A., & Leonardo, R. T. (2003). Root canal treatment of three-rooted maxillary first and second premolars—A case report. *International Endodontic Journal*, 36(10), 705–710. <https://doi.org/10.1046/j.1365-2591.2003.00713.x>
13. Sulaiman, A. O., Dosumu, O. O., & Amedari, M. (2013). Maxillary first premolar with three root canals: A case report. *Annals of Ibadan Postgraduate Medicine*, 11(2), 105–108.





14. Velmurugan, N., Parameswaran, A., Kandaswamy, D., Smitha, A., & Vijayalakshmi, D. (2005). Maxillary second premolar with three roots and three separate root canals—Case reports. *Australian Endodontic Journal*, 31(2), 73–75. <https://doi.org/10.1111/j.1747-4477.2005.tb00220.x>
15. Vera, M. M. (2020). Valoración de éxitos y fracasos en endodoncia [Unpublished bachelor's thesis]. Universidad de Guayaquil. <http://repositorio.ug.edu.ec/handle/redug/48351>